V.T.PALCHUN, N.L.VOZNESENSKY

DISEASES OF THE EAR, THROAT AND NOSE

MIR PUBLISHERS MOSCOW

DISEASES OF THE EAR, THROAT AND NOSE

В. Т. ПАЛЬЧУН, Н. Л. ВОЗНЕСЕНСКИЙ

БОЛЕЗНИ УХА, ГОРЛА И НОСА

ИЗДАТЕЛЬСТВО «МЕДИЦИНА»
МОСКВА

V.T.PALCHUN,
N.L.VOZNESENSKY

DISEASES OF THE EAR, THROAT AND NOSE

Translated from the Russian
by
Alexander Rosinkin

Mir Publishers
Moscow

First published 1988
Revised from the 1986 Russian edition

На английском языке

Printed in the Union of Soviet Socialist Republics

ISBN 5-03-000012-7
© Издательство «Медицина», 1986
© English translation, Mir Publishers, 1988

PREFACE

The study and treatment of disorders of the ear, nose, and throat (otorhinolaryngology) should be considered as an independent branch of the medical sciences with its own complex of nosological types of diseases that affect the vitally important functions of respiration, balance, hearing, speech and others–in short, affecting the overall condition of the organism.

Another important aspect of ear, nose and throat disorders is the high frequency of complications affecting other organs and organ systems. For example, pathologies of the ear and often of the nose and the paranasal sinuses can lead to otogenic and rhinogenic intracranial inflammatory (frequently purulent) processes and sepsis; affections of the throat and larynx are often complicated by paratonsillitis, parapharyngitis and even mediastinitis and general grave infections (rheumatism, polyarthritis, nephritis, and others).

In addition to the specific features of this medical discipline mentioned above, it should be noted that the mucous membrane of the upper respiratory tract–of the nose, pharynx, and larynx–is like an "open gate" for infection during many systemic diseases. It is responsible for allergization of the organism more than other tissues, and plays a fundamental role in the formation of allergic reactions.

The aim of this textbook is to provide a practical approach to the subject matter. Thus, a coherent step-by-step description of the medical examination of the organs is presented, allowing the student to closely follow and master the techniques. The endoscopic picture, its interpretation, and the complete diagnostic picture of diseases is presented. Methods of local and general therapy have been given major emphasis.

Review questions and problems (case studies) are given at the end of each section to aid the student in consolidation of the material.

The textbook also includes over 80 black-and-white and colour illustrations that have been carefully chosen and limited in number because of its concise format.

In brief, the material covered is organized as follows. First, the essentials of clinical anatomy and physiology are explained followed by methods of examination of the ear, nose, and throat. Next, the general principles of therapy and nursing are given, followed by descriptions of the nosological types of disorders. After this and a discussion on the establishment of diagnosis, the treatment of the given disease is described. Instructions on the preparation for surgery on specific organs and postoperative management are presented.

Separate sections deal in sequence with disorders of the nose and the paranasal sinuses, the throat and oesophagus, the larynx, trachea and bronchi, and the ear. A special section is devoted to tumours and their classification (tumours of the respiratory tract, benign tumours, malignant tumours, and tumours of the ear), and specific diseases (tuberculosis, scleroma, syphilis).

This book is intended as an introductory course to diseases of the ear, nose, and throat. Knowledge of the essentials of this specialty will also contribute to the formation of clinical thinking in all other medical disciplines.

The authors will be most grateful to the readers for their comments and suggestions.

V. Palchun

CONTENTS

Diseases of the Nose and Paranasal Sinuses 9

Clinical Anatomy 9
Clinical Physiology 15
Methods of Examination 16
General Therapy and Nursing 21
Diseases of the Nose 22
  Congenital Defects (Malformations) 22
  Diseases of the External Nose 23
  Diseases of the Nasal Cavity 27
  Preparing a Patient for Nasal Cavity Surgery 53
Diseases of the Paranasal Sinuses 54
  Allergic Diseases 54
  Inflammatory Diseases 56
Rhinogenic Complications 68
Fungal Diseases of the Nose and Paranasal Sinuses 70
Pre- and Postoperative Management of Surgical Patients 71
  Review Questions 72
  Problem 72

Diseases of the Pharynx and the Oesophagus 73

Clinical Anatomy of the Pharynx 73
Clinical Physiology of the Pharynx 77
Examination of the Pharynx 79
Clinical Anatomy and Physiology of the Oesophagus 82
Examination of the Oesophagus 83
General Therapy and Nursing 83
  Injuries and Foreign Bodies 85
  Hypertrophy of Lymphoid Tissue of the Pharynx 95
  Inflammation of the Pharynx 99
  Inflammation of the Tonsils 103
  Complications of Tonsillitis 110
  Affections of the Pharynx in Systemic Diseases of the Blood 114
  Chronic Tonsillitis 116
  Prevention of Acute and Chronic Tonsillitis 122
  Fungal Diseases of the Pharynx 123
  Review Questions 124
  Problem 124

Diseases of the Larynx, Trachea and Bronchi 125

Clinical Anatomy 125
Clinical Physiology 128

Methods of Examination 130
General Therapy and Nursing 136
Injuries and Foreign Bodies 139
Oedema of the Larynx 145
Acute Laryngitis 147
Fungal Diseases of the Larynx 152
Chronic Laryngitis and Tracheitis 152
Chondroperichondritis of the Larynx 154
Stenosis of the Larynx 155
Disorders of Laryngeal Nerves 160
Review Questions 162
Problem 162

Diseases of the Ear 163

Clinical Anatomy 163
Clinical Physiology 169
Methods of Examination 171
General Therapy and Nursing 184
Diseases of the External Ear 186
Injuries and Foreign Bodies 186
Abnormality of the External Ear 192
Inflammatory Diseases 193
Diseases of the Middle Ear 199
Catarrhal Otitis 200
Aero-otitis (Barotitis) 203
Acute Otitis 203
Mastoiditis 214
Traumas 217
Chronic Suppurative Diseases 218
Tympanoplasty 224
Diseases of the Internal Ear 224
Labyrinthitis 224
Vestibulocochlear (Cochlear) Neuritis 225
Ménirère's Disease 227
Otosclerosis 229
Otogenic Intracranial Complications 231
Surdology and Hearing Aids 241
Review Questions 243
Problem 243

Tumours 244

Tumours of the Respiratory Tract 244
Benign Tumours 244
Malignant Tumours 248
Tumours of the Ear 254

Specific Diseases 257

Tuberculosis 257
Scleroma 260
Syphilis 262

DISEASES OF THE NOSE AND PARANASAL SINUSES

CLINICAL ANATOMY

External nose (*nasus externus*). There are the external nose, the nasal cavity and the paranasal sinuses. The skeleton of the external nose (Fig. 1) is formed by bones and cartilages. The bony part of the nose is formed by paired nasal bones and by the frontal processes of the maxilla. The free ends of these bones form a piriform aperture. The cartilaginous framework of the nose includes triangular cartilages, paired alar cartilages, and the accessory cartilages. The triangular cartilages are continuous with the anterior edge of the nasal bones and the frontal processes of the maxilla. The skin on the external nose has many sebaceous and sweat glands. The upper narrow part of the nose is called the root. The dorsum (or ridge) of the nose ends in a soft formation consisting of

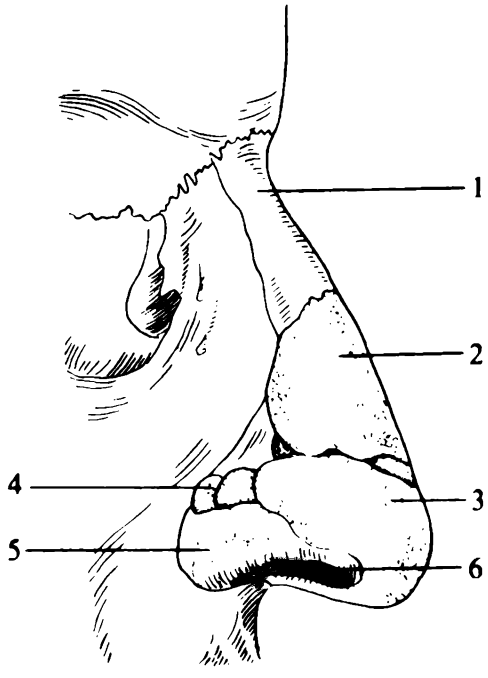

Figure 1
External nose:

1 - nasal bone;
2 - lateral triangular cartilage;
3 - greater alar cartilages;
4 - lesser alar cartilages;
5 fatty tissue of the ala;
6 - nostrils

skin and subcutaneous cellular tissue. The lateral movable parts of the nose (alae) slightly protrude outside to form the nostrils, which, together with the nasal septum, form the entrance (vestibule) to the nasal cavity. The inner part of the nostrils (about 4-5 mm) is covered with fine hairs (cilia) and sebaceous glands.

The external nose is supplied with blood via branches of the ophthalmic artery. The blood outflows through the anterior facial and angular veins into the superior ophthalmic vein which communicates with the cavernous sinus.

The lymphatic vessels of the external nose form a deep and superficial network; they anastomose with the lymphatic vessels of the face and drain into the parotid and submandibular lymph nodes.

The external nose is innervated by the fifth and seventh pairs of the cranial nerves.

Nasal cavity (*cavum nasi*). The nasal cavity is found in the

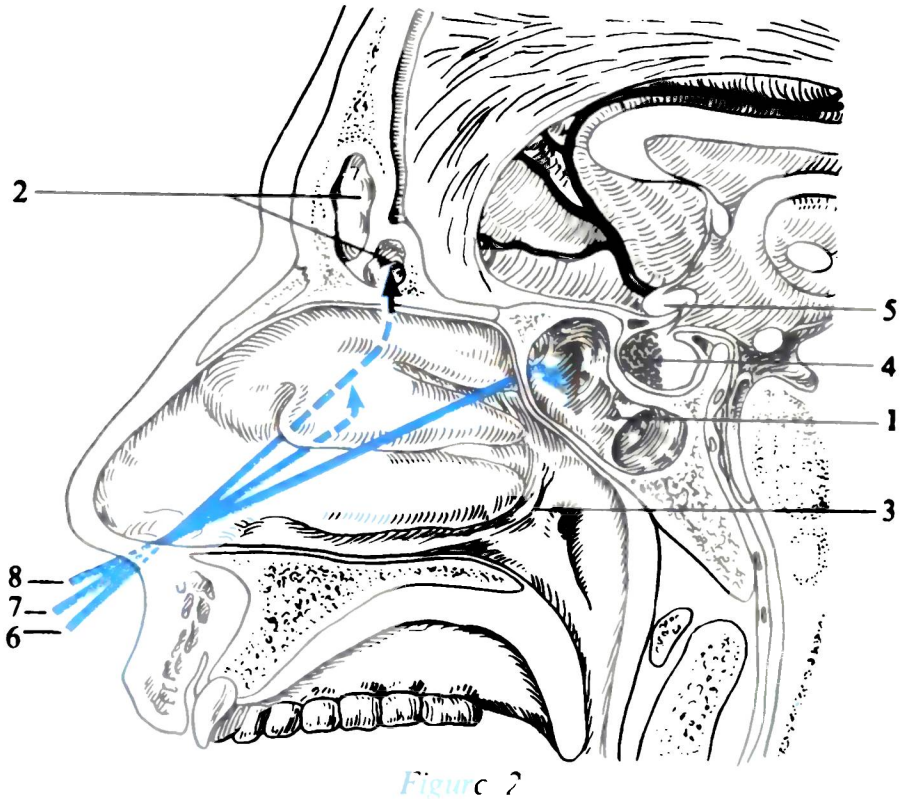

Figure 2

Sagittal section of the nose:

1 sphenoidal sinus;
2 – frontal sinus;
3 – nasopharyngeal groove and the opening of the auditory tube;
4 pituitary gland;
5 – optic chiasma;
6 – entrance to the frontal sinus;
7 – entrance to the maxillary sinus;
8 entrance to the sphenoidal sinus

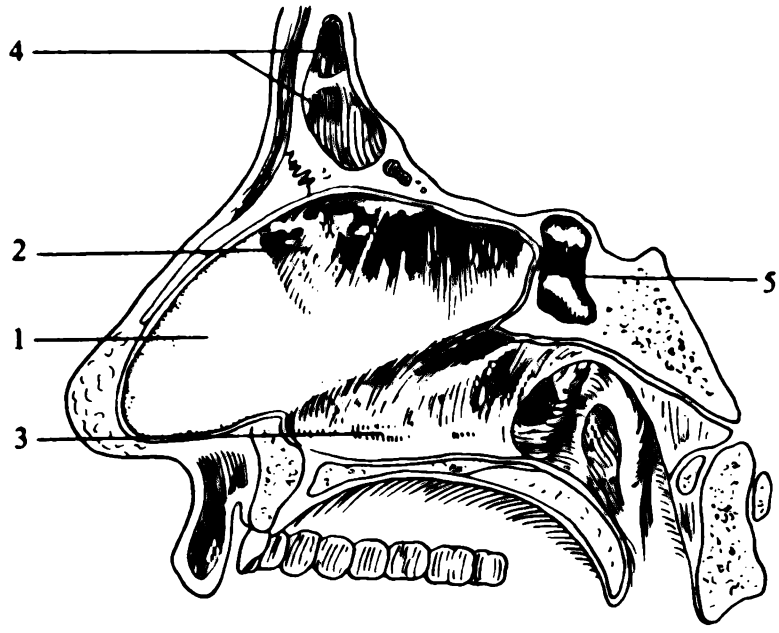

Figure 3
Nasal septum:

1–septal quadrilateral cartilage; *2*–perpendicular plate of the ethmoid bone; *3*–vomer; *4*–frontal sinus; *5*–sphenoidal sinus

middle of the upper facial part of the cranium. It includes the nasal cavity proper and the paranasal sinuses, lying superiorly, laterally, and posteriorly to the nasal cavity. The sinuses are frontal, ethmoidal, maxillary and sphenoidal. The nasal cavity is divided by the septum into the right and left parts, into which the paranasal sinuses and the cells of the ethmoidal labyrinth open. The anterior part of the nasal cavity opens with a piriform sinus (anteriorly) and choanae (posteriorly). The nasal cavity has four walls, namely, the superior, inferior, internal, and external walls.

The inferior wall (the floor) of the nasal cavity is the hard (bony) palate (Fig. 2).

The superior wall (the roof) of the nasal cavity includes the bones of the nose anteriorly, the cribriform plate and cells of the ethmoid bone in the middle (the greater part of the roof) and the anterior wall of the sphenoidal sinus. The fibres of the olfactory nerve (whose bulb is found on the under surface of the cerebral hemisphere) and the branches of the ethmoidal artery and the veins pass through the perforations of the cribriform plate.

The medial (internal) wall, or the septum, (Fig. 3) consists of the anterior cartilaginous and posterior bony parts. The bony part of the septum is formed by the perpendicular plate of the

ethmoid and the vomer. The cartilaginous part of the septum is a rectangular structure whose upper edge forms the anterior part of the dorsum. The nasal septum is usually slightly deviated to either of the sides. Significant deviation of the septum from its normal position can impair nasal respiration.

The lateral (external) wall of the nasal cavity has a more complex structure. Three nasal conchae extend from the external wall toward the nasal septum: the superior, middle and inferior conchae. Three nasal meatuses (groovelike passages) are distinguished accordingly: the superior, middle, and inferior meatuses. The space between the nasal conchae and the septum, extending from the floor to the roof of the nasal cavity, is called the common nasal meatus. A nasolacrimal duct opens into the anterior part of the inferior nasal meatus.

The middle meatus contains a crescent-shaped semilunar hiatus where the maxillary and frontal sinuses, and also the anterior and middle cells of the ethmoidal labyrinth open. The posterior cells of the ethmoidal labyrinth open into the superior nasal meatus. A communication with the sphenoidal sinus is found somewhat superiorly.

The nasal cavity is lined with the mucosa which is continuous with the mucosa of the paranasal sinuses, the pharynx, and the middle ear. The nasal cavity can be divided into three parts: the anterior (vestibule), respiratory, and the olfactory.

The respiratory part of the nasal cavity extends from the floor to the inferior border of the middle concha. The mucosa lining this cavity consists of multilayered columnar ciliated epithelium rich in goblet cells, which produce mucus, and serous glands producing serous or seromucous secretion. The mucosa of the concha overlies the cavernous tissue which can become engorged instantaneously, thus narrowing the nasal meatuses or, on the contrary, become contracted.

The olfactory part of the nose is found in the superior regions of the nasal cavity; it extends from the inferior border of the middle concha to the roof. The mucosa of this part of the nasal cavity is lined with olfactory epithelium, with inclusion of islets of ciliated epithelium, which performs here the filtering function.

The nasal cavity is supplied with blood via the branches of the carotid arteries. The outflow of the blood is through the anterior facial and ophthalmic veins. The veins of the posterior parts

of the conchae empty into the pharyngeal veins. The anterior part of the nasal septum has an area (Kiesselbach's area) which is usually covered with a small vascular varicosity. It is often called the bleeding area, because it is a common locus of nasal bleeding.

The lymph from the anterior parts of the nose flows into the submandibular lymph nodes; the lymph from the middle and posterior parts of the nose is drained into the deep cervical lymph nodes.

Three types of innervation are distinguished in the nasal cavity: the olfactory, sensory, and secretory. The olfactory fibres (about 20) originate from highly differentiated cells and pass to the olfactory bulb through the cribriform plate. The sensory innervation of the nasal cavity is accomplished by the first and second branches of the trigeminal nerve.

The secretory innervation of the nasal cavity is represented by the sympathetic nervous system. The fibres of the sympathetic nerve pass from the pterygopalatine ganglion. They serve to communicate with the sympathetic nerves of the thoracic, abdominal, and endocrine organs. All this establishes reflex connection between the nasal cavity and other organs and systems.

Paranasal sinuses. The paranasal sinuses are located by sides of the nasal cavity and communicate with it (Fig. 4). There are

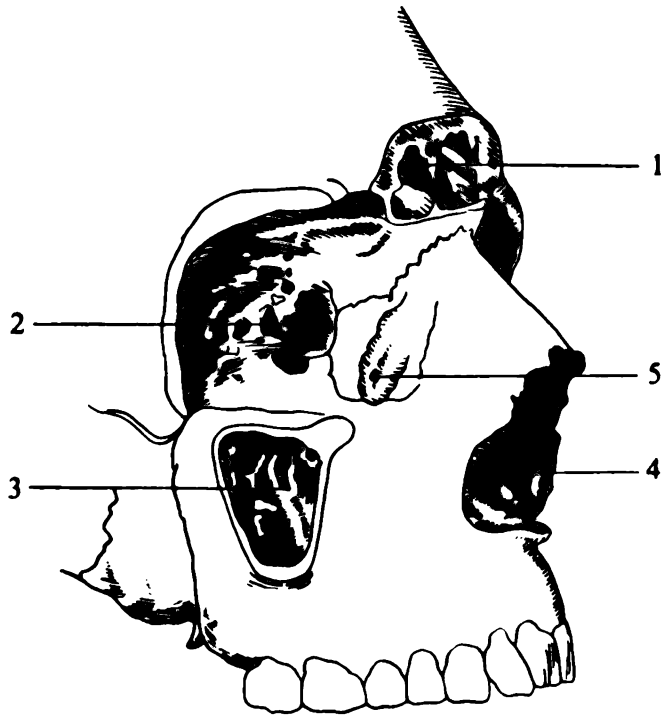

Figure 4
Human skull with the paranasal sinuses open (after Onodi):

1 – frontal sinus;
2 – ethmoid bone cells are open from the orbit;
3 – maxillary sinuses;
4 – nasal cavity;
5 – lacrimal fossa

four paired air cavities, namely, the maxillary, cells of the ethmoidal labyrinth, frontal, and sphenoidal.

The *maxillary sinuses* are located inside the maxilla; these are the largest paranasal sinuses. The external surface of the maxillary sinus has a depression which is known as the canine fossa. The medial wall of the maxillary sinus, or the lateral wall of the nasal cavity, has 2-3 openings at the level of the middle nasal concha, through which the sinus communicates with the nasal cavity.

The upper wall of the maxillary sinus is at the same time the inferior wall of the orbit. The alveolar process of the maxilla forms the lower wall (the floor) of the sinus. In most adults, the floor of the sinus is found below the floor of the nasal cavity. The posterior wall of the sinus is thick; it is formed by the maxillary tuberosity.

The *ethmoidal sinuses* (ethmoidal labyrinth) consist of air cells of the ethmoid which is located between the frontal and the sphenoidal sinuses. Anterior, middle, and posterior cells of the labyrinth are distinguished (6-7 cells of each type on either side). In healthy man the cells are filled with air.

The *frontal sinuses* are found in the squama of the frontal bone. Each sinus has four walls: the anterior (facial); the posterior, which borders with the cranial fossa; the inferior, which in most cases is the superior wall of the orbit and borders with the cells of the ethmoid and the nasal cavity over a small area; and the internal wall (the septum).

The *sphenoidal sinuses* are found in the body of the sphenoid bone. The septum separating the sinuses extends anteriorly to the nasal septum.

A neonate has only two pairs of paranasal sinuses: the maxillary and the ethmoidal; these sinuses are only in their initial stage of development. The frontal and sphenoidal sinuses are absent in neonates; their formation begins only 3-4 years later. The topography of the paranasal sinuses approaches its final development by the age of 12.

The mucosa of the paranasal sinuses is continuous with the nasal mucosa but differs from the latter in thickness and the absence of the cavernous tissue.

The paranasal sinuses are supplied with blood through the branches of the external and internal carotid arteries. Blood drains through the veins that anastomose with one another and empty into the veins of the external nose, face, orbit, cerebral veins,

venous plexuses, and the cranial sinuses. The lymph outflow is directed to the retropharyngeal, submandibular and deep cervical nodes. The paranasal sinuses are innervated by the first and second branches of the fifth pair of the cranial nerves. The sympathetic innervation originates from the pterygopalatine ganglion.

CLINICAL PHYSIOLOGY

Nasal respiration is very important because, in addition to the respiratory function, the nose also performs the protective, resonating, and olfactory functions, and is also involved in the regulation of respiration and lacrimation.

The *respiratory function* of the nose is part of the entire respiratory function in man. During inspiration, which is due to creation of negative pressure in the chest, air enters both parts of the nasal cavity mostly through the respiratory part of the nose. The inspired air passes upwards and then descends by the superior and middle conchae and passes posteriorly to the choanae. The pressure of the air on the nasal mucosa excites the inspiratory reflex. If a subject breathes through his mouth, the inspiration becomes shallow and the amount of the air oxygen intake decreases; this in turn can cause a pathological effect on the nervous, vascular, circulatory, and other systems of man (especially in children).

The *protective function* of the nose consists in warming the inspired air, its moistening and filtering. Cold air stimulates a rapid expansion of the cavernous sinuses and their filling with blood. The volume of the conchae thus increases significantly; their surfaces become enlarged as well, and the nasal passages are narrowed accordingly.

The inspired air is moistened by the wet mucosa. As the air passes through the vestibule of the nose, large dust particles are retained by thick hairs. Fine dust and air-borne microbes, that pass first filter, are precipitated on the nasal mucosa moistened with mucous secretion. Dust is also retained because the nasal passages are narrow and curved. About 40-60 per cent of dust particles and microbes inspired with air are retained in the nose and then removed from it with mucus. This function is performed by ciliated epithelium whose reciprocating movements propell the mucus toward the nasopharynx. When treating diseases of the nose, it is necessary to remember that in addition to

the therapeutic effect, prolonged instillation of liquid medicines into the nose can produce an adverse effect on the draining function of the ciliated epithelium. Prolonged administration of oil, soda, vasoconstrictive and other solutions should therefore be avoided whenever possible. Lysozyme, contained in the nasal mucus and secretion of the lacrimal glands, has a marked disinfecting property.

The sneezing and lacrimal reflexes are also important protective mechanisms. Dust particles, cold, chemical, mechanical, and other factors can stimulate these reflexes. The olfactory, trigeminal, and facial nerves are involved in the reflex arc to stimulate contraction of the muscles of the face, trunk, and the limbs.

The *olfactory function* in man is provided by the olfactory mucosa that contains the neuro-epithelial fusiform olfactory cells, which are chemoreceptors. When the olfactory slit is narrowed or closed, respiratory hypo-osmia or anosmia develops. Defects of olfaction can also be caused by the affection of the nervous receptor cells in the presence of adequate nasal respiration. The molecules of gases, vapour, mist, dust, or smoke stimulate the olfactory receptors. It should be noted that man can also perceive odour of some substances (e.g. spirit of ammonia) that act on the endings of the trigeminal nerve.

The *resonating function* of the nose accounts for the special timbre of the human voice. Pathological changes in the nasal cavity or in the nasopharynx (polyps, hypertrophy of the conchae, inflammation of the nasal mucosa, tumour, adenoids, and other changes) cause rhinolalia clausa (nasal speech). If the nasal cavity has unusually large communication with the nasopharynx (e.g. due to the absence of the soft palate or its paralysis), the patient develops rhinolalia aperta.

METHODS OF EXAMINATION

Examination of the nose and the paranasal sinuses includes external inspection, palpation, and inspection of the internal cavities using special tools, X-ray examination and diaphanoscopy (transillumination).

The patient sits so that the source of light and the tool bench are on his right side; the physician sits facing the patient; the source of light should be placed level with the patient's right auricle, at a distance of 10 cm; the head mirror should

Figure 5
Head position during anterior rhinoscopy:
a - first position; *b* - second position

be at a distance of 25-30 cm (focal distance) from the organ to be examined; the correct placement of the light source and the head mirror ensure adequate illumination of the internal cavities (Fig. 5).

Examination of the nose. The physician should inspect the external nose and the sites of projection of the paranasal sinuses on the face.

The external nose should be palpated. Palpation should also be used to examine the anterior and inferior walls of the frontal sinuses, the anterior walls of the maxillary sinuses, and also the cervical regional lymph nodes.

The respiratory function of the nose should be examined separately on each side. To that end, the wing of the right nostril is pressed to the nasal septum using the second finger of the left hand, and the patient is asked to breathe air quietly in and out (as in ordinary respiration); a small piece of cotton wool held close to the left nostril will show if the passage is free. Air passage through the right half of the nasal cavity should be examined in a similar way (Fig. 6).

Nasal breathing can be normal, impeded, or it can be absent. The respiratory function of the nose is assessed from the patient's complaints, findings of the examination (with cotton wool), and by rhinoscopy. A special rhinopneumometer is used for a more accurate assessment of the nasal breathing function.

The olfactory function of each side of the nose is tested separately using odoriferous substances from a special olfactometric

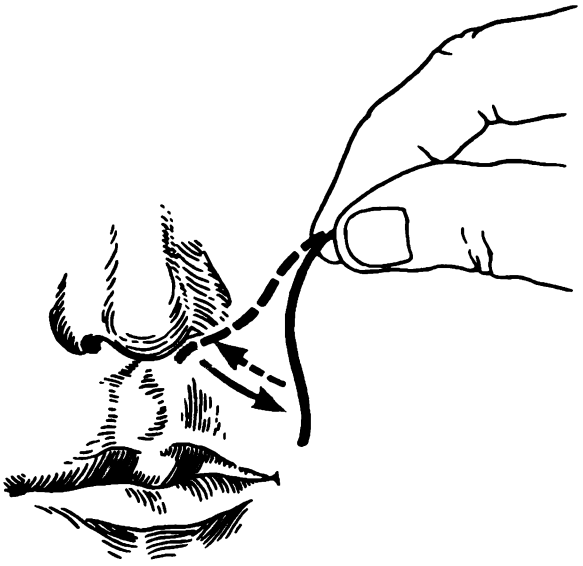

Figure 6
Checking respiratory function of the nose by holding a cotton thread to the nostril

set, or using a special instrument called olfactometer. The technique for testing the olfactory function is the same as that described for testing the respiratory function.

Olfaction can be normal (normosmia), decreased (hyposmia), perverted (cacosmia), or it can be absent (anosmia).

Rhinoscopy can be anterior, middle, and posterior. In order to inspect the vestibule of the nose, the tip of the nose should be raised slightly using the first finger of the right hand. A normal vestibule is free; its walls are covered with hairs. Anterior rhinoscopy should be carried out on both sides of the nose. The nasal dilator should be placed on the open palm of the left hand with the beak down. The first finger of the left hand is placed on top of the screw; the second and third fingers, on the handle; and the fourth and fifth fingers, between the handles. This position of the fingers is convenient for opening and closing the nasal dilator. The elbow of the left arm should be lowered, while the wrist of the hand holding the dilator should move freely. The palm of the right hand should be placed on the top of the patient's head to set it in a position convenient for rhinoscopy.

The closed valves of the dilator are now introduced into the vestibule of the nose to a distance of 5 mm. The second and third fingers of the left hand press on the handle of the dilator to stretch the nostril so that the distal end of the valves do not touch the nasal mucosa.

The right half of the nose is thus examined with the erect position of the patient's head. The normal colour of the nasal mucosa is pink; its surface is smooth; the normal position of

the septum is central; the nasal conchae are of normal size and the common nasal meatus is patent (Fig. 7). The other side of the nose should be examined in a similar way.

In order to withdraw the dilator from the nose, set the valves slightly apart so as not to capture the hairs in the vestibule, and then remove the dilator.

Inspection of the posterior parts of the nose is called posterior rhinoscopy (epipharyngoscopy) (Fig. 8). To that end, the nasopharyngeal speculum is fixed in the handle and the mirror surface of the speculum is warmed up (check the degree of warming by touching the back of the hand to the mirror). The speculum should now be held in the right hand and the spatula in the left hand. The spatula should be held so that the

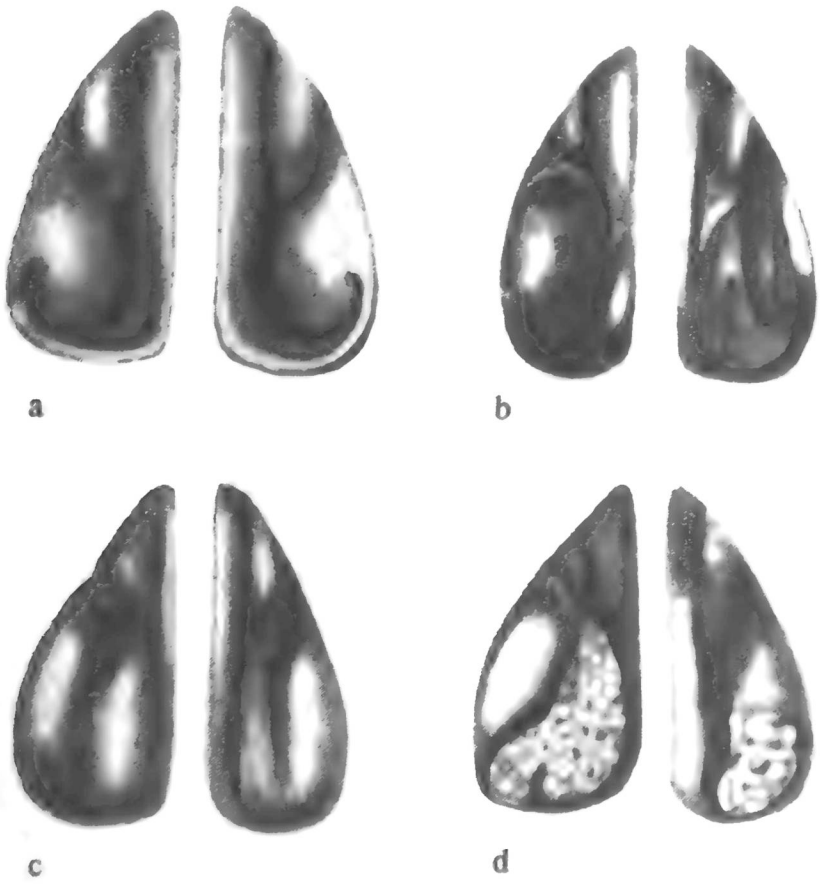

Figure 7

Mucous membrane as viewed during anterior rhinoscopy:

a normal rhinoscopic picture; *b* hypertrophy of the mucosa (on the right before, and on the left after applying adrenaline solution), *c* hyperplasia of the mucosa resistant to adrenaline; *d* papillary hypertrophy of the mucosa (mulberry-like growth)

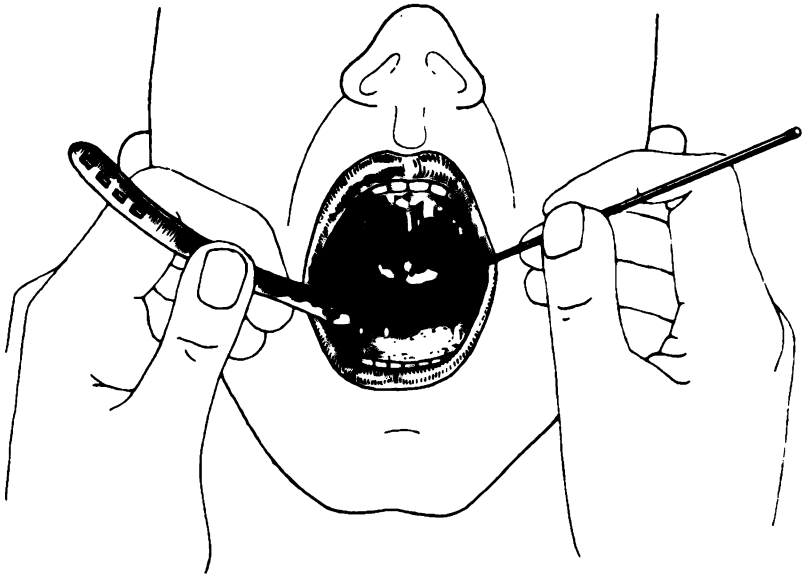

Figure 8
Inspection of the posterior portions of the nasal cavity

first finger rests on its lower surface while the second, third and fourth fingers on the upper surface. The spatula should be introduced into the right angle of the mouth to press the tongue aside. The nasopharyngeal speculum should simultaneously be introduced into the mouth at its left angle. The mirror surface should be directed upwards. The speculum should be moved into the mouth to the distance beyond the soft palate. The posterior parts of the nasal cavity are inspected by slightly turning the speculum to the required side. The posterior ends of the nasal conchae, the nasal meatuses, and the vomer can thus be inspected. The nasopharynx can be examined in a similar way.

Examination of the paranasal sinuses. X-ray and electrography are the main diagnostic methods for examining the paranasal sinuses. X-ray pictures of several projections should be made.

Diaphanoscopy (transillumination) is another important method of examination (Fig. 9). The procedure should be performed in a dark room. A 12 W burning lamp is introduced into the patient's mouth and the lips are closed. In the absence of pathology in the maxillary sinuses, the patient's face glows diffusely pink with brightly luminescing floors of the orbits and crescents of light under each eye (the pupils appear as pink circles). In the presence of unilateral sinusitis this picture can only be observed on one (healthy) side of the face. Transillumination can also be used to examine the frontal and the ethmoidal sinuses.

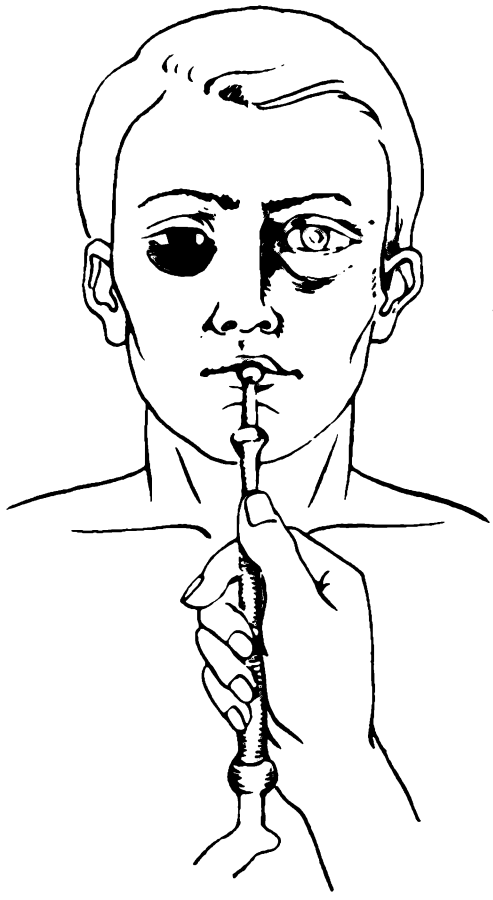

Figure 9
Diaphanoscopy

The paranasal sinuses can also be punctured or probed for diagnostic purposes, but these manipulations can, however, be performed only by a physician.

GENERAL THERAPY AND NURSING

Diseases of the nose and its paranasal sinuses can be treated conservatively and surgically.

Conservative treatment includes instillation of various medicinal solutions, insufflation of powders, inhalation of various solutions of drugs, and external application of ointments.

Surgical treatment includes cauterization of the mucosa with galvanic current and chemical substances, puncturing of the sinuses, extirpation of polyps, probing, removal of the conchae, resection of the distorted portion of the nasal septum, etc.

Surgical operations on paranasal sinuses require special pre-operative treatment and postoperative care of the patient.

Nasal drops should be instilled with the patient in the lying position. The head should be dropped back and turned to the

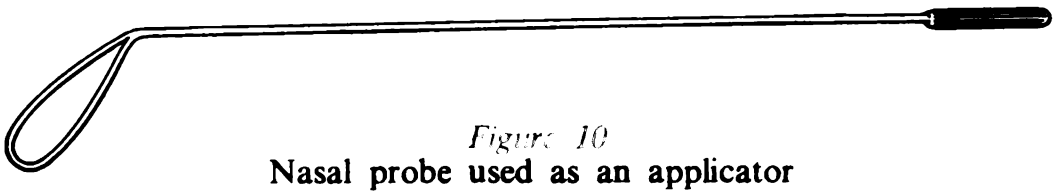

Figure 10
Nasal probe used as an applicator

involved side. Adults are given 5 drops into each nostril; the dose for children is 3 drops in each side of the nose.

Powdered medicines are blown into the nose by special apparatus called insufflator.

Medicines (solutions and oils) can also be administered into the nasal cavity by inhalation. A glass rod (ophthalmic spatula) or cotton wool on an applicator (Fig. 10) are used to apply ointments to the vestibule of the nose. The patient should press the wing of the nose to the nasal septum and massage to distribute the ointment over the mucosa. The procedure should continue for about 20 seconds.

Removal of pathological contents from the nose by suction is another useful manipulation. A special aspirator or a rubber bulb should be used for the purpose. Special care should be exercised when removing nasal contents by suction in order to prevent possible damage to the nasal mucosa and subsequent bleeding.

Care of patients with pathology of the nose or paranasal sinuses, who are treated conservatively, is not difficult. The main duty of the nurse is to fulfil orders of the physician.

DISEASES OF THE NOSE

CONGENITAL DEFECTS (MALFORMATIONS)

Congenital defects of the external nose due to inadequate intrauterine development are relatively rare. These are complete absence or underdevelopment of the nose, hyperplasia of its separate parts, incorrect position of the nose or of some of its parts. Developmental anomalies are double nose, split nose, nose in the form of one or two trunks, the absence of one or both parts of the external nose, fistulae or cysts of the nose, defective conchae, and atresia of the choanae. Malformations of the nose frequently concur with developmental defects of some other organs and parts of the body, e.g. harelip or cleft palate, underdevelopment of the brain, limbs, etc.

Malformations of the nose can only be treated surgically.

Operations should preferably be performed during the first year of the child's life. If the defect is dangerous to life, the operation can be carried out on neonates.

DISEASES OF THE EXTERNAL NOSE

Burn of the nose. As a rule this is the result of the burn of the entire face. The causes are quite varied: sun-rays, acids, hot water, etc.

Symptoms include hyperaemia, tenderness, and swelling of the skin. Pain subsides in 4-5 days, and the skin darkens. Desquamation of the corneal layer is observed during subsequent days.

Diagnosis is established on the basis of anamnestic findings and the examination. In rare cases, the severity of the burn exceeds stage I.

Treatment includes general means for treating burns. Antimicrobial ointments containing hormones are used locally. A 10 per cent synthomycin or oxycort ointments are applied to the affected surface.

Frostbite is a frequent affection of the nose.

The *symptoms* usually depend on the duration and intensity of freezing. In mild cases, the tip of the nose becomes cyanotically red. In warm room, the skin begins itching. In severe cases bullae, foci of necrosis, and even trophic ulcers develop on the frost bitten surface.

The *diagnosis* is not difficult and is based mainly on the anamnesis and examination.

Treatment in mild cases includes thermotherapy (compresses) and application of oxycort ointment to the affected skin. In severe cases, the patient should be hospitalized for general and local anti-inflammatory treatment.

Erysipelas. This is a diffuse contagious disease caused by *Streptococcus pyogenes*. The condition is often attended by a pronounced general reaction of the body. The nose alone is affected in rare cases; as a rule, erysipelas of the nose is secondary to inflammation of the skin of the face. The disease begins with a significant increase in body temperature (38-40°C). Chills, headache, and marked deterioration of the patient's condition are characteristic. The regional lymph nodes are markedly enlarged. The skin at the affected site is strongly hyperaemic, with significant infiltrations, and epidermal bullae; it is tender to

palpation. The inflammation can extend from the skin at the nose vestibule onto the mucosa of the nasal cavity. Propagation of the disease is facilitated by scratching, cracks, and purulent affections of the nose and the paranasal sinuses.

The diagnosis is not difficult as a rule. The patient should be treated in hospital. Antibiotics (synthomycin, laevomycetin, penicillin, etc.) rather rapidly remove the inflammatory reaction; exposure to quartz light (erythema dose) and application of antiseptic ointments are also helpful.

Eczema of the vestibule of the nose is an allergic disease and can be due to metabolic disorders. The incidence is low. The acute course is characterized by the following signs: pronounced erythema, swelling, desquamation of the epidermis, occasional bullae, crusts at the vestibule of the nose, and cracks of the skin. The disease often extends (especially in children) onto the skin of the face, ears, and the head. The general condition remains satisfactory. Eczema can provoke furunculosis, sycosis, erysipelas, and some other diseases.

Treatment includes elimination of purulent foci in the nasal cavity and the paranasal sinuses and of other sources of chronic infection in the patient (chronic tonsillitis, dental caries, and the like), management of systemic diseases, and anti-allergic therapy with antihistaminics. The envigorating therapy with iron and arsenic preparations, vitamins A and C, cod-liver oil, and quartz light is also indicated. The skin is treated locally with vegetable (olive, peach-kernel) or mineral oil with subsequent application of antibiotic and steroid ointments (oxycort and others). Cracked skin is treated with a 2-5 per cent silver nitrate solution or mercury ointments. The application of ointments should be continued after the surface signs of the disease subside, i.e. until complete normalization of the skin.

Sycosis (folliculitis) of the nasal vestibule is a relatively common disease. It is a circumscribed purulent inflammation of the hair follicles at the nasal vestibule and the adjacent areas of the upper lip. The aetiological factor is *Staphylococcus aureus*. The infection is commonly carried into the nose when picking it to remove crusts, especially the crusts of pustules. Purulent diseases of the nasal cavity and the paranasal sinuses facilitate the development of the infection. Inspection reveals small red nodules with pustule through which a hair passes. The course of the disease is chronic, with exacerbations. The patient complains of itching and burning in the nose, pain and tension of the skin

at the vestibule. Large crusts often accumulate here which impede breathing.

Diagnosis is simple; it is only difficult to differentiate between sycosis and eczema in their mutual presence.

The disease can be *treated* under out-patient conditions. The sycosis-affected skin is treated with boric or salicylic alcohol, the affected hairs are then removed, and synthomycin ointment applied. Oxycort, hydrocortisone and other ointments can also be used. UHF-therapy is useful in between these procedures. Severe (long-standing) cases should be treated with X-rays in epilating doses.

Furuncle, or boil, of the nasal vestibule is an acute inflammation of the hair follicle or sebaceous gland; it often concurs with general furunculosis. The main aetiological factor is an injury, local impairment of resistance of the skin or body to staphylococci and streptococci. Some systemic diseases, e.g. diabetes mellitus, metabolic disorders, hypovitaminosis, tuberculosis, or chilling, can provoke furunculosis of the nose. Asthenic children often develop furunculosis. If two or more furuncles fuse into a carbuncle, the local and general inflammatory reaction markedly increase.

It is important to foresee a possible formation of septic thrombi in small veins in the inflammatory infiltration that surrounds the hair follicle or the sebaceous gland. The infection can be carried by the venous blood to the cavernous sinus and other cavities of the skull with subsequent severe intracranial complications and sepsis.

The clinical picture is characterized by severe pain in the inflammation focus, circumscribed cone-shaped infiltrate covered with hyperaemic skin, whose top in 3-4 days becomes crowned with a yellowish pustular head, which ripens during the next 4-5 days, and the inflammation then resolves. The furuncle can sometimes turn into an abscess. The general reaction of the body in mild cases can be either insignificant or absent altogether. If the course of furunculosis is unfavourable and a carbuncle develops, the body temperature can rise, the ESR accelerate, leucocyte counts increase, and the regional lymph nodes become enlarged and tender.

Treatment includes administration of antibacterial preparations, such as erythromycin, tetracycline, sulpha drugs, etc., polyvitamins, and (locally) quartz lamp and UHF. The skin around the furuncle is treated with boric alcohol. It is absolutely pro-

hibited to express the furuncle contents because of the danger of intracranial complications and sepsis. Ichthyol or balm ointments should be applied locally until the furuncle ripens. Location of the furuncle permitting, a sterile cotton ball or gauze with ointment can be put into the vestibule of the nose. The size of the ball should be large enough to ensure a moderately tight fit in the nostril as not to fall out, or the ball can be held in place with a four-tailed bandage or adhesive tape. The therapeutic tactics should be different if the soft tissues around the furuncle become infiltrated. The infiltration can extend onto the other parts of the face. The patient's condition then worsens, the leucocyte counts increase, and the ESR accelerates. The patient should be taken to hospital in view of possible complications such as rhinogenic sepsis or thrombosis of the cavernous sinus.

Common acne (acne vulgaris) usually occur on the lower third of the nose due to obstruction of the sebaceous ducts and a relative hypersecretion of sebaceous glands.

Common acne is usually *treated* by drainage of the cystic lesions and exposure to quartz light. Sun-rays are also helpful.

Rosacea and rhinophyma. Acne rosacea can occur due to period-

Rhinophyma

ic or permanent hyperaemia of the skin of the nose due to dilatation of subcutaneous and cutaneous blood vessels caused by local disorders in the vegetative innervation. Rosacea usually affects the lower part of the external nose but can also extend onto the cheeks and the forehead. The disease runs a chronic course and is characterized by development of red nodules and dilated vessels. If the disease is long-standing, telangiectasia can develop with hypertrophy of all skin layers, sebaceous glands, blood and lymphatic vessels (uniform or nodular soft infiltration). The hypertrophy is rounded into formation known as rhinophyma. It can be as large as 5-6 cm in diameter. The surface of rhinophyma is nodular. It often appears as three papules: the anterior and the lateral ones. Their colour is red-blue or pale-pink. Rhinophyma disfigures the face. It occurs rarely and mostly in the aged men (Fig. 11). Rhinophyma is commonly associated with alcoholism and frequent exposure of the nose to cold.

Treatment is surgical. The hypertrophied parts of the skin are cut off with a sharp blade to restore the normal shape of the nose. The operation is carried out under local or general anaesthesia.

DISEASES OF THE NASAL CAVITY

Deformation of the nasal septum. This occurs usually due to injury. Physiological deformation is usually the result of disbalanced growth of the septum and the bony framework into which the septum is included.

Three types of deformities are distinguished: deviated septum, septal spur and shelf. The combination of these three deformities is not infrequent either.

The main complaint of the patient with deviated nasal septum is nasal obstruction. Headache, nasal discharge, occasional pain in the ear, dry throat, etc. also occur in some cases.

Treatment is surgical (Fig. 12). Difficult respiration through one or both sides of the nose is indication for operation. Submucous resection of the deviated part of the septum should be carried out.

Synechia and atresia. Adhesions of the nasal cavity include synechiae (fine adhesions between the nasal septum and the lateral wall of the nose) and atresia (extensive adhesions between the lateral and medial walls of the nose which narrow the nasal meatuses). Congenital atresia can be due to the growth of connec-

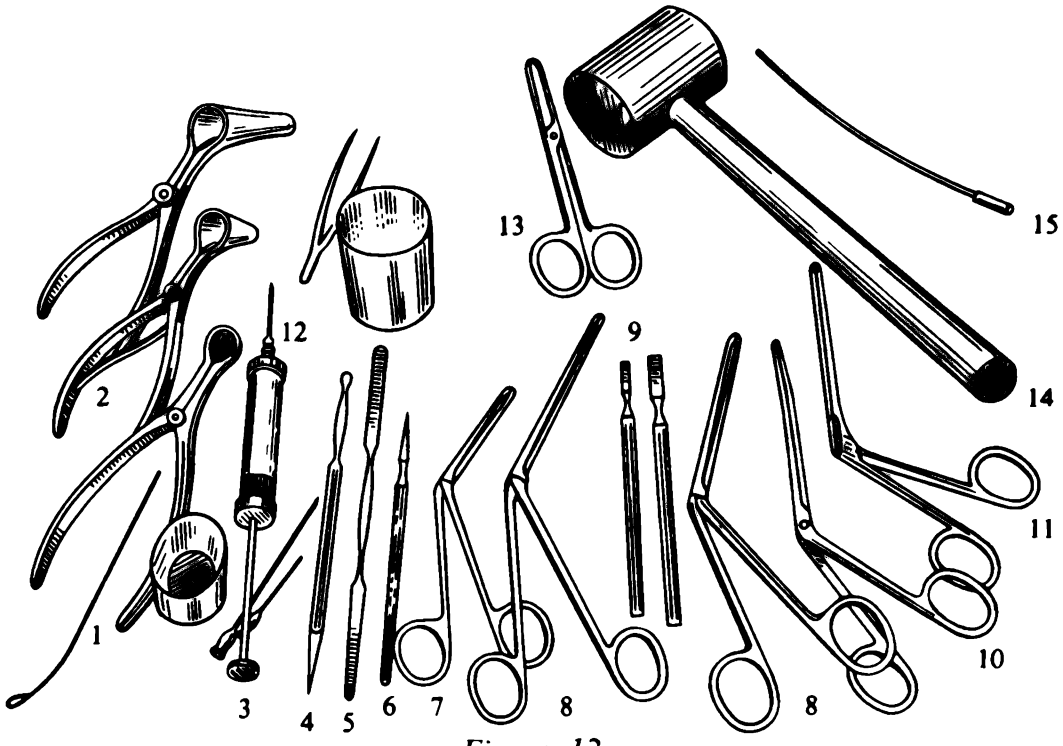

Figure 12

Set of instruments used for operations on the nasal septum:

1–nasal probe;
2–Killian's specula;
3–syringe with needles;
4–Freyer's raspatory;
5–Killian's raspatory;
6–ophthalmological scalpel;
7–aural packer;
8–nasal packer;
9–flat chisels;
10–nasal fenestrated forceps;
11–conchotome;
12–ophthalmic forceps;
13–Cooper's scissors;
14–hammer;
15–aspirator end-piece

tive tissue, cartilage, or bone. Synechia and atresia can occur in ulcerations of the nasal mucosa of various aetiology, in scleroma, lupus, diphtheria, smallpox, typhus, and also in occasional surgical injuries to the nasal mucosa after cauterization with electric current or chemicals.

Diagnosis is established by anterior and posterior rhinoscopy and probing.

Treatment is surgical. The adhesions of the nasal cavity and the choanae are either cut or, if possible, excised.

Foreign bodies in the nose are more common in children who put various small objects, e.g. buttons, balls, kernels, etc., into their noses. Foreign bodies can get into the nose through the choanae, e.g. during vomiting. A foreign body can with time become coated with lime or phosphates to form a rhinolith. As a rule, foreign bodies are retained in the inferior or the common nasal meatus. Frontal and lateral rhinography can reveal a radiopaque foreign body.

Treatment consists in removal of the foreign body. This can

sometimes be easily attained by blowing out through the involved part of the nose. But in most cases foreign bodies are tightly held in nasal meatuses and can only be removed using special tools. The manipulation is carried out with surface anaesthesia with a 5 per cent cocaine solution.

Injuries to the nose (the external nose and the walls of the nasal cavity) usually occur in children and in adult males. Common injuries to the skin are contusions, bruises, abrasion, or wounds. When examining a patient with the injured nose, it is necessary to remember that an injury can only appear superficial while in fact it may be deep and a foreign body may be present in the wound. Injuries to the nose often concur with concussion of the brain. If such suspicion arises, the nasal bones should be examined with X-rays and the patient should be subjected to neurological examination. Contusion and a bruise do not require special treatment except application of cold immediately after the injury; iodine tincture should be used to treat abrasions.

Mild injuries to the nose are usually characterized by the injuries to the skin of the nose alone, while severe injuries usually involve soft tissues, bones and cartilages. It should be remembered that in some cases the skin of the nose can remain intact in the presence of severe damage to the nasal structures. The nose can be partly or completely torn off in gunshot wounds. The skeleton of the nose and the adjacent parts of the face can be crushed. A bullet or a shell fragment can penetrate the nose and enter the paranasal sinuses, the skull, the neck, etc.

Crepitation sounds indicate fractures of the ethmoid bone and rupture of the mucosa. As the patient blows his nose, air passes via the injured tissue to bulge the face skin. The fracture of the cribriform plate is manifested by liquorrhoea from the nose.

X-ray examination usually reveals the character and extent of injury to the nasal and facial bones in the presence of severe oedema and infiltrative swelling of the soft tissues. But the absence of X-ray evidence does not exclude fracture of the nasal bony framework.

Treatment of nasal fractures is most effective during the first hours following the injury. Bleeding from injured tissues should be arrested as soon as possible to prevent massive loss of blood endangering the patient's life. Since injuries to the skin and surface

tissues are always associated with possible ingress of infection, tetanus antitoxin should be administered according to the accepted scheme. If the anamnestic and objective findings indicate possible concussion of the brain (degree II or III), the patient should be given neurological treatment and only later (in one or more days) correction of the displaced bones and more extensive surgical operations should be performed. The primary surgical treatment of the wound should, however, be carried out in such cases: the wound margins should not be excised, and only non-viable tissues should be removed. The face wounds usually heal rapidly because of the intensive blood supply. The wound should be treated with hydrogen peroxide, dried up, and its margins joined by shortly spaced sutures using fine synthetic ligatures (Dacron, caprone, etc.). No special dressing is usually applied. The primary suturing should be done during the course of the first 24 hours following the injury, but suturing at later terms (to 48 hours) is also possible.

Laterally displaced bone fragments should be repositioned using the thumb of the right hand to correct displacement to the left, and of the left hand to correct the displacement to the right (see Fig. 13). A significant effort of the finger is required

Figure 13

Repositioning laterally displaced bone fragments



Set of elevators used for intranasal repositioning of bone fragments (Volkov)

for repositioning of a bone fragment. A specific crunch is heard when the bone fragment is replaced. No anaesthesia is usually required, since the operation lasts only 2-3 seconds. Novocain solution can, however, be injected into the field of injury or the operation can be performed under short-lasting anaesthesia.

Posteriorly displaced bone fragments should be repositioned using nasal elevators (Figs 14 and 15). In most cases, the replaced bone fragments have to be fixed by anterior tamponade of one or both sides of the nose. If fractures are multiple, a firmer and longer immobilization is required. It can be ensured by a turunda soaked in paraffin (melting at 50-54 °C). The paraffin tampon can remain in place for 12 days which is necessary for correct accretion of the fragments, while a common gauze tampon should be removed in 3-4 days. Whenever necessary, fixing rolls and bandages are applied.

The fractured nasal bones are usually repositioned on the day of the injury, but if the patient attends doctor at later terms, the operation can also be performed, although the correction becomes more difficult.

The nurse should be aware of a possible nasal bleeding or dislocation of the bone fragments that are likely to occur during the first day following the surgical correction. In order to prevent these complications, the patient must remain in bed, which is also necessary because nasal fractures are usually attended with concussion of the brain.

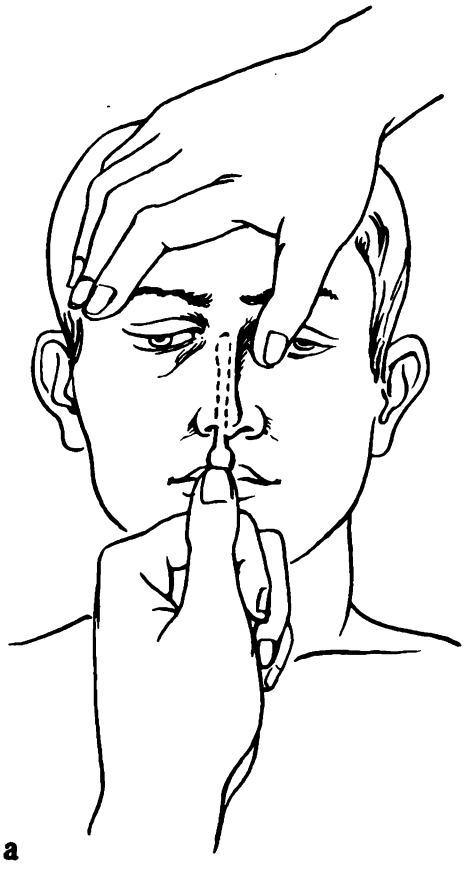

a

b

Figure 15
Repositioning bone fragments in closed fracture of the nasal bones:

a – using tools and fingers;
b – using fingers alone

Injuries to the paranasal sinuses. Injuries to the frontal sinuses stand the first in the list of incidence; next follow the maxillary sinuses and the ethmoidal labyrinth; the sphenoidal sinuses are injured in rare cases. As a rule, the injury to a paranasal sinus is combined with injuries to some other bones of the face and skull. Mechanical or gunshot wounds of the frontal sinus are often attended by the injury to the frontal lobe of the brain, to the ethmoidal labyrinth, the cribriform plate, the superior and interior parts of the orbit. Injuries to the paranasal sinuses are attended by the concussion syndrome more frequently than injuries to the nose. Nasal bleeding is common at the moment of injury and afterwards.

Injuries to the paranasal sinuses with penetration into the skull usually cause general symptoms of brain injuries: loss of consciousness, dizziness, psychic derangement (excitation or inhibition, talkativeness, etc.), vomiting, congestive changes in the fundus of the eye, and cardiovascular dysfunction. The local change at the site of injury is characterized by accumulation of blood in the injured sinus. In some cases, the only sign of bone fracture is

subcutaneous emphysema of the orbit, eyelid, cheek, or forehead. Emphysema can be diagnosed by the specific crepitation which can be heard during palpation of the swollen site. Air can penetrate into the cranium through the infractions in the skull bones; this is due to the difference between the pressure inside the cranium and the atmospheric pressure. Air can also penetrate from the airways during forced expiration, as in coughing or sneezing.

The injury to the ethmoidal labyrinth is usually attended by the injury to the olfactory receptor. Constant hypo-osmia or anosmia thus develops.

General inspection and endoscopy reveal the character of the injury.

Treatment is aimed at arresting bleeding and eliminating shock. These are the first and emergency measures in injuries to the paranasal sinuses. In the presence of brain concussion of degree I, and also in the absence of signs of concussion, the injured site should be given a complete primary treatment including repositioning of the bone fractures. Shock and brain concussion of the second and third degrees require maximum sparing conditions for the patient. The primary treatment of the wound should therefore include arrest of bleeding, suturing the wound, and administering antitetanic serum.

Nasal bleeding is a symptom of a local nose injury or of a systemic disease. Causes of nasal bleeding are therefore classified as local and general. Treatment is distinguished accordingly. The most frequent site of bleeding is the anteroinferior part of the nasal septum (Kiesselbach's area). Haemorrhage into this area is usually mild and presents no special danger. The other parts of the nasal septum can bleed as well (Fig. 16). The superior

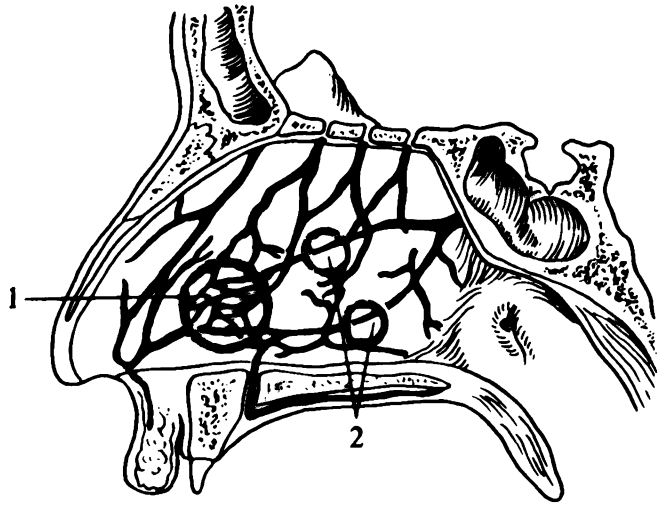

Figure 16
Bleeding zones of the nose:

1 - Kiesselbach's area;
2 - inferior and superior branches of the sphenopalatine artery

and posterior parts of the nasal walls are the sites where bleeding can be profuse.

The most common local cause of nasal haemorrhage is injury which can be slight and thus cause only insignificant bleeding. The injury can be severe, with affections of the facial framework, causing profuse haemorrhage endangering life of the patient.

General causes of nasal bleeding are diseases of the blood and the circulating system. Nasal bleeding is often the first sign of developing essential hypertension. Relapsing nasal bleeding often occurs in patients with hypertension and nephronecrosis or contracted kidney. Nasal bleeding can also be caused by blood congestion in heart diseases, lung emphysema, diseases of the liver and spleen, and in pregnancy.

Severe nasal bleeding occurs in haemorrhagic diathesis, including haemophilia, haemorrhagic thrombasthenia, thrombopenic purpura, haemorrhagic vasculitis, capillary toxicosis, and telangiectasia (Osler-Rendu syndrome). The causes of nasal bleeding in these diseases are different. In some cases bleeding is caused by disorders in the blood coagulation system, and in others by the affections of the vascular walls. Diseases of the haemopoietic system (leucosis, reticulosis, haemocytoblastosis, etc.) can also be attended with bleeding from the nose and the mucosa of other organs.

Various other factors, such as hypo- and avitaminosis, especially vitamin C deficiency, vicarious menstruation (instead of normally expected menstruation), and also low atmospheric pressure, physical overstrain, exposure to heat and some other factors, can also cause nasal haemorrhage.

Clinical picture. In some patients nasal bleeding begins unexpectedly, while other patients complain of prodromal disorders such as headache, noise in the ears, dizziness, itching and prickling in the nose. It should be remembered that blood can get into the nose from other parts of the upper airways, e.g. from the pharynx, larynx, trachea, oesophagus, the lung and sometimes even from the middle ear through the auditory tube. The diagnosis is established by rhinoscopy, pharyngoscopy, and inspection of the other related organs.

Mild, moderate, and profuse nasal bleedings are distinguished. Mild nosebleed usually originates from the Kiesselbach area. The bleeding is transient and only a few millilitres are lost. Such bleedings stop spontaneously. Though appearing as harmless, frequently recurring mild bleeding can have an adverse effect, es-

pecially in the young. Radical treatment is therefore required in such cases.

Moderate nasal bleeding is characterized by discharge of larger amount of blood (dozens of millilitres), which, however, does not exceed 200 ml in adults. Measures should be taken in such cases to arrest bleeding rapidly and completely. If blood enters the pharynx and is swallowed, profuse haematemesis can occur with a fall of arterial pressure and tachycardia.

In profuse haemorrhage, the blood loss exceeds 200 ml a day. In severe cases one litre and more of blood can be lost. Such haemorrhage is a direct danger to the life of the patient.

Recurrent haemorrhages are often attended by psychic disorders. The patient needs repeated and immediate transfusion of fresh citrate blood, and radical measures directed at arrest of bleeding should be taken.

Treatment includes the arrest of nasal bleeding. Whenever necessary, the circulating blood volume should be replenished. Erythrocytes should be transfused. The protein, electrolyte, and acid-base balance of the body should be corrected.

Insignificant nasal bleeding can in most cases be easily arrested by putting for 15-20 minutes a sterile cotton ball soaked in a 3 per cent hydrogen peroxide solution into the anterior part of the involved side of the nose. The cotton in the nostril should be compressed by the finger against the nasal septum. The patient should be seated upright and ice (or a towel wetted in cold water) applied to the nose. If insignificant bleeding from the anterior parts of the nose recurs, the bleeding site should be infiltrated with a 1-2 per cent novocain solution or cauterized with strong trichloroacetic acid, silver nitrate, or chromic acid. Recurrent bleeding from the Kiesselbach area can be managed by separating the mucosa in the area between two incisions. If this measure fails, or if bleeding originates from deeper structures, anterior tamponade is required (Fig. 17). A 5 or 10 per cent cocaine or a 2 per cent dicaine solution can be used (2 or 3 times) for anaesthesia. Anterior tamponade of the nose is performed by means of a 60-70-cm long turunda, nasal forceps, haemostatic paste, or emulsion.

A turunda is prepared from a 4-cm wide and 1-1.5-m long strip of gauze or roller bandage. The edges of the strip should be turned inside and the strip folded in two by the long axis. The turunda is then rolled into a ball and sterilized. The sterile turunda is taken with two forceps and unrolled into a con-

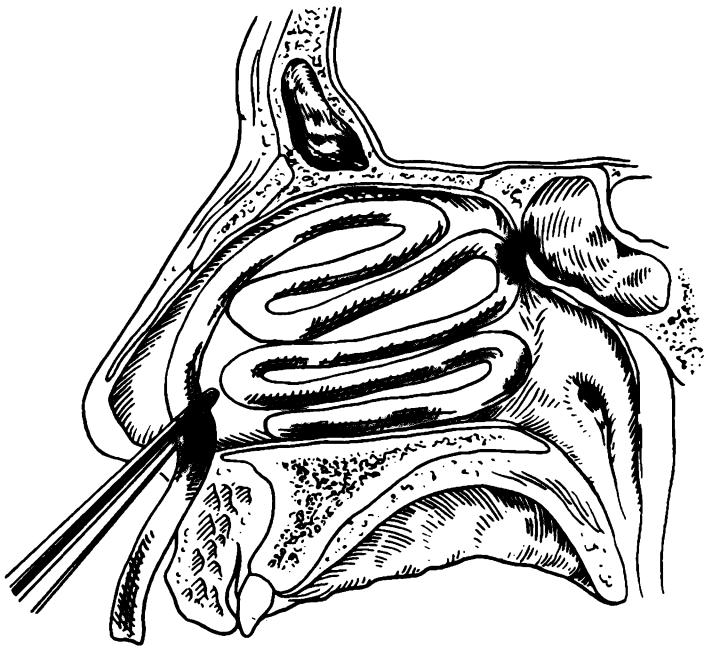

Figure 17
Anterior tamponade of the nose

tainer filled with a haemostatic solution. Turunda is then removed from the solution and excess liquid pressed out by the forceps.

The tamponade of the nose is performed by placing the turunda on the floor of the nasal cavity, from its vestibule to the choanae. The turunda is taken by the forceps at a distance of 6-7 cm from its end and is placed on the floor of the nasal cavity to the choanae. The forceps is then used to press the turunda to the floor of the nasal cavity. Then the next loop of the turunda is placed, and so on. The anterior pack should be removed in 24 hours after preliminary wetting it with a hydrogen peroxide solution. In cases of severe bleeding, the tampon should be left in place for 6-7 days, but it should be wetted each day with an antiseptic penicillin solution or aminocaproic acid, using a syringe and a needle.

A finger of a rubber glove is often used for anterior tamponade (instead of gauze). The glove finger should be stuffed with foam rubber. One or more such rubber fingers are inserted into the bleeding nasal cavity to ensure its tight filling. This tamponade is quite effective, the more so that it is more sparing than the tamponade with a gauze turunda. Inflatable balloon (with a breathing pipe passed inside) is also used for the purpose. Foam rubber encased in a rubber sheath can be used for anterior tamponade as well.

Profuse bleeding is characterized by a rapid loss of blood.

Immediate anterior tamponade is indicated in such cases. If nosebleed is profuse and does not stop, posterior tamponade is indicated. The blood group of the patient and his Rhesus factor should be established for immediate blood transfusion.

These measures prove ineffective in some cases. The external carotid artery should then be ligated not only on the involved but also on the opposite side. Destruction of cells of the ethmoidal labyrinth is an effective surgical method of arresting profuse nasal bleeding. In some cases, for example, in the presence of the Osler-Rendu syndrome, this operation should be done on both sides.

Posterior tamponade (Fig. 18) is done with special sterile tampons. Gauze is folded several times into 3 × 2.5 × 2 cm tampon which is then tied up crosswise with two 20-cm long silk threads. One end is cut off, while the other three ends remain. The posterior tamponade is begun with passing a thin rubber catheter into the bleeding side of the nose until its end enters the nasopharynx to appear in the middle of the pharynx. The end of the catheter is taken with a forceps and pulled outside through the mouth. Two threads of the tampon are tied up to this end of the rubber catheter and pulled back through the nose. The second finger of the right hand should be used to help to seat the tampon behind the soft palate in the nasopharynx and press it tightly to the corresponding choana. The next manoeuvre is to pull the two threads through the nose. The threads should be held strained while the nose is packed with the turunda and the thread ends are then tied tightly over a gauze pad at the nasal vestibule. The thread in the mouth will be used to withdraw the tampon. Its free end is fixed on the cheek with an adhesive tape.

Posterior tampon is removed in 24 hours. But if bleeding resumes, the tamponade should be repeated and the tampon remains for 3-4 and in some cases for 7-8 days. Antiseptic solution should be used to wet the tampon. It should be remembered that the drainage of the auditory tube is impaired in posterior tamponade and inflammation of the auditory tube and the middle ear can develop.

When the anterior and posterior tamponades are used in combination, it is necessary to see that the tampon closing the entrance to the nose should not compress too tightly the wing of the nose, otherwise necrosis can develop due to impaired blood supply. Antibacterial preparations should be administered in common doses

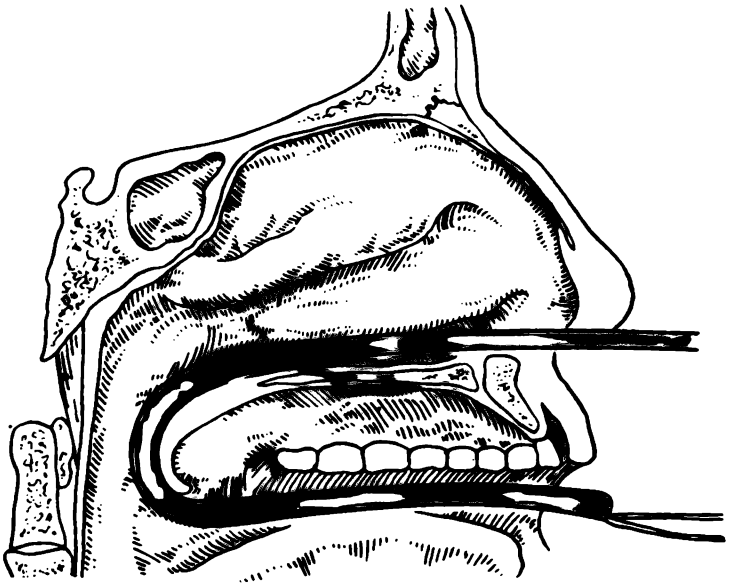

a

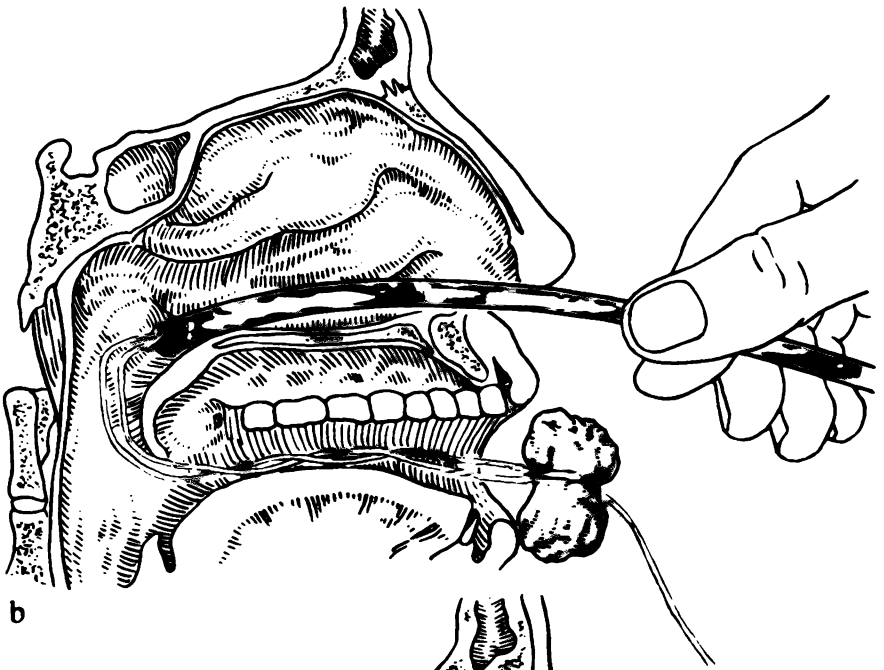

b

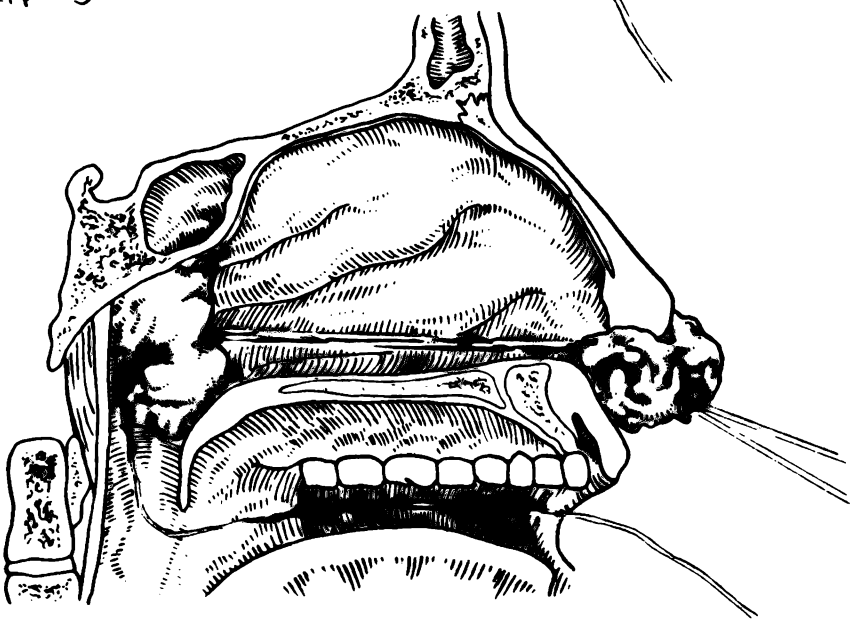

c

Figure 18
Posterior tamponade of the nose:

a – passing a catheter;
b – posterior packing;
c – fixing pack in place;
d – four-tailed bandage

immediately after tamponade is applied. Vitamins K (or vikasol), C and P, rutin, dicinon, solution of aminocaproic acid, and calcium gluconate should be given per os or injected to increase blood coagulation. A 10 per cent calcium chloride solution should be injected intravenously (3-5 per cent solution to children). Blood serum should be administered subcutaneously. Blood transfusion is a strong haemostatic means. It should also be conducted as a replacement therapy. In severe blood loss, isotonic sodium chloride solution should be infused subcutaneously: 1500 ml/day to adults and 300-500 ml/day to children. Oxygen therapy is indicated, because oxygen deficiency develops in the body after blood loss. Oxygen should be humidified and given to breathe for an hour 2-3 times a day (4-6 times a day in severe cases) through a rubber tube introduced into the mouth or nose from an oxygen bag or from a compressed oxygen cylinder.

If all these measures fail to arrest bleeding and the life of the patient is in danger, the vessels should be ligated. The external carotid artery is in most cases ligated on the involved side. But in some cases ligation of the maxillary artery or coagulation of the ethmoidal arteries is more effective.

If bleeding originates from a vascular tumour in the nose, it should be removed or coagulated. A bleeding malignant tumour should be removed with underlying healthy tissue, and with subsequent radio- and chemotherapy of the main disease. If bleeding originates from the paranasal sinuses, the source of haemorrhage should first of all be located. In order to arrest bleeding from

Figure 19
Abscess of the nasal septum

the sinuses, in addition to the described measures, the bleeding sinus can be cut open and a tamponade applied.

Patients with nasal bleeding require special attention and care. Their nutrition should be adequate with respect to caloric value. Food must be warm. The patient should be given much liquid to drink (natural juices). Patient's clothes and linen should be changed in due time. Children require special care and attention.

Haematoma and abscess of the nasal septum. Septal haematoma is usually due to the injury to the nose. Bleeding occurs between the cartilage or the bony part of the nasal septum on the one hand, and the perichondrium (periosteum) on the other. In rare cases haematoma can be formed in infectious and especially viral diseases. As a rule, the haematoma later suppurates and converts into an abscess of the nasal septum (Fig. 19). Pain in septal haematoma is either absent or is so insignificant that the patient does not attend the doctor at early terms following the affection. The danger of septal abscess is that it can extend onto the roof of the nasal cavity and cause intracranial complications. A septal abscess in children develops rapidly and often causes deformity of the external nose due to degeneration of the quadrilateral (septal) cartilage. Less frequently the condition can cause sepsis.

Diagnosis is established from the anamnestic findings and the

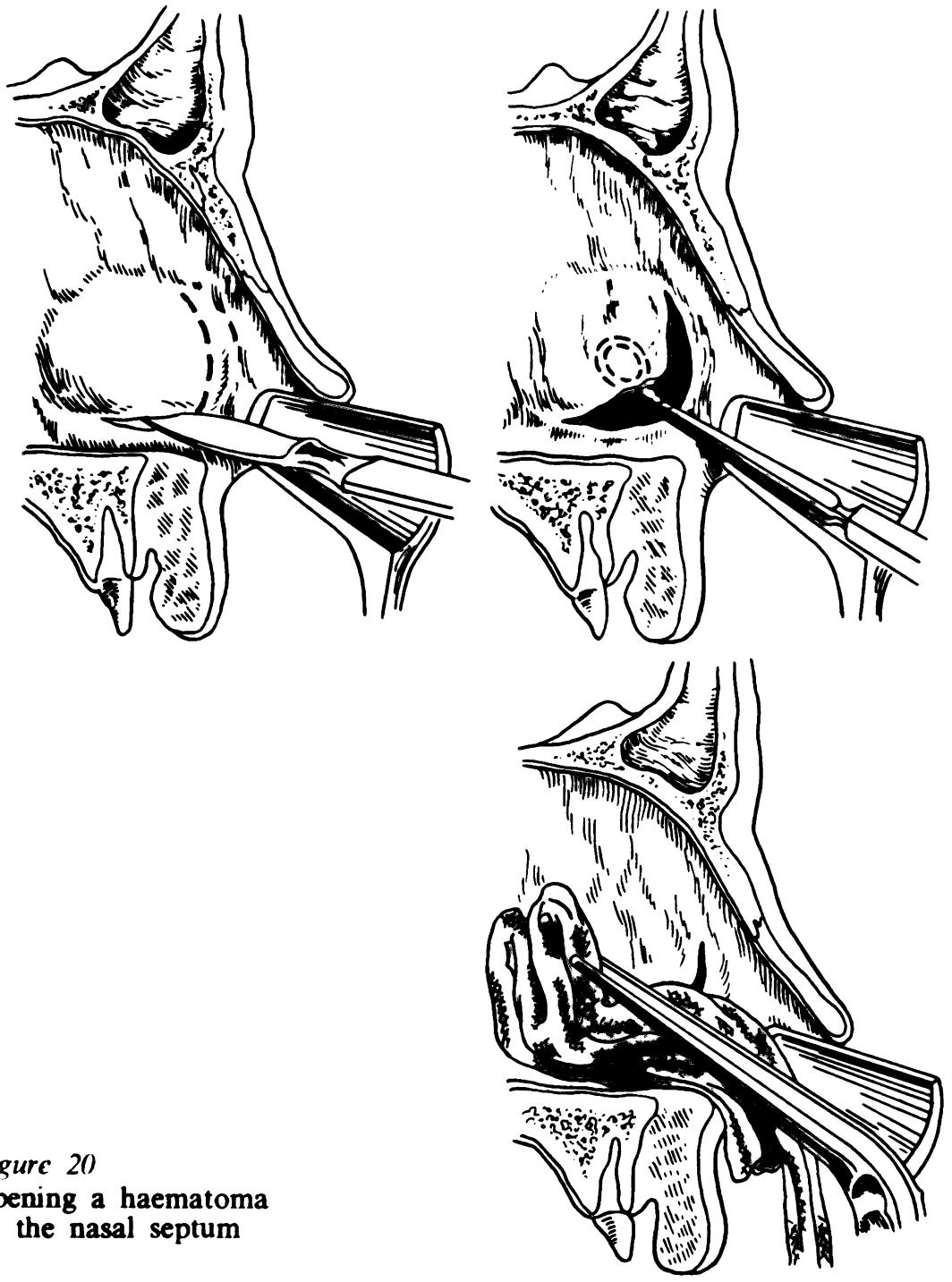

Figure 20
Opening a haematoma on the nasal septum

rhinoscopic picture. Probing and puncturing are used to confirm the diagnosis.

Treatment. Fresh haematoma (1-2 days) can be treated by its puncturing and suction of blood with subsequent anterior tamponade of the involved side of the nose. A septal abscess should be incised and drained (Fig. 20).

Perforation of the nasal septum usually occurs in its antero-inferior region, in the Kiesselbach area. A septal perforation can be subsequent to abscess of the nasal septum, its surgical correction, injury, atrophic process, tertiary syphilis, or tuberculosis.

Treatment is directed at elimination of harmful factors and therapy of the atrophic process. Plastic closure of the perforation is performed in some cases.

Disordered sensitivity to odour. Decreased sensitivity to odour (hypo-osmia) or complete loss of the sense of smell (anosmia) can be obstructive (respiratory) and essential, congenital and acquired. Hyperosmia (increased sensitiveness to odour) and perverted perception of odour (cacosmia) occur in rare cases.

The respiratory (obstructive) disorder is due to pathological changes in the nasal cavity which interfere with normal entrance of the inspired air containing odourous substances into the olfactory slit (hypo-osmia), or the air passageway is closed completely causing anosmia. Hypo-osmia and anosmia in adults and children are usually due to swollen mucosa of the conchae, atresia of the choanae, congenital abnormality of the nose, the presence of foreign bodies in the nose, deviated nasal septum, synechiae of the nasal cavity (of traumatic or other aetiology), polyps, tumours of the nose, and some other factors.

Essential anosmia is caused by the affection of the olfactory receptor or the olfactory nerve, by infectious diseases (e.g. influenza), children's infections, etc. Olfactory disorder can be irreversible due to the injury to the olfactory region of the nasal cavity or affection of the conduction routes. Anosmia can result from a tumour or an abscess in the anterior cranial fossa.

Diagnosis is established by testing the patient with strong-smelling substances (without special dosage) or, more accurately, using the instrument known as an olfactometer. The rhinoscopic picture is also very important for the diagnosis. The olfactory region should be examined thoroughly (its configuration and dimensions).

Treatment of the respiratory form of olfactory disorder is usually surgical. It is aimed at restoring nasal breathing and ensuring unobstructed passage of air through the olfactory slit to the olfactory region. Most common operations are polypotomy of the nose, submucous resection of the nasal septum, partial conchotomy, and some others. The essential form of olfactory disorder should be treated by eliminating the causative factor, e.g. atrophy of the nasal mucosa, and by increasing olfactory sensitivity using biological stimulants such as, for example, aloe,

vitreous body, vitamins B and C, and also strychnine or arsenic preparations.

Allergic and **neurovegetative forms of rhinitis** are distinguished.

The aetiology of the allergic form depends basically on the allergen, i.e. the substance to which the patient has increased sensitivity. The effect of the allergen on the mucosa of the upper airways and absorption of the allergen immediately cause an attack of allergic rhinitis.

Allergic rhinitis can be seasonal or permanent (non-seasonal). Seasonal rhinitis is usually provoked by pollen of the blossoming trees and grass, and for this reason it is often called hay fever. Seasonal allergic rhinitis recurs regularly at the same time of the year, when the specific plant (or several plants) is in blossom.

Permanent (non-seasonal) rhinitis is caused by many various substances (allergens) with which the patient often comes in contact, e.g. house dust, fur of domestic animals, pillow feathers, book dust, some foods, various microflora (usually streptococci and staphylococci). Not infrequently, sensitization to several allergens arises simultaneously (pollinosis). This imposes additional difficulties in the diagnosis and treatment of this form of rhinitis.

Neurovegetative rhinitis occurs due to disordered nervous mechanisms accounting for the normal physiology of the nose; as a result, otherwise harmless stimuli provoke hyperergic reaction of the nasal mucosa.

The main symptom of both forms of rhinitis is paroxysmal sneezing attended by nasal hydrorrhoea and difficult nasal breathing. This triad of symptoms is more or less pronounced in all cases. The rhinoscopic signs of rhinitis are oedema and pallor of the mucosa, and cyanotic or white spots on it.

The allergic form of the disease is characterized by increased eosinophil counts (more than 5-6 in the field of vision) and appearance of eosinophils in the nasal mucus. The vividness of these symptoms varies.

Treatment depends on the findings of the allergological examination and includes elimination from the patient's environment of wool (carpets), domestic animals, book dust, certain foods, etc. Purulent foci or microbial allergy should also be eliminated. Treatment is, as a rule, complex. It includes specific and non-specific hyposensitization of the patient and local procedures, including surgery and action on the nervous system.

Specific hyposensitization is conducted in conditions of an allergological laboratory because severe allergic reactions are possible

following administration of the allergens. The identified allergen should be highly diluted and administered to the patient in gradually increasing microdoses (subcutaneously or into the nose, on the mucosa, regularly during the course of several weeks). The body can thus produce protective antibodies to the allergen.

Non-specific desensitization is used in both allergic and neurovegetative forms of rhinitis. Antihistaminics (diphenhydramine, diprazine, diazolyl) and hormones (hydrocortisone, prednisolone, prednisone, etc.) are used for the purpose.

Preparations of calcium, sulphur, and vitamins are also helpful. But it should be remembered that practically any preparation can act as an allergen, especially if it is administered for a long time. Local methods of treatment, including endonasal novocain block, intramucous administration of corticosteroids, cauterization of the reflexogenic zones of the nasal mucosa with strong acids, silver nitrate, intranasal physiotherapy, sclerotherapy, and also intranasal administration of some preparations are used for treatment of both forms of rhinitis. Local use of vasoconstrictive drops for these forms of rhinitis has an adverse effect on the course of the disease.

Electrophoresis of various medicinal solutions is the most common method of physiotherapy for rhinitis. Endonasal electrophoresis with a 2 per cent calcium chloride solution is used most frequently. A 1 per cent diphenhydramine (diphenylhydramine hydrochloride) can be added to the calcium chloride solution (1:1).

Endonasal phonophoresis of hydrocortisone is an effective therapeutic means. An ultrasound generator is used for the purpose.

Long-standing vasomotor rhinitis often increases the volume of the conchae and imposes permanent difficulties in nasal breathing. Surgical treatment (sparing inferior conchotomy, submucous destruction of the inferior conchae with ultrasound) is most rational in such cases.

Acute catarrhal rhinitis (common cold) is an acute non-specific inflammation of the nasal mucosa. This rhinitis is a common disease of adults and children.

The aetiology of acute rhinitis is determined by decreased local or general reactivity of the body and activation of microflora of the nose. The disease usually occurs following general or local chilling that interferes with the protective nervous and reflex mechanisms.

The clinic of acute catarrhal rhinitis includes three stages, which are continuous with one another: the first stage is dry irritation, the second stage is characterized by increased mucous secretion, and the third stage (resolution) is characterized by mucopurulent secretion. Acute rhinitis begins with the feeling of dryness, tension, burning, and itching in the nose and often in the pharynx and the larynx; sneezing is annoying. The patient complains of indisposition, chill, discomfort and headache (mostly pain in the forehead). The body temperature is elevated. Nasal respiration becomes difficult - from insignificant impediment to a complete obstruction due to obturation of the nasal meatuses with swollen mucosa. Olfaction is impaired significantly (respiratory hypo-osmia). The sense of taste is also altered. The speech becomes nasal (rhinolalia clausa). Profuse watery discharge from the nose is characteristic of the first day of acute rhinitis. The amount of mucus in the discharge increases later. The mucus contains sodium chloride and ammonia which accounts for the irritating effect on the skin and the mucosa, especially in children. This can cause hyperaemia and swelling of the skin at the nose vestibule and of the upper lip. The nasal discharge becomes seropurulent in 4 or 5 days. The discharge is first grey, then it turns yellowish due to the presence of the formed elements of blood (leucocytes, lymphocytes) desquamated epithelium, and mucin. The amount of nasal discharge decreases gradually during the next few days, swelling of the mucosa subsides, respiration through the nose and olfaction are restored, and the patient recovers in 8-14 days from the onset of acute catarrhal rhinitis.

If the immunobiological condition of the patient is good, the course of acute catarrhal rhinitis is abortive and ends in 2-3 days. If the patient's immunobiological protective mechanisms are weak, the disease can last for 3-4 weeks. In such cases it tends to convert into the chronic form of rhinitis.

The inflammatory process in infants can extend onto the pharynx. In this case the disease is called acute rhinopharyngitis. The inflammation often extends to the larynx, trachea, or bronchi, i.e. the disease acquires the character of acute respiratory infection.

Acute rhinopharyngitis in children is often complicated with acute otitis media due to inflammation spread from the nasopharynx to the auditory tube, and also due to the special anatomy of the child's auditory tube, which is short and wide.

Diagnosis is established on the basis of the mentioned symptoms, but in each particular case it is necessary to differentiate the disease from acute specific rhinitis which is a symptom of an infectious disease, such as influenza, diphtheria, measles, whooping-cough, scarlet fever, and gonorrhoea, syphilis, etc.

Treatment as a rule is given on out-patient basis. If rhinitis is severe and is attended with high temperature, the patient is recommended bed rest at home.

The course of acute rhinitis can be aborted by thermal, counter-attractive, and sudorific procedures. Hot bath is recommended for the feet and the lumbar region; hot tea, 0.5 g of acetylsalicylic acid is also recommended with subsequent bed rest and packing in a blanket. UV-therapy, application of mustard plasters to the calves, UHF, or diathermia are also useful; they are usually effective during the first days of the disease.

Therapy of children with rhinitis has some special features. Before nursing an infant, it is necessary to suck off mucus from each side of the nose using a rubber syringe. Crusts in the vestibule, if any, should first be softened with vegetable or mineral oil, and removed using cotton balls. Two drops of a vasoconstrictive substance, e.g. adrenaline (1:5000 or 1:10000), and two drops of a 2 per cent boric acid should be instilled into each nostril 5 minutes before breast-feeding. Four drops of a 2 per cent colloid silver (or protein silver) solution should be instilled into each nostril four times daily in the intervals between nursing. A 1 per cent ephedrine solution and some other preparations have an adequate vasoconstrictive effect. **Cocaine and menthol solutions should not be given to children under 10 years of age because of the toxic effect of the former and the irritating properties of the latter.** Adults should be given adrenaline, ephedrine, galasoline, or otrivin, and sanorine at all stages of acute catarrhal rhinitis. Galasoline (otrivin) has a prolonged effect: the vasoconstrictive effect of 3 drops administered into each nostril lasts for about 4 hours. The drops should be given 3 times a day.

A mixture of several sulpha drugs with an antibiotic that does not produce an allergic effect on a given patient should be insufflated to patients with pronounced inflammatory and microbial reaction. It should be remembered that administration of drops, either aqueous or oily, insufflation of powders, or inhalation of medicinal substances should not continue longer than for 8-10

days (for 2 weeks in rare cases). A longer use of nasal preparations can cause various pathological conditions, for example, allergy.

Patients with acute rhinitis can in some cases be considered temporarily disabled (depending on the general condition and severity of symptoms). This, in the first instance, concerns persons working in public catering establishments, and those who are lecturing, singing or engaged in other activities that may worsen the patient's condition.

Hardening the body to cold or heat, and to dry or moist air is an effective prophylactic measure.

Acute rhinitis in children with infectious diseases. *Nasal diphtheria* is a general infectious disease caused by the Loeffler bacillus. It is attended with local diphtheritic inflammation of the nasal mucosa, nasopharynx, oropharynx, and the larynx, as well as of the eyes, sexual organs and skin. Diphtheria is a rare disease.

The onset of the disease is characterized by general weakness, flaccidity, indisposition, elevated (subfebrile) temperature; fever is possible. The diphtheritic affection of the nose has two forms: membranous and catarrhal (catarrhal-ulcerative).

The membranous form is characterized clinically by dryness in the nose, impeded respiration through the nose, copious nasal discharge (mostly from one side of the nose), and formation of membranes mainly in the anterior parts of the nose. The membranes are firmly adherent to the underlying tissues (the mucosa) and their forcible removal (also separation during sneezing or blowing out the nose) causes bleeding. The regional lymph nodes are usually enlarged and tender to palpation.

The catarrhal form does not involve formation of the membranes and this is a frequent cause of incorrect diagnosis. The clinical signs of the disease are similar to those of acute catarrhal rhinitis. The differential signs of nasal diphtheria are sanguinous discharge, protracted course, and growth of the diphtheria bacillus in the smears taken from the nasal mucosa.

Nasal diphtheria in infants runs a severe course. The disease is associated with fever which can subside and then develop again. In the absence of specific treatment, the disease spreads onto the pharynx and the larynx and can become fatal.

Carriers of diphtheria bacillus, in whom the clinical signs of nasal diphtheria are absent while nasal cultures contain the Loeffler bacilli, are very dangerous for children. True, the carrier himself can develop diphtheria subsequent to an adverse effects impairing

the body resistance. The administration of antidiphtheritic preparations has no effect on the bacilli and treatment of their carriers is difficult. Natural immunological protective mechanisms should in such cases be strengthened by improving the patient's general condition. Local antibacterial treatment is also helpful.

Treatment. Nasal diphtheria should be treated by immediate administration of diphtheria antitoxin. The patient should immediately be taken to an infectious department and a corresponding report should be sent to the epidemiological centre. The apartments of the patient should be disinfected. All contacts should be taken under control.

The membranous form of nasal diphtheria should also be treated by nasal inhalations of a 2 per cent sodium hydrocarbonate solution (3-4 times a day). Boric acid (a 2 per cent solution) containing adrenaline should be used for spraying over the focus of infection. A 2 per cent silver protein solution should be instilled into the nose. The skin of the vestibule and the upper lip should be treated with a neutral oil (ointment). If the membranes are formed in the nasopharynx, the above mentioned preparations should be instilled into the nose.

Influenza and other viral diseases, in addition to the general acute symptoms, are manifested by acute catarrhal rhinitis which runs its specific course. The special feature of influenzal rhinitis is the sanguinous character of nasal discharge. Conjunctivitis and otitis media are frequent complications. The nasal mucosa of a patient with influenzal rhinitis can have haemorrhages.

Scarlet fever is an infectious disease with involvement of the nasal cavity and the pharynx. The disease is relatively rare.

The course of rhinitis in scarlet fever can run a moderately severe and severe course. It is characterized by copious nasal discharge, severe hyperaemia of the nasal mucosa, sometimes with superficial necrosis of epithelium and fibronecrotic deposits.

The diagnosis of scarlet fever is based on the combination of the specific symptoms (tonsillitis, skin eruption, toxaemia) and the rhinoscopic findings. The main disease and acute rhinitis should be treated in an infectious department.

Whooping-cough is a relatively rare viral disease; it occurs mostly in small children. Acute rhinitis associated with whooping-cough runs a moderately severe course. Among the specific signs are haemorrhages into the hyperaemic mucosa and conjunctiva; nasal bleeding can also occur. The main disease should be treated; acute rhinitis itself should also be treated.

Rhinitis is a prodromal symptom of *measles*. It occurs 2-3 days before rash appears on the skin. Rhinitis develops simultaneously with enanthema of the mucosa of the soft and hard palate and subsides when the measles rash turns pale. Rhinitis often develops together with inflammation of the airways (laryngotracheobronchitis) and of the conjunctiva; the paranasal sinuses are often involved. Rhinitis in measles should be treated as common acute catarrhal rhinitis.

Chronic rhinitis. The main forms of chronic rhinitis are catarrhal, hypertrophic and atrophic. The disease is common.

The onset of chronic rhinitis is connected as a rule with frequently recurring acute inflammation in the nasal cavity (including inflammations associated with various infections), irritating environmental effects such as dust, gas, dry or moist air, variations in ambient temperature, etc. In some cases, chronic rhinitis is a symptom of other diseases, e. g. chronic purulent sinusitis (frontal sinusitis, maxillary sinusitis, ethmoiditis), a foreign body in the nose, and the like, which should be taken into account when establishing the diagnosis and treating the patient.

Chronic catarrhal rhinitis. The main symptoms of chronic catarrhal rhinitis are impeded respiration through the nose and rhinorrhoea; both signs are manifested moderately. Respiration through the nose becomes periodically difficult, mostly due to chilling. The passageway through one side of the nose is usually obstructed permanently. Nasal respiration is even more difficult when the patient lies on his side: the impediment is more pronounced on the lower side, which is explained by the filling of the cavernous vessels with blood in the dependent conchae whose tone decreases in chronic rhinitis. The nasal discharge is mucous and its amount is not significant. When the process is exacerbated, the discharge becomes purulent and copious.

Decreased sense of smell (hypo-osmia) is usually transient and is due to increased amounts of mucus; anosmia (loss of the sense of smell) is rare.

Chronic hypertrophic rhinitis. The main signs of hypertrophic rhinitis are impeded respiration through the nose, copious mucous and mucopurulent nasal discharge, and thickened and swollen nasal mucosa, mainly in the entire inferior concha and to a smaller degree in the middle concha, i. e. in the areas where the cavernous tissue is found. The mucosa is usually hyperaemic (scarlet, red-blue, greyish-blue) and covered with mucus. In the presence of mucopurulent discharge, inflammation of the paranasal sinuses

should be excluded. The posterior ends of the inferior conchae are usually thickened; sometimes they compress the pharyngeal orifices of the auditory tubes, causing salpingo-otitis.

Decreased olfaction is first manifested by respiratory hypo-osmia or anosmia but later, in connection with atrophy of the olfactory cells, essential (irreversible) anosmia develops. The sense of taste slightly decreases too. The nasal obstruction changes the voice (rhinolalia clausa).

In some patients hypertrophic rhinitis is attended by polypous degeneration of the mucosa, mostly in the middle and superior meatuses. Congestive oedema in the posterior parts of the inferior nasal conchae can also occur. Allergic sensitization of the body provokes formation of polyps and oedema.

Chronic atrophic rhinitis. Common chronic atrophic rhinitis can be diffuse or circumscribed; the degree of affection can also vary. Slight atrophy of mucosa, mainly of the respiratory part of the nose, frequently occurs. This affection is commonly called subatrophic rhinitis.

The onset of atrophic affection in the nose is commonly associated with prolonged exposure to dust, gas, vapours, etc. Mineral dust (silicates, cement) and that of tobacco produce a strong effect on the condition of the nose.

Atrophic changes in the nose of children can be caused by infectious diseases such as measles, influenza, diphtheria, or scarlet fever; constitutional predisposition is also important.

Common symptoms of the disease are crusts in the nose. Meagre tenacious mucus (or mucopurulent discharge) adheres to the mucosa and dries into crusts. The patient complains of dryness in the nose and the pharynx, and impairment of olfaction. Separation of the crusts often causes nosebleed, usually from the Kiesselbach area.

Treatment of chronic rhinitis. Treatment of various forms of chronic rhinitis includes the following: (1) elimination of possible endo- and exogenic factors which cause and maintain rhinitis; (2) specific medicamentous therapy of each particular form of rhinitis; (3) surgical management for special indications; (4) physiotherapy and climatic treatment.

Astringent substances are used for chronic catarrhal rhinitis. These are a 3-5 per cent protein silver or colloid silver solution (5 drops into each nostril, 3 times a day; a cotton ball can be soaked in the solution and wound round a probe for application to the mucosa) and a 3-5 per cent silver nitrate solution.

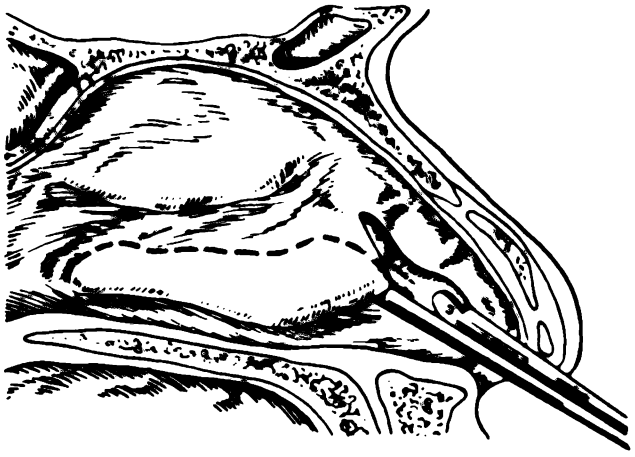

Figure 21
Resection of the inferior concha

If the mucosa is swollen, it can be treated with an iodine-glycerol solution. The treatment with the mentioned preparations should not continue for more than 10 days. Physiotherapy is also recommended: UHF or microwaves on the nose and UV-therapy endonasally (through a cone). Courses of instillation of peloidin, inhalations of balms (Shostakowsky's balm diluted 1:5 with vegetable oil, or eucalyptus balm) should be alternated. Patients with chronic catarrhal rhinitis can be recommended to reside in dry warm climate. If hypertrophy is insignificant, sparing surgical interventions are recommended: cauterization with chemical substances (silver nitrate, trichloroacetic acid, chromic acid), electric current, or extreme cold. If hypertrophy is significant and respiration through the nose is impeded, partial resection of the hypertrophied parts of the conchae (conchotomy) is recommended (Fig. 21).

Treatment of atrophic rhinitis. This is mainly symptomatic. The patient should take care of his nose so that crusts and nasal discharge should not accumulate in the nasal cavity. The nose should be cleaned once or twice a day by irrigating the nasal cavity with isotonic sodium chloride solution containing an additive of iodine (6-8 drops of a 5 per cent iodine tincture per 200 ml of the solution). Irritants should periodically be used: the mucosa should be treated with an iodine-glycerol solution once a day in the course of 10 days, this stimulates the secretion of the glands in the nasal mucosa. A 30 per cent potassium iodide solution (8 drops 3 times a day, for 2-3 weeks) should be given per os for the same purpose.

Ozaena is a pronounced atrophy of the nasal mucosa and the nasal bones marked by formation of fetid crusts which produce a firm layer on the nasal mucosa. Metaplasia of the columnar

ciliated epithelium into squamous epithelium associated with ozaena is characteristic for the major part of the nasal mucosa.

Ozaena is rare in the Soviet Union. It mainly occurs in women and begins in the young. Social and occupational factors are important for the aetiology of the disease, but still its cause is unknown. The disease persists during the whole life. It is exacerbated during menstruation. The symptoms of the disease subside significantly during pregnancy and lactation and in old age.

Ozaena patients complain of marked dryness in the nose, intensive crusting, and fetor. The respiration through the nose is impeded. Olfaction is either strongly impaired or lost completely.

Diagnosis is established by the fetid odour from the nose, the presence of many crusts and atrophy of the nasal mucosa and bony walls of the nose. Ozaena often concurs with pronounced atrophic pharyngitis and laryngitis, and sometimes atrophic tracheitis.

Treatment is mainly symptomatic. It is aimed at eliminating the grave symptoms of ozaena: crusts and fetor. In order to remove the crusts and prevent their accumulation, the nasal cavity should be irrigated daily with various solutions, which should be alternated at 2-3-week intervals. An isotonic sodium chloride solution or a 1 per cent sodium chloride solution containing iodine tincture, or a solution containing 10 ml of salicylic acid, 20 g of sodium chloride, and 20 g of sodium hydrocarbonate (1/2 teaspoonful per cup of water) should be used for irrigation. In the presence of many crusts and fetid odour, a streptomycin solution should be sprayed into the nose for several days. Crusts can be softened using a neutral oil.

After irrigation of the nose, the softened crusts should be removed completely, and the clean mucosa should be powdered slightly with a mixture of menthol (0.3 g) and boric acid (10 g). If improvement is pronounced, sodium chloride solution alone can be used for spraying.

Along with the local treatment, vitamins and biological stimulants (aloe) are also recommended. Surgical treatment includes mostly narrowing of the nasal passages but, like protein therapy, this method is not widely used for ozaena.

PREPARING A PATIENT FOR NASAL CAVITY SURGERY

On the eve of the operation the patient should take a hygienic bath (men should shave, since hair interferes with normal treatment of the skin and can thus cause slow healing of the operative wound). Disinfection of the field for operations on the nose and the paranasal sinuses differs from disinfection in general surgery. The nasal cavity should be cleaned of mucus or pathological matter using cotton wool wound around an applicator. The nasal meatuses should be freed from pathological matter carefully as not to damage the nasal mucosa. This manipulation should be carried out under direct visual control. The face skin should be treated two times using a 76 per cent alcohol (not a 5 per cent iodine tincture).

Some operations on patients with diseases of the nose, ear, and throat can be carried out under out-patient conditions. Among these operations are submucous resection of the nasal septum, conchotomy, polypotomy, opening of the cells of the ethmoidal labyrinth, endonasal opening of the maxillary sinus, trephinopuncture of the frontal sinus, and biopsy. These operations can be performed under local infiltration (0.5-1 per cent novocain solution) or permeation anaesthesia (1-3 per cent dicaine or xylocaine solution containing drops of adrenaline hydrochloride solution diluted 1:1000, or 5-10 per cent cocaine solution).

Operations under out-patient conditions should be performed on patients younger than 55, because complications on the part of other organs and systems are possible during operations and may require intensive therapy. Out-patient surgical operations are permitted on the condition that the following data are available: total blood count, blood test for the haemorrhagic syndrome (coagulability, coagulation time, platelet count); clinical urinalysis; X-ray examination of the chest, nose and the paranasal sinuses (in one or several projections, depending on the character of pathology); Wassermann's test, and the test for blood group and the Rh factor; conclusion of the internist on the absence of contraindications for operation, conclusion of a stomatologist; ECG should be taken before operation on patients aged over 40.

The hygienic requirements for the out-patient operations are the same as for operations in the hospital.

The nurse is responsible for timely sterilization of tools and dressing material, and for sterility of anaesthetics; she must check

the date of expiration of the anaesthetics to be used during operation, and show this date to the surgeon.

The requirements for the pre-operative treatment under hospital conditions are the same.

DISEASES OF THE PARANASAL SINUSES

ALLERGIC DISEASES

As a rule, allergic sinusopathy attends allergic rhinitis and concurs with some other aetiologically dependent diseases (nettle rash, bronchial asthma, eczema). Secondary infection of the mucosa is possible in allergic sinusitis. In this case the disease becomes purulent.

The disease is characterized by attacks which can occur unexpectedly. The attack is marked by permanent sneezing, itching in the nose, difficult respiration through the nose, and copious watery discharge. At the end of the attack the patient complains of discomfort in the head and noise in the ears.

Long-standing allergic rhinosinusopathy often causes polypous degeneration of the mucosa. Rhinoscopy in such cases reveals polyps of variable size growing from the middle nasal meatus (Plates I and II; Fig. 22).

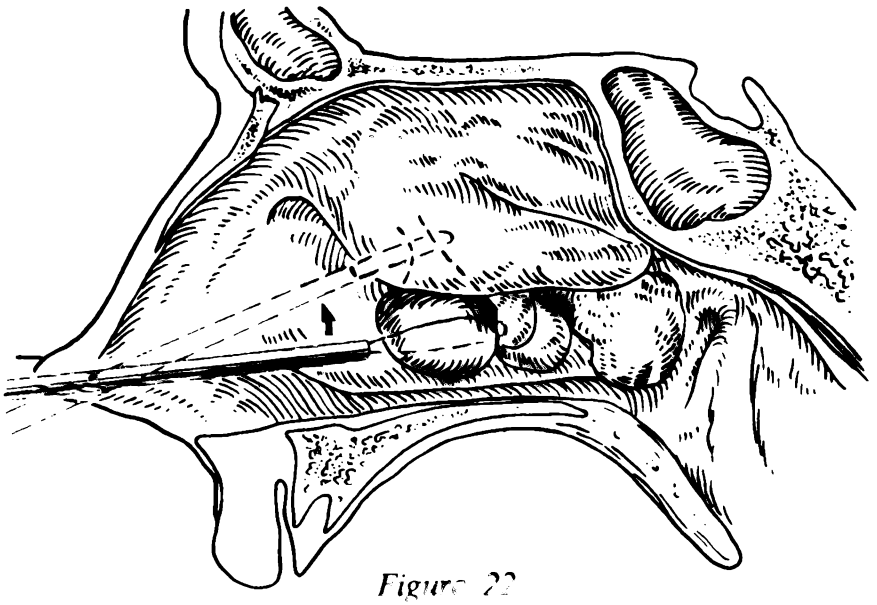

Figure 22
Polypotomy

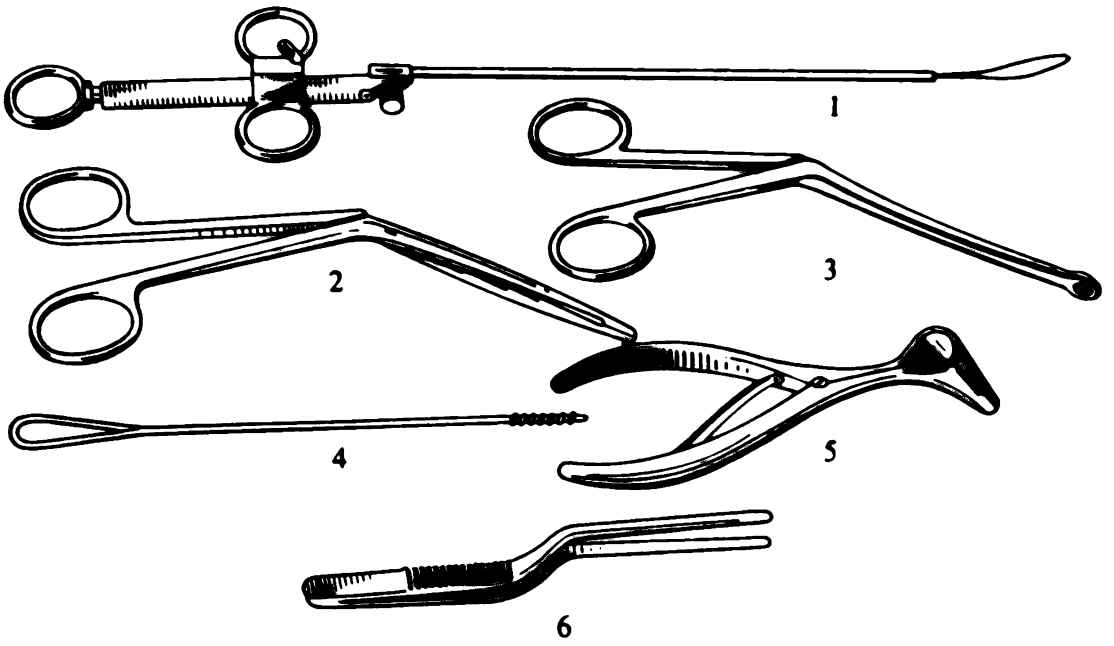

Figure 23

Set of instruments for polypotomy:

1–snare; *2*–nasal dressing forceps; *3*–nasal fenestrated forceps; *4*–nasal probe; *5*–Killian's speculum; *6*–bayonet forceps

X-ray picture of the paranasal sinuses of the patient with allergic sinusopathy reveals moderate homogeneous opacity of the maxillary sinus and the cells of the ethmoidal labyrinth (usually on one side). Unlike in purulent sinusitis, another X-ray picture taken a day later can give quite a different result: the sinus that was opaque is now clear, and vice versa, i.e. the pathology can be seen in the other side of the nose.

The final *diagnosis* can be confirmed by special laboratory tests, e.g. scarification and intracutaneous tests with allergens, counting eosinophils in the blood, in the nasal discharge, and in the maxillary contents.

Treatment of allergic rhinosinusopathy includes removal of factors that exacerbate the disease (domestic animals, certain foods, medicines, etc.) and administration of desensitizing preparations. Desensitization can be specific, if the patient is treated with small doses of the allergen that was discovered during sensitivity tests. Desensitization can also be non-specific. In this case antihistaminics should be administered: diazolin (0.05-0.2 g, 1-2 times a day), suprastin or pipolphen (0.025 g 3 times a day). Hydrocortisone suspensions (25 mg of the preparation diluted in

4 ml of isotonic sodium chloride solution) are sometimes effective when administered into the sinus.

Surgical operations should be performed for special indications only (Fig. 23).

INFLAMMATORY DISEASES

Acute and chronic inflammatory diseases of the paranasal sinuses are frequent. They make 25-30 per cent of the hospitalized patients with diseases of the ear, nose and throat.

Maxillary sinusitis stands the first in the list of incidence. Next comes ethmoiditis, then frontitis and finally sphenoiditis. More than one sinus can be involved (polysinusitis). Sometimes all paranasal sinuses are affected (pansinusitis) or the sinuses of one side (hemisinusitis).

Acute inflammation of the sinuses is caused by acute respiratory diseases, influenza, common cold, general microbial infections, and injuries. Acute rhinitis is usually associated with acute inflammation of the paranasal sinuses.

Chronic sinusitis can be secondary to protracted or frequently recurring acute diseases in the presence of various local and general harmful factors such as decreased reactivity and general weakening of the body, impaired drainage of the sinuses in the presence of hypertrophy or polyps of the mucosa in the region of the orifices, deviated septum, and diseases of the teeth.

The suppurative forms of the disease are usually caused by streptococci and staphylococci, in some cases by pneumococci, pseudodiphtheritic bacillus, or other micro-organisms. Microbes are normally absent from healthy sinuses.

Acute maxillary sinusitis. Signs of acute inflammation of the maxillary sinuses can be local and / or general. The local symptoms are pain in the region of the involved sinus, forehead, root of the nose, and the cheek bone. Pain can differ in severity; it can intensify during palpation and radiate into the temple or the entire half of the face. Headache can be diffuse. Impeded respiration through the involved side of the nose is a common symptom. In rare cases nasal respiration is difficult on both sides due to swelling of the nasal mucosa and contraction of the nasal passages. Nasal discharge is usually unilateral, and is first liquid, serous, but then it becomes cloudy, tenacious, and purulent. Olfaction is affected as a rule, but the severity of other symptoms masks this disorder.

The general symptoms are elevated (to subfebrile) temperature of the body, indisposition, which becomes even more pronounced if nasal respiration is impeded on both sides and the patient has to breathe through the mouth. The temperature reaction can begin with a chill and be intensive during the entire disease; in other cases the temperature is elevated only during the first days of the disease, or it can even remain normal.

The objective symptom of acute maxillary sinusitis is a narrow strip of purulent discharge from the maxillary sinus into the middle nasal meatus, which is especially evident if the head is inclined to the opposite side.

Some additional examinations should be carried out: X-ray examination of the paranasal sinuses, diagnostic antral puncture and irrigation of the maxillary sinus; contrast X-ray and echography, and some other techniques can also be used.

The Kulikovsky needle is commonly used for antral puncture, but other needles can also be used, e.g. a needle commonly used for spinal puncture. The sinus wall is punctured by the needle and the sinus contents are aspirated; then, the sinus is irrigated with a disinfectant solution, e.g. furacin, or peloidin, using a 100-ml syringe. The liquid is passed into the sinus through the needle, while the sinus is drained through the natural orifice. The patient leans foreward (downward) so that the washings are withdrawn through the nose without entering the nasopharynx (Figs 24, 25, and 26).

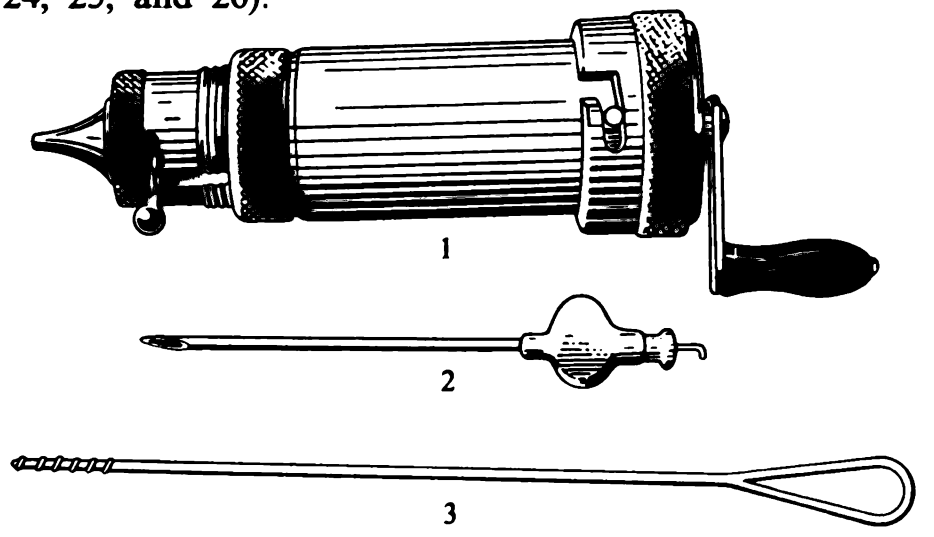

Figure 24

Tools for puncturing sinuses:

1 – trephine for puncturing the frontal sinus;
2 – Kulikovsky's needle for puncturing the maxillary sinus;
3 – probe for anaesthesia of the nasal cavity

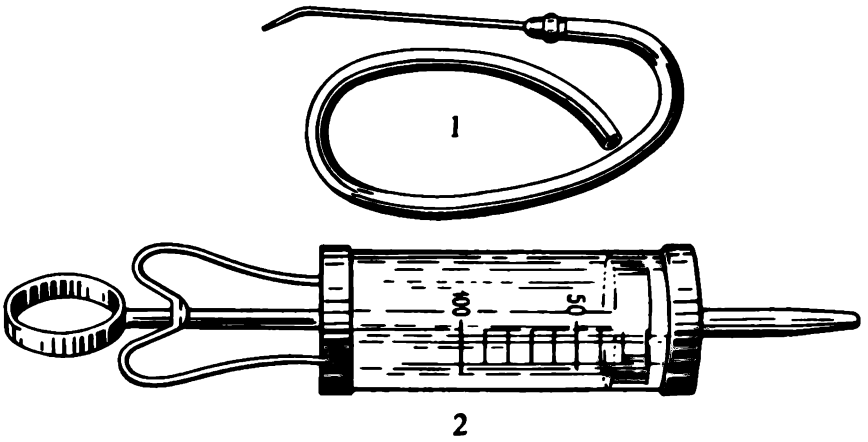

Figure 25
Tools for irrigation of the maxillary sinus:
1–metal catheter with a rubber tube; *2*–Janet's syringe

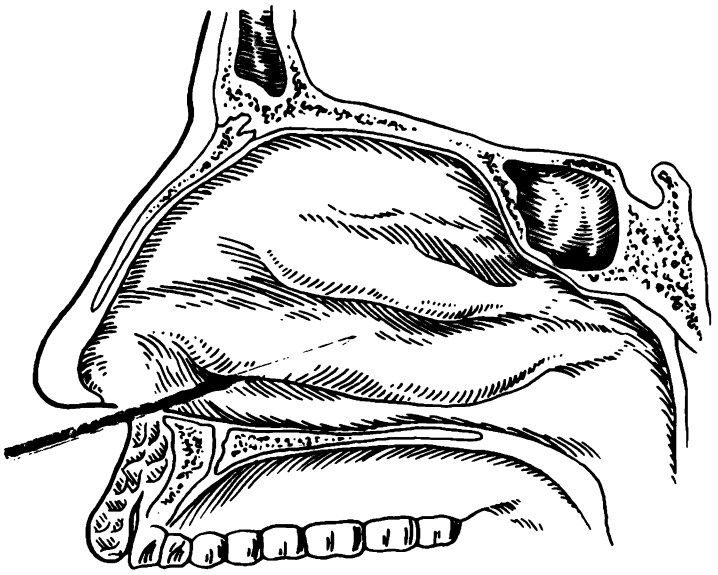

Figure 26
Puncturing the maxillary sinus through the inferior nasal meatus

The presence of pathological contents in the sinus is a direct indication of the specific pathology; the absence of pathological matter in the washings does not exclude completely the disease of the sinus. A radiopaque substance (iodolipol) should then be injected into the sinus and an X-ray picture taken in two projections.

Air embolism of the cerebral or heart vessels is a severe complication of antral puncture. This can be prevented by strictly adhering to the corresponding rules; for example, before irrigating the sinus, the rubber tube leading from the syringe to the needle should be filled with the cleansing fluid; it is prohibited to blow air into the sinus after its irrigation.

Treatment includes local use of vasoconstrictors, physiotherapy, and general antibacterial therapy in the presence of high temperature and intoxication of the body.

If these measures fail to give the rapid effect, the sinus should be punctured and irrigated in 1 or 2 days and a mixture of penicillin (300 000 U) and streptomycin (250 000 U) should be injected. Antral puncture is not recommended for children, and especially for infants, because their sinuses are small, and also because acute osteomyelitis and venous thrombosis can develop.

Various vasoconstrictors are instilled into the nose, e. g. otrivin, less frequently 1-3 per cent ephedrine solution. Five drops of the preparation are instilled into each side of the nose 3 times a day.

The acute suppurative inflammation ends in 5-6 days. UHF-therapy of the maxillary sinuses should then be carried out daily (a total of 12 sessions). UV-therapy should be used locally and generally.

Local and general complications, e. g. abscess (phlegmon) of the orbit, intracranial abscess, meningitis, or sepsis, are indications for emergency surgery.

Chronic maxillary sinusitis. Suppurative, suppurative-polypous, and polypous forms of chronic maxillary sinusitis are common. Less frequently occur the catarrhal, serous, vasomotor, allergic and parietohyperplastic forms; still less frequently occur cholesteatomatous, caseous, necrotic, and ozaenous forms of the disease. Chronic inflammation of the sinus is as a rule a sequel of acute sinusitis, which is recurrent in some patients. Acute inflammation persisting for more than 3 weeks should be considered as long-standing. If such inflammation does not terminate by the end of the 6th week, the disease can be considered chronic.

Sometimes chronic maxillary sinusitis is associated with spreading of pathology from a caries-affected tooth.

A common symptom and complaint of patients with the exudative forms of chronic maxillary sinusitis is discharge from one side of the nose, which can be copious during exacerbation and scarce in remission. The purulent discharge in patients with maxillary sinusitis can be thick or liquid and have a specific odour. The mucopurulent discharge is tenacious and it dries in crusts. Catarrhal sinusitis is marked by tenacious mucous discharge which is often retained in the nasal cavity, and dries in crusts. The discharge in serous, or allergic maxillary sinusitis accumulates in the sinus and drains in portions when the patient

assumes a certain position facilitating drainage of the sinus through the nasal meatus. An unpleasant odour is sometimes the main complaint of the patient who feels the smell himself. Olfaction is often impaired on the involved side (to anosmia). This disorder is usually of the respiratory type. In bilateral chronic pathologies in the maxillary sinuses patients always complain of decreased sense of smell.

Local or diffuse headache usually develops only during exacerbations or in obstructed drainage of the sinus. During remission, the general objective and subjective condition of the patient is satisfactory.

Exacerbation of a chronic process can be attended with elevated temperature, worsening of the patient's condition, painful swelling of the cheek, oedema of the eyelid and local or diffuse headache.

Cleaning and anaemization of the nasal mucosa are required before rhinoscopy. To that end, a 3 per cent ephedrine solution should be sprayed over the nasal mucosa, or it should be treated by a cotton applicator moistened with ephedrine solution. The discharge from the middle concha can reappear after the removal of the previous portion; it can emerge from the orifice of the maxillary sinus (as in acute maxillary sinusitis).

Serous-catarrhal maxillary sinusitis facilitates formation of polyps which usually grow from the middle nasal meatus.

Like in adults, chronic maxillary sinusitis in children is secondary to the acute disease. Adenoids and adenoiditis play an aggravating role in the aetiology and pathogenesis of maxillary sinusitis. Catarrhal, serous, and catarrhal-suppurative forms of sinusitis are common in children. The suppurative form is rare.

Oedema of the mucosa of the maxillary sinus is characteristic for sinusitis in children. Oedema often impedes respiration through the nose and simulates exacerbation of chronic inflammation. Restoration of nasal respiration in such cases leads to normalization of the sinus mucosa. Chronic maxillary sinusitis in children is often exacerbated. The temperature often elevates, the child is weak and complains of fatigue; conjunctivitis and regional lymphadenitis occur in some cases; headache is frequent.

In rare cases, in the presence of dental granuloma, cysts and fistulae in the sinus, a cholesteatoma can form from the cells of the squamous epithelium.

True (retention) cysts of the sinus form due to obstruction of the mucous glands when the mucosa swells and the gland duct is

closed with connective tissue. Pseudocysts can also develop in the sinus, but they differ from true cysts by the absence of the inner epithelial coat. They are actually regions of oedematous mucosa. The main symptom of a cyst is headache arising due to compression of the endings of the trigeminal nerve. Amber-coloured liquid can at times issue from one side of the nose, after which the headache subsides. This is a sign of spontaneous drainage of the cyst.

In addition to the mentioned signs, the cysts can cause morphological changes in the bony walls of the sinus (osteolysis, to perforation). The anterior and medial walls are more likely to undergo such changes. Simple and especially contrast X-raying are effective means for diagnosing cysts of the sinus. In adults in the presence of caries of roots of the upper teeth (4, 5, 6), the so-called odontogenic cyst can also develop.

Diagnosis is based on the patient's complaints, anamnestic data and examination findings (X-ray, diaphanoscopy, puncture and irrigation of the sinus). If the picture is obscure, contrast X-ray examination and echography help the situation.

The pathological discharge from the nose and sinus (taken during antral puncture) is examined in the laboratory for the presence of microflora and for sensitivity to antibiotics. Diagnostic puncture of the maxillary sinus is widely used in older children. Pathology of the maxillary sinus should be differentiated from frontitis, ethmoiditis, and in rare cases from sphenoiditis. These diseases often occur simultaneously, especially unilateral inflammation of the maxillary and ethmoidal sinuses. In adults it is necessary to rule out the odontogenic nature of the disease, especially in the presence of a suppurative process in the roots of the upper teeth (4, 5, 6), whose apices are in the immediate vicinity of the floor of the maxillary sinus.

Conservative treatment. Treatment should begin with elimination of causes of the disease. If maxillary sinusitis is odontogenic, the teeth should first of all be treated; conservative treatment will then often be quite efficacious. It should be noted that radical operations on the sinus will be ineffective if the odontogenic cause remains active. In the presence of adenoids or adenoiditis in children, the tactics should be the same: the nasopharynx should first be treated, and only then should treatment of maxillary sinusitis be started.

As a rule, general antibacterial treatment is not indicated outside exacerbations, and it should only be administered during exacerba-

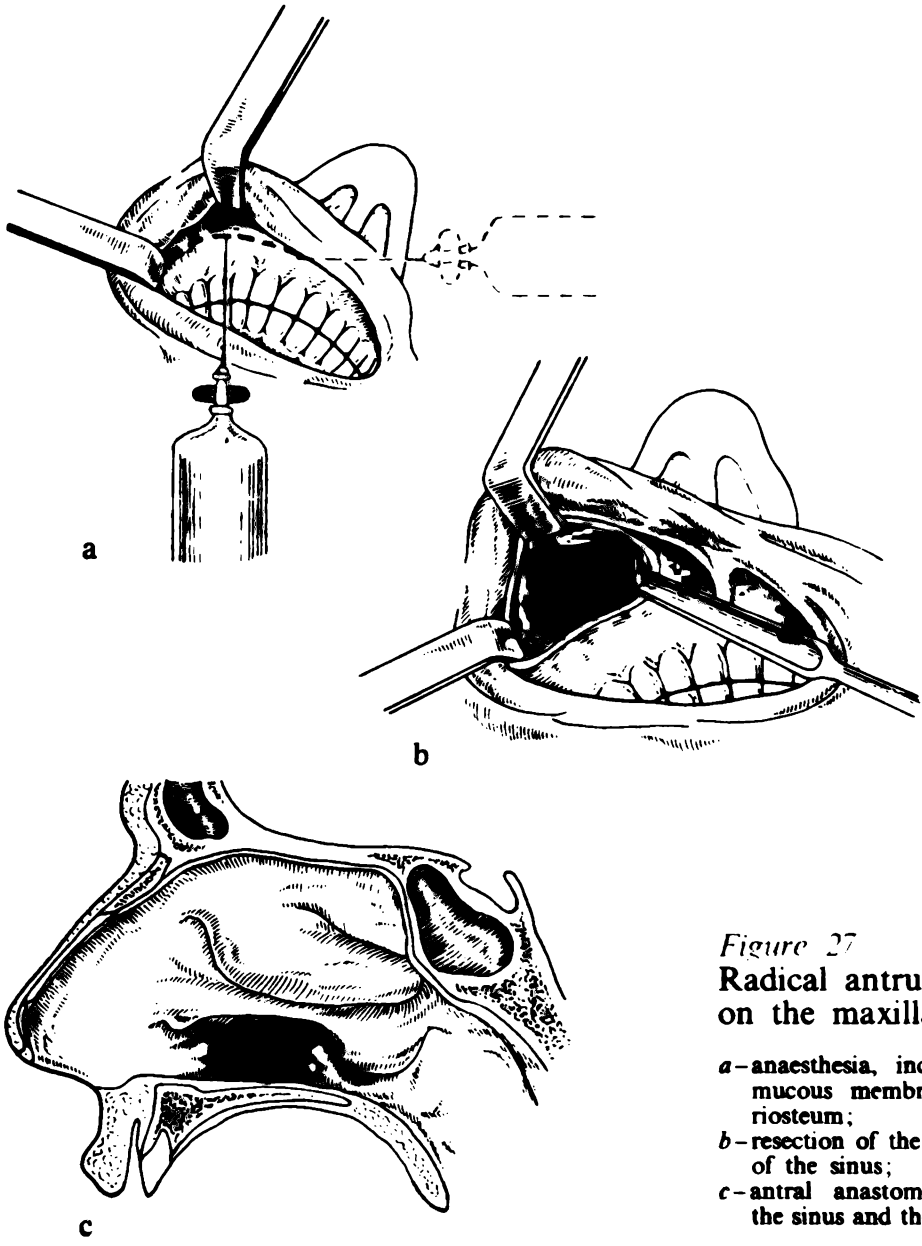

Figure 27
Radical antrum operation on the maxillary sinus:

a – anaesthesia, incision of the mucous membrane and periosteum;
b – resection of the anterior wall of the sinus;
c – antral anastomosis between the sinus and the nasal cavity

tion (in combination with other medical procedures, depending on the sensitivity of the microflora).

Treatment of chronic maxillary sinusitis should begin with simultaneous use of several conservative methods.

1. Antral puncture and irrigation of the sinus with a disinfectant solution (furacin, potassium permanganate solution, peloidin) or enzymes (chymopsin and the like), and administration into the sinus of a solution of the antibiotic to which the microflora is sensitive.

2. In addition to the irrigation of the sinus, UHF and SHF therapy should be applied to the involved area (a total of 12

sessions). The sessions should not be conducted on the day of irrigation. High arterial pressure, tumours, and poor tolerance are contraindications for UHF and SHF.

3. Vasoconstrictors are indicated: 5 drops into each side of the nose, 3 times a day. Long-action preparations should be preferred (otrivin, naphazoline). The course of treatment should last 7-10 days (not longer than 2 weeks).

The sinus is sometimes irrigated through a thin polythene tube which is passed into the sinus through a thick needle during the first antral puncture; the tube is left in the sinus for the entire course of treatment. If the virulence of the microflora is high, long-action preparations are administered into the sinus, such as chinosol paste (1 g of chinosol, 0.2 g of hydrocortisone, and 20 g of Shostakowsky's balm).

If conservative treatment of chronic suppurative maxillary sinusitis fails, a radical operation of the maxillary sinus is indicated (Fig. 27).

Conservative treatment is usually minimally effective in catarrhal, serous and vasomotor maxillary sinusitis, but is can help in the early stages of the disease. The main technique is also antral puncture and irrigation of the maxillary sinus. But instead of antibacterial preparations, astringent substances are recommended (3 per cent colloid silver or protein silver solution) or steroid preparations (hydrocortisone or prednisolone) together with antihistaminics, e. g. dimedrol (diphenhydramine hydrochloride), chloropyramine. In some cases it becomes necessary to open the maxillary sinus endonasally.

Patients with the polypous and suppurative-polypous forms of maxillary sinusitis usually require radical surgical treatment which should be followed by conservative treatment to prevent relapses of polyposis. Postoperative conservative treatment includes endonasal electrophoresis with calcium chloride, regular administration of astringent preparations, and if signs of allergy are obvious, antiallergic treatment is indicated. All patients with chronic maxillary sinusitis should be observed in out-patient conditions.

Large cysts that compress the walls of the sinus, cause headache and impede nasal respiration or cause some other symptoms should be removed.

Patients with cholesteatoma, caseous and necrotic maxillary sinusitis need surgical treatment.

Surgical treatment. Operations on the maxillary sinus are performed with endonasal and extranasal approach. With the endonasal

approach, the surgeon cannot survey fully the entire sinus, and the pathological tissues cannot be radically removed from it. The endonasal technique can only be used to open the medial wall of the sinus and to perforate it for drainage and aeration of the sinus. The extranasal approach with the Caldwell-Luc operation ensures an easy access to all parts of the sinus and the operation is therefore radical. This technique includes incision of the soft tissues under the upper lip, separation of these tissues, and approach to the anterior wall of the maxillary sinus. The sinus is then opened, the pathological matter removed, and a communication with the nasal cavity is made.

Acute frontal sinusitis. Acute frontal sinusitis can be secondary to acute rhinitis and ethmoid sinusitis, general viral infection, acute respiratory disease, or chilling of the body.

The main symptoms of acute frontal sinusitis are pain in the forehead, diffuse headache or pain over various parts of the head, and purulent discharge from the involved side of the nose. Severity of frontal pain can vary, but it is, as a rule, intensified on palpation or percussion. The nasal discharge is first serous and liquid; later it becomes purulent, odour is usually absent. Nasal respiration through the involved side is impeded. The patient complains of general fatigue and indisposition. If the affection is pronounced, the body temperature can elevate to subfebrile levels.

The forehead in the area overlying the frontal sinus can be swollen and the skin hyperaemic. The internal angle of the orbit and the upper eyelid can also be involved. Palpation of the swollen area, especially of the inferior wall of the sinus, is very painful. A special cannula is passed into the frontal sinus for diagnostic purposes and for irrigation. But since the approach to the sinus is through a curved frontonasal duct, this manipulation is not always possible. X-ray control is recommended during this operation.

X-ray examination and trephination puncture of the frontal sinus are used for diagnostic purposes. Trephination is also an effective therapeutic means.

Treatment is usually conservative. But if the disease is long-standing and complications develop in the orbit, skull, or other organs, surgery should be performed immediately to eliminate the purulent focus and to restore patency of the frontonasal duct. Local treatment includes application of preparations causing anaemization of the nasal mucosa: a 3 per cent cocaine and 3 per

cent ephedrine solutions, once a day; vasoconstrictors (galasoline, naphazoline). UHF- and SHF-therapy of frontal sinusitis is indicated only for cases where drainage of the sinus is adequate; otherwise physiotherapy will exacerbate the process. Elevated temperature and headache can be managed by oral or parenteral administration of antibacterial preparations in the appropriate doses (ototoxic preparations should not be given); acetylsalicylic acid and antipyrine are useful. The absence of the desired effect is an indication for probing or puncture of the sinus.

Chronic frontal sinusitis. The most common cause of conversion of acute frontal sinusitis into its chronic form is persistent obstruction of the frontonasal duct and decreased reactivity of the body, especially subsequent to general infectious diseases. This process is promoted by hypertrophy of the middle concha, significant deformity of the nasal septum, a narrow or tortuous frontonasal duct, or polyps in the nasal cavity.

There may be no complaints from the patient during remissions. A small amount of the nasal discharge often escapes into the nasopharynx to cause chronic pharyngitis, laryngitis, and tracheitis. But in most cases, the disease causes diffuse headache and frontal pain. The nasal discharge from the involved side is almost continuous; the discharge is often fetid; nasal respiration and olfaction are impaired, especially in bilateral affection.

Palpation of the walls of the frontal sinus is often painful, especially at the upper internal angle of the orbit, which can be swollen. In the absence of microflora, obstruction of the frontonasal duct sometimes stimulates the accumulation of discharge in the sinus and the formation of mucocele consisting of secretions of the mucous glands, goblet cells, and lymph. In the presence of infection in the sinus, a subperiosteal abscess can develop for the same reason; a suppurative fistula can also form, usually in the inferior wall, most frequently closer to the inner canthus of the eye. If the symptoms are pronounced, diagnosis of the disease is not difficult.

Treatment. In the absence of local and general complications, conservative treatment is indicated. It is directed at providing adequate drainage of the secretion from the sinus using vasoconstrictors which are instilled into the nose, administering these substances (using a turunda) under the middle concha, suction of the sinus contents through a cannula, irrigation of the sinus, and administration into it of antibacterial preparations (after prelim-

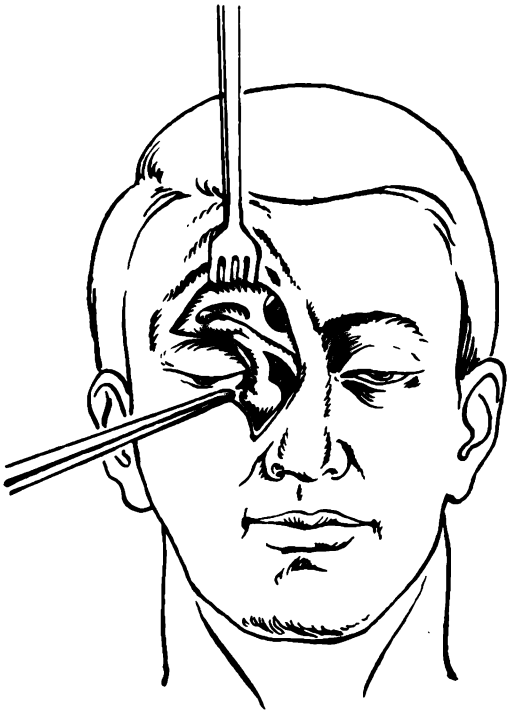

Figure 28
Operation on the right frontal sinus

inary testing of the microflora for sensitivity to these preparations).

In the absence of exacerbation, general antibacterial treatment and physiotherapy are unnecessary in chronic frontal sinusitis. Trephination puncture of the frontal sinus with removal of its contents and subsequent irrigation and administration of medicinal preparations are effective.

Long-standing and persistent chronic frontal sinusitis (despite active treatment), and also symptoms of developing complications (and complications themselves) are indications for surgical treatment (Fig. 28).

Acute ethmoid sinusitis commonly follows acute rhinitis, influenza, often in combination with acute inflammation of the other paranasal sinuses. Acute ethmoid sinusitis in children is secondary to an acute respiratory disease, measles, scarlet fever, and other infectious diseases; sometimes it has the character of necrotic osteitis, often in combination with acute maxillary sinusitis.

The symptoms of acute ethmoid sinusitis are pressing pain in the dorsum and the bridge of the nose, headache of various localization, and significant impediment of nasal respiration. The first days of the disease are marked by copious serous discharge from the involved side of the nose which later becomes mucopurulent or purulent. The discharge is usually odourless.

Oedema and hyperaemia of the internal angle of the orbit and the adjacent parts of the lower and upper eyelids, and also conjunctivitis are frequent findings in children. Hypo-osmia or anosmia and impaired olfaction of the non-involved side of the nose are also frequent.

An elevated body temperature occurs in response to influenza or other infectious disease, but in acute ethmoid sinusitis the temperature is usually between 37.5 and 38 C and persists for a week.

The diagnosis can be confirmed by X-ray examination and, if necessary, by ophthalmological and neurological examination; an infectionist must also be consulted. The nasal discharge should be studied for microflora and its sensitivity to antibiotics which will help assess the severity of the infection and prescribe the appropriate antimicrobial therapy.

Treatment is conservative. If any complications develop (or are likely to develop), surgical treatment is indicated. Vasoconstrictors are instilled into the nose. The same preparations are applied under the middle concha. UHF or SHF on the area of the ethmoidal sinus are indicated. If the body temperature is elevated, antibacterial preparations are given per os. Parenteral administration of antibacterial preparations is indicated for severe cases. The antibiotic should be prescribed after testing the microflora for sensitivity to this antibiotic. If a closed empyema or ophthalmic complication develops, the cells of the ethmoidal labyrinth should be opened to gain access to the purulent focus in the orbit.

Chronic ethmoid sinusitis. An improperly treated acute ethmoid sinusitis plays the leading role in the aetiology of chronic ethmoid sinusitis. The disease is often secondary to the affection of the other paranasal sinuses. Chronic ethmoid sinusitis therefore often concurs with frontal sinusitis, sphenoid sinusitis, and more frequently, maxillary sinusitis. The catarrhal-serous and catarrhal-suppurative forms of chronic ethmoid sinusitis prevail. These are marked by formation of polyps.

The symptoms depend on the activity of the disease. During remission, the patient complains of occasional headache, mostly in the region of the nose root and bridge; headache is sometimes diffuse. In serous-catarrhal ethmoid sinusitis, the nasal discharge is clear and copious. The suppurative form is characterized by a meagre discharge that dries to form crusts. The nasal discharge often has a fetid odour. Involvement of the posterior cells of the ethmoidal labyrinth promotes accumulation of the discharge in the

nasopharynx, usually in the morning. Olfaction is impaired to some degree.

Treatment of non-complicated forms is usually conservative. Sometimes it is combined with endonasal operations (polypotomy, opening of cells of the ethmoidal labyrinth, partial resection of the conchae, etc.). Opening of the cells of the ethmoidal labyrinth and polypotomy with an endonasal approach are the most common operations. As a rule, these two operations are performed simultaneously.

Acute and chronic sphenoid sinusitis. Isolated affection of the sphenoidal sinuses is rare. The inflammation is usually combined with lesion of the posterior cells of the ethmoidal labyrinth.

Acute sphenoid sinusitis is marked by severe oedema of the mucosa. The process can be unilateral or bilateral. The most common subjective symptom of acute sphenoid sinusitis is headache in the occipital region and inside the head; the pain is sometimes felt in the orbit, and in rare cases, in the vertex of the skull and the temples. Nasal discharge is often absent because it passes from the superior nasal meatus into the nasopharynx and further along the posterior wall of the pharynx, where it can easily be seen during pharyngoscopy and posterior rhinoscopy. The body temperature is usually subfebrile; the general condition is satisfactory; the patient can complain of weakness, discomfort, and irritability.

X-ray examination is an important diagnostic tool. If the clinical picture is obscure (and also for the therapeutic purposes), the sphenoidal sinus can be punctured through its anterior wall.

Treatment is usually conservative: local treatment with vasoconstrictors and general antibacterial treatment. If the disease lasts longer than 2 weeks, the sinus should be irrigated or opened endonasally. Symptoms of complications (septic, intracranial, ophthalmic) are indications for emergency operation on the sphenoidal sinus.

Chronic sphenoid sinusitis is provoked by the same conditions as chronic affection of the other paranasal sinuses.

RHINOGENIC COMPLICATIONS

Ophthalmic complications (infiltrative and suppurative complications of the orbit soft tissues, destruction of the orbit walls, etc.) develop subsequently to acute and chronic inflammatory processes in the paranasal sinuses, usually when the cells of the ethmoidal

labyrinth and the frontal sinus are affected and less frequently in diseases of the maxillary and the sphenoidal sinuses.

Infection spreading from the sinus into the orbit is facilitated by the anatomic position of the orbit and the canals through which the nerves and vessels pass. Less frequently, the inflammation extends through congenital open defects (dehiscence).

The leading symptoms in ophthalmic complications of acute frontal sinusitis are limited mobility and downward displacement of the eyeball and pain. Subperiosteal abscess in the superomedial angle of the orbit can be the initial stage of the disease. The upper eyelid moves with difficulty: it is hyperaemic and swollen.

Complications of the eye and its orbit are severest in ethmoid sinusitis.

Inflammation of the posterior cells of the ethmoidal labyrinth and the sphenoidal sinus spreads to the orbit impairing the visual acuity, narrowing the field of vision, and intensifying scotoma. Maxillary sinusitis rarely gives complications in the eye or orbit. Only a subperiosteal abscess in the superior wall of the sinus can induce development of retrobulbar phlegmon.

Treatment is surgical with simultaneous general anti-inflammatory treatment. In children, the paranasal sinuses, especially cells of the ethmoidal labyrinth, should be opened by extranasal approach.

Intracranial complications. Rhinogenic intracranial complications are very dangerous. True, they occur in rare cases, due to the penetration of infection from the nose and the paranasal sinuses to the cranium.

The most frequent cause is diseases of the nose and the paranasal sinuses of influenzal aetiology. Among other infections scarlet fever, measles, and erysipelas should be mentioned.

In 75 per cent of the cases, rhinogenic intracranial complications arise due to chronic inflammation in the sinuses, and in 25 per cent of the cases, they are secondary to acute sinusitis.

The initial symptom of the disease is headache, which can be due to developing hydrocephalus in response to the inflammation.

The pathogenesis of rhinogenic intracranial complications is connected to a certain degree with the anatomy and topography of the nose and the paranasal sinuses, which play an important role in the infection spreading. The infection can spread by the contact, haematogenic and lymphogenic pathways.

Theatment of rhinogenic intracranial complications requires emer-

gency surgical intervention with subsequent dehydration, anti-inflammatory and symptomatic treatment.

FUNGAL DISEASES OF THE NOSE AND PARANASAL SINUSES

Fungal affections of the nose and the paranasal sinuses are rare diseases. An isolated fungal process in the nose alone occurs in exceptionally rare cases. The main causative agent of this pathology is the *Aspergillus* fungus, but some species of *Penicillium* and *Candida* organisms can also be the causative factor.

The *aetiology* of mycoses is mainly based on the administration of antibiotics to patients with some other inflammatory diseases.

Injury plays the leading role in the *pathogenesis* of the disease. Trauma impairs the protective function of the mucous membrane, while the serous secretion serves as a nutrient medium for the growth of the fungi. Allergic diseases which exhaust the organism are also important for the pathogenesis of fungal diseases.

The maxillary sinus is affected in most cases. Sometimes several sinuses are involved simultaneously.

Clinical picture of fungal sinusitis is quite varied and includes only a few specific symptoms. Among them are occasional discharges with specific colour and odour, headache, feeling of heaviness in the head and pressure in the involved sinus, and tickling in the nose. Sneezing and liquid discharge from the nose occur less frequently. Soft tissues of the face can swell and a fistula develop in fungal affection of the paranasal sinuses. If the maxillary sinus is affected, a fistula develops in the region of the lower eyelid; in disease of the frontal sinus, it appears in the region of the upper eyelid, at the inner angle of the orbit.

The rhinoscopic picture of fungal diseases of the nasal mucosa differs insignificantly from the picture of common inflammation. The colour and the consistency of the nasal discharge in fungal diseases vary, depending on the particular causative agent. Fungal inflammation of the paranasal sinuses occurs in two forms. The first form is superficial affection of the mucosa, while in the second form it extends to the periosteum and the bone.

The mycotic affections of the nose and the paranasal sinuses are long-standing and marked by occasional exacerbations.

Diagnosis is based on the clinical and laboratory findings. Fungal affection of the nose and the paranasal sinuses should be differentiated from tuberculosis.

Treatment includes a series of general and local procedures. In local treatment of nasal mycoses preference should be given to application of ointments after preliminary separation of crusts from the nasal mucosa and other pathological matter from the nose. Nystatin, levorin or sanguiritrin ointment should be applied to the nasal mucosa using a glass spatula. These ointments should sometimes be applied in combination with other ointments containing corticosteroids (prednisolone, hydrocortisone, or locacorten). If the skin of the nasal vestibule and of the upper lip is excoriated, these areas should be treated with Castellani's mixture, solutions of gentian violet, or chinosol. Strains of fungi can be resistant to various preparations, and therefore the medicinal preparations should be alternated. In order to prevent relapses, a 0.1 per cent chinosol solution should be instilled into the nose after recovery.

Like diseases of the nose, mycotic diseases of the paranasal sinuses are treated by administering 2-4 mln U of nystatin and levorin daily per os for a month. The nystatin dose can be increased to 5-8 mln U daily because of the poor absorption of the preparation in the intestine. General treatment can include sulpha drugs (sulphaethidole 2.5 g a day, or madribon 1 g a day). Iodotherapy of fungal sinusitis is not used. Vitamins B and C should be given to the patient. If the paranasal sinuses are deeply affected, surgical intervention is required, as in common inflammatory processes. During the postoperative period, the sinuses should be irrigated with solutions of the sodium salt of nystatine (5 mg/ml or 10000 U/ml), a solution of the sodium salt of levorin (the same concentration), suspensions of nystatin and levorin (1:1000), a chinosol solution (0.1; 0.05 and 0.01 per cent), and an aqueous solution of gentian violet (0.1; 0.01 per cent). If the affection is only superficial, the mucosa of the sinus can be treated by puncturing the sinus and irrigating it with the solutions mentioned above. Courses of treatment should be given at two-week intervals. Clinical recovery is determined by the absence of symptoms of fungal affection of the nose and the paranasal sinuses for a year.

PRE- AND POSTOPERATIVE MANAGEMENT OF SURGICAL PATIENTS

The hospital nurse who is directly involved in preparing the patient for surgery should always be at the patient's bedside. Following the surgeon's or anaesthesiologist's orders she sees to it

that the patient takes hypnotic, sedative and anti-allergic agents at the appropriate time; she takes his temperature, controls the patient's stools and urination, and watches the patient's behaviour.

Since the patient is given pre-operative treatment in his ward, he is delivered to the operating room on a trolley. After surgery and delivery back to the ward, the patient is administered proper postoperative care. Before placing the patient in his bed, a waterproof sheet should be placed on top of the linen to prevent it from soiling. The patient's head should be positioned on the pillow in a slightly elevated position. An ice bag wrapped in a towel should be applied to the operated side for 6-8 hours. At 30-40-minute intervals the ice bag should be removed for 10-15 minutes.

During the first postoperative day the nurse should be especially careful not to overlook possible nasal bleeding. If nosebleed begins, the physician should be informed immediately. For 4-5 post-operative days the patient should be given warm liquid food. Patient's stools and urination should be controlled. In addition to the measures mentioned above, the nurse should also perform her common duties.

Review Questions

1. What care should be given to patients operated on for pathology of the maxillary sinus?
2. What tools are used for repositioning fragments of the fractured nasal bones?
3. How is a four-tailed bandage applied to a patient operated on his concha?
4. How should drops be instilled into the nose?

Problem

A patient with bleeding from the right side of the nose seeks for medical care. Examination reveals haemorrhage of the nasal mucosa in the anterior third of the nasal septum. The arterial pressure is 180/110 mm Hg; the pulse rate is 98 per minute; the pulse is tense.

What measures should be taken to arrest the haemorrhage and to prevent its possible relapse?

DISEASES OF THE PHARYNX AND THE OESOPHAGUS

Diseases of the pharynx are classified as injuries, hypertrophic changes, acute and chronic non-specific inflammations of the pharyngeal mucosa, lymphoid formations and tumours.

CLINICAL ANATOMY OF THE PHARYNX

The **pharynx** is a part of the alimentary and respiratory tracts. This is a hollow organ formed by muscles, fibrous membranes, and lined on the inside with mucous membrane. The pharynx connects the nasal and oral cavities with the larynx superiorly and with the oesophagus inferiorly. The pharyngeal cavity is located posterior to the nasal and oral cavites and the larynx, and anterior to the base of the occipital bone and six cervical verbetrae; it passes into the oesophagus below the sixth cervical vertebra (Fig. 29). The pharynx is divided into three parts: nasopharynx (epipharynx), oropharynx (mesopharynx) and the laryngopharynx (hypopharynx).

As one swallows or utters a sound, for example, a vowel, the soft palate rises and moves back to contact, for a short time, the posterior wall of the pharynx, thus closing completely the nasopharynx. Seven orifices open into the pharynx: two openings of the choanae and two openings of the auditory tubes are in the nasopharynx; the fauses opens into the oropharynx; and the inlet of the larynx and the oesophagus are found in the laryngopharynx.

The **nasopharynx** performs only the respiratory function. Its walls do not collapse and they are immovable. Two choanae are found anteriorly. Funnel-shaped openings of the auditory tubes are located on the lateral walls, at the level of the posterior ends of the

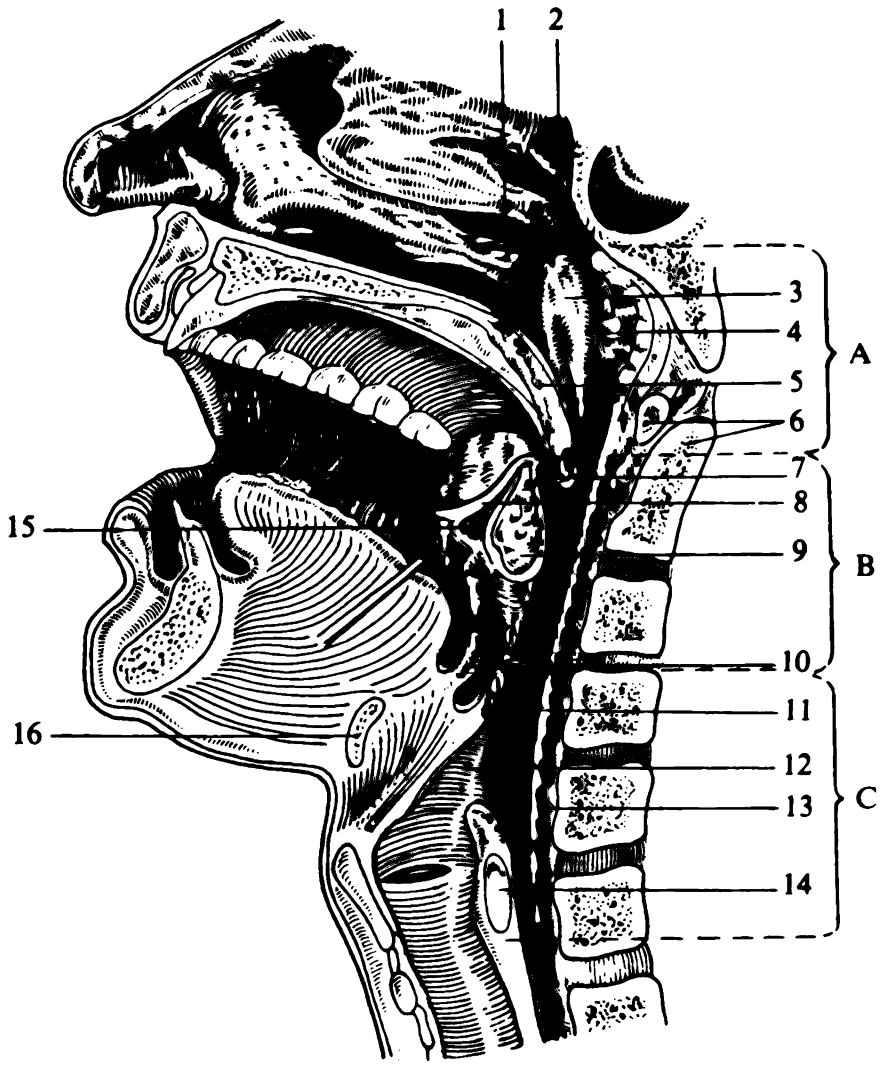

Figure 29
Sagittal section of the pharynx (after Jackson):

1 – inferior nasal concha;
2 – middle nasal concha;
A – nasopharynx;
3 – opening of the auditory tube;
4 – tubal tonsil;
5 – soft palate;
6 – arch and body of cervical vertebra;
B – oropharynx;
7 – uvula;
8 – palatine arches;
9 – palatine tonsil;
10 – lingual tonsil;
C – laryngopharynx;
11 – epiglottis;
12 – inlet of the larynx;
13 – prevertebral fascia;
14 – cricoid cartilage;
15 – triangular fold;
16 – hyoid bone

inferior conchae. Posterior to the openings of the auditory tubes, on each side, found are the pharyngeal recesses, in which lymphoid tissue is usually accumulated. These lymphoid formations are called the tubal tonsils (pharyngeal tonsils V and VI). At the border between the superior and posterior walls of the nasopharynx is the pharyngeal tonsil (nasopharyngeal tonsil III). The pharyngeal tonsil is well developed only in children (Plate III). During sexual maturation, the tonsil diminishes and by the age of 20 turns into

a small strip of adenoid tissue; atrophy of this tonsil continues in adulthood. The border between the superior and middle parts of the pharynx is an imaginary plane passing at the level of the hard palate.

The **oropharynx** is the part of the pharynx through which air and food pass; the alimentary and respiratory tracts meet in this region. Anteriorly the oropharynx opens into the mouth (fauces), while the posterior wall of the oropharynx borders on the third cervical vertebra. The fauces is confined in the space between the edge of the soft palate, the anterior and posterior palatine arches, and the root of the tongue. The middle part of the soft palate ends in a fleshy mass known as the uvula. The soft palate forms the posterior and anterior palatine arches. As their muscles contract, the opposite arches approach each other and act like a sphincter during swallowing. In the soft palate itself a muscle is found which elevates the palate to bring it in contact with the posterior wall of the pharynx. Contraction of this elevator muscle widens the lumen of the auditory tube. The other muscle of the soft palate strains and stretches the palate thus widening the opening of the auditory tube but narrowing its lumen in the rest of it.

Palatine tonsils (I and II) are found in triangular recesses (tonsillar fossae) between the palatoglossal and palatopharyngeal arches. The histological structure of the lymphoid tissue of the pharynx is uniform: a mass of lymphocytes with spheric formations known as follicles is located between connective-tissue fibres. The structure of the palatine tonsils is important from the clinical standpoint. Their free surface is exposed to the pharyngeal cavity and is lined with mucous membrane with stratified squamous epithelium. The tonsil has 16-18 deep pits known as lacunae, or crypts. The outer surface of the tonsils is connected with the lateral wall of the pharynx by a firm fibrous membrane called the capsule. The lacunae penetrate into the depth of the tonsil where they ramify two, three, or even four times.

The walls of the lacunae are lined with squamous epithelium which is desquamated at many points. In addition to the desquamated epithelium, which is the main material of plugs, the tonsillar crypts also contain microflora, lymphocytes, neutrophils, etc.

Emptying of the branching lacunae can be easily impaired due to their deep location, sinuosity and narrow passages, which can be narrowed even more by cicatricial stenosis of their orifices; moreover, some lacunae (in the anteroinferior part of the tonsil) are covered with a mucous fold. All these anatomical and topo-

graphic characteristics of the tonsils provide favourable conditions for their inflammation.

Lymphoid tissue is also found on the posterior wall of the pharynx where it is present in the form of small (punctate) granules or follicles; it is also found posterior to the palatine arches, on the lateral walls of the pharynx. Small accumulations of lymphoid tissue are also found at the entrance to the larynx and in the piriform pharyngeal recesses. The lingual tonsil (IV) is located on the root of the tongue.

The following lymphoid formations thus form a sort of a ring: two palatine tonsils, two tubal tonsils, one pharyngeal tonsil, one lingual tonsil, and the fine accumulations of lymphoid tissue. All these tonsils are called the throat ring (Pirogov-Waldeyer tonsillar ring).

The laryngopharynx. The superior edge of the epiglottis and the root of the tongue form the border between the oropharynx and the laryngopharynx. The lower end of the laryngopharynx narrows into a funnel and is continuous with the oesophagus. The laryngopharynx is located anterior to the fourth-sixth cervical vertebrae. The entrance to the larynx borders the laryngopharynx anteriorly and inferiorly. Along the sides of the entrance to the larynx, between the entrance and the lateral walls of the pharynx, are found cone-shaped diverticula known as the piriform recesses. Food moves to the oesophagus by these piriform recesses. The bulk of the inferior part of the pharynx is located behind the larynx so that its posterior wall is also the anterior wall of the pharynx.

The pharyngeal wall consists of four layers. The main layer is a fibrous membrane, which is lined with mucosa on the inside (from the side of the pharyngeal cavity), and with muscles on the outside. The outer surface of the muscles is lined with a layer of loose connective tissue, the adventitia, owing to which the pharynx can move relative to the surrounding anatomic structures.

The mucosa of the pharynx (its upper portion) is covered with stratified ciliated epithelium in accordance with the respiratory function of the nasopharynx. Stratified squamous epithelium lines the middle and lower parts of the pharynx. The mucosa of the pharynx, especially of the nasopharynx, and the pharyngeal surface of the soft palate and of the tongue root are rich in mucous glands. Lymphoid tissue (the tonsils included) is located in the submucous layer.

The muscular layer of the pharynx includes striated fibres (circular and longitudinal) which contract and elevate the pharynx.

Three constrictor muscles of the pharynx, namely, the superior, the middle, and the inferior constrictor muscles are responsible for its contraction.

Two longitudinal muscles elevate the pharynx. As the muscles contract, they ensure the peristalsis-like movement of the pharynx. At the moment of swallowing, the pharynx rises and the food thus moves downward, to the mouth of the oesophagus.

A retropharyngeal space is found between the posterior wall of the pharynx and the prevertebral fascia. The space is a flat slit packed with loose connective tissue. The retropharyngeal space is divided sagittally by the median septum into two symmetric parts. In children, there are lymph nodes close to the median septum into which the lymphatic vessels of the palatine tonsils and the posterior parts of the nasal and oral cavities empty. These nodes atrophy with age. The nodes can purulate in children thus causing a retropharyngeal abscess. The parapharyngeal space lined with connective tissue is located by sides of the pharynx. A neurovascular bundle and the main cervical lymph nodes are found here.

The length of the pharynx in an adult varies from 12 to 15 cm; the anteroposterior diameter of the pharynx is smaller than its transverse diameter; it is 4.5 cm on the average.

The pharynx is supplied with blood mainly by the branches of the external carotid artery.

The lymph is emptied from the pharynx into the deep and posterior cervical lymph nodes. The lymphoid formations of the pharynx (all tonsils included) have no vessels by which lymph is supplied to them.

The pharyngeal nervous plexus is located on the external and internal surfaces of the middle constrictor of the pharynx. The plexus is responsible for the motor and sensory innervation of the pharynx.

CLINICAL PHYSIOLOGY OF THE PHARYNX

Through the pharynx, food and saliva pass into the gastrointestinal tract and air passes into the larynx (and further to the lungs and back). The pharynx is involved in the following vital functions: (1) ingestion of food (sucking and swallowing); (2) production of vocal sounds; (3) respiration; (4) protective function (during eating and respiration).

Ingestion of food during the first months of life can only be accomplished by sucking.

The passage of food by the pharynx, from the mouth into the oesophagus, is accomplished by a complicated and well coordinated swallowing reflex, during which the muscles of the tongue, pharynx and the larynx contract in a specific sequence.

The *vocal* (sound-producing) function of the pharynx includes intensification of sounds produced in the larynx by resonance. The voice timbre is formed in the cavities of the larynx, pharynx, nose, paranasal sinuses, and the mouth. Sounds of varying pitch and volume are produced in the larynx. The production of vowels and consonants occurs mainly in the oral and, to a lesser degree, in the pharyngeal cavities. As a vowel is pronounced, the soft palate separates the nasopharynx from the mouth cavity, while the consonants are produced with the soft palate lowered.

All parts of the pharynx are involved in the *respiratory* function. But if the nasal passages are obstructed, breathing is accomplished through the mouth. In this case, and partly during speaking and singing, air does not enter the nasal cavity but gets into the oropharynx.

The *protective* function of the pharynx consists in reflex contraction of the pharyngeal muscles when a foreign body or an irritating substance (corrosive chemical, hot liquid) gets into the pharynx. As the muscles contract, the lumen of the pharynx narrows to prevent deeper penetration of the irritating factor.

Inspired air is first warmed in the nose and then in the pharynx, where it is also cleaned from dust which sticks to the mucous lining of the pharyngeal walls. The mucus is then either expelled outside, or swallowed and inactivated in the alimentary tract.

The physiology of the palatine tonsils is not autonomous. It is part of the function of the entire lymphatic system of the body. It is believed that the lymphoid apparatus of the pharynx, in particular, the palatine tonsils (like similar accumulations of lymphoid tissue in the small intestine) protect the body from the ingress of micro-organisms. At the same time, the anatomical structure of the palatine tonsils (the presence of crypts) provides conditions for the vegetation of micro-organisms in them; toxins produced by propagating micro-organisms enter the body to cause infectious diseases.

During the first years of life, the lymphoid structures of the pharynx attain maximum growth, but during sexual maturation (at the age of 14-15) they undergo partial and gradual back development.

EXAMINATION OF THE PHARYNX

Inspection and palpation. The neck and the mucosa of the lips are inspected. Next, the regional lymph nodes of the pharynx are palpated: the submandibular nodes, the nodes in the retromandibular fossae, deep cervical, posterior cervical nodes and the nodes in the supra- and subclavicular fossae.

The patient is asked to open the mouth. The examiner pulls the angle of the mouth aside using a spatula, and inspects the entrance to the mouth (the mucosa and the parotid ducts). The mouth cavity is then examined: the teeth, the gums, the hard palate, the tongue, the sublingual and submandibular ducts, and the floor of the mouth. In order to inspect the mouth floor, the tongue should be lifted using a spatula, or the patient is asked to raise it.

Mesopharyngoscopy. Using a spatula (held in the left hand) the anterior two-thirds of the tongue should be pressed down (without touching the root of the tongue, because this will stimulate the vomiting reflex). The mobility of the soft palate should be determined by asking the patient to utter the sound 'ah'. A normal soft palate is readily movable.

The mucosa of the soft palate, of the uvula, and the anterior and posterior palatine arches should then be inspected. Normal mucosa is smooth and pink; the arches are well defined.

The size of the palatine tonsils should be estimated. To that end, the distance between the edge of the anterior palatine arch and the line passing through the middle of the uvula and the soft palate is divided conventionally into three parts. If the tonsil extends to one-third of this distance, its size is classified as degree I; if it extends to two-thirds of the length, as degree II; and if the tonsil extends to the midline of the pharynx, the size is classified as degree III.

The mucous membrane of the tonsils should next be examined. Normally it is pink, smooth and moist. The lacunae contents should be examined. To that end, two spatulas are used. Using one spatula, the tongue is pressed down, while the other spatula (in the other hand) is used to press the base of the anterior arch and, through its agency, the tonsil, at its upper pole. A normal tonsil contains non-purulent scarce secretion (epithelial plugs) in its lacunae. The lacunae can contain no plugs at all.

The mucosa of the posterior wall of the pharynx is then examined. The normal mucosa is pink, moist and smooth. Granules (accumulations of lymphoid tissue), approximately 1 × 2 mm in size, occur occasionally.

Figure 30
Examining the nasopharynx with a finger

Epipharyngoscopy (see posterior rhinoscopy). A warmed nasopharyngeal speculum and a spatula are used for this purpose. The superior parts of the nasopharynx, the choanae, the lateral walls of the pharynx (where the openings of the auditory tubes can be seen at the level of the posterior ends of the conchae) are visible in the mirror. Normal choanae are empty; the mucosa of the superior regions of the pharynx is pink and smooth. The nasopharyngeal tonsil (III) can be seen in the vault of the pharynx. Normally it is lodged on the posterosuperior wall of the nasopharynx without reaching the superior edge of the vomer and the choanae.

Palpation of the nasopharynx. The physician stands behind and to the right of the seated patient (Fig. 30). The doctor's right index finger should swiftly pass behind the soft palate into the nasopharynx to feel the choanae, the vault of the nasopharynx, and the lateral walls. The cheek of a child should be pressed between the upper and lower jaws using the left index finger.

Hypopharyngoscopy. The lower portions of the pharynx should be inspected using indirect laryngoscopy with a warmed laryngeal speculum.

The tip of the tongue should be wrapped in a piece of gauze and held by the fingers of the left hand so that the thumb is on the superior and the middle finger on the inferior surfaces of the tongue, the index finger lifting the upper lip. The tongue is pulled slightly forward and downward. The laryngeal speculum should be held by its handle in the right hand and moved into the mouth without touching the root of the tongue and the posterior wall of the pharynx. The mirror surface should be directed downwards. As the uvula is reached, the mirror is turned through 45° and the soft palate with the uvula should be displaced by the speculum superiorly and posteriorly. The patient is asked to utter the sound 'ee' and gently breathe in (Fig. 31). Normally, the mucosa of the posterior walls is pink and smooth.

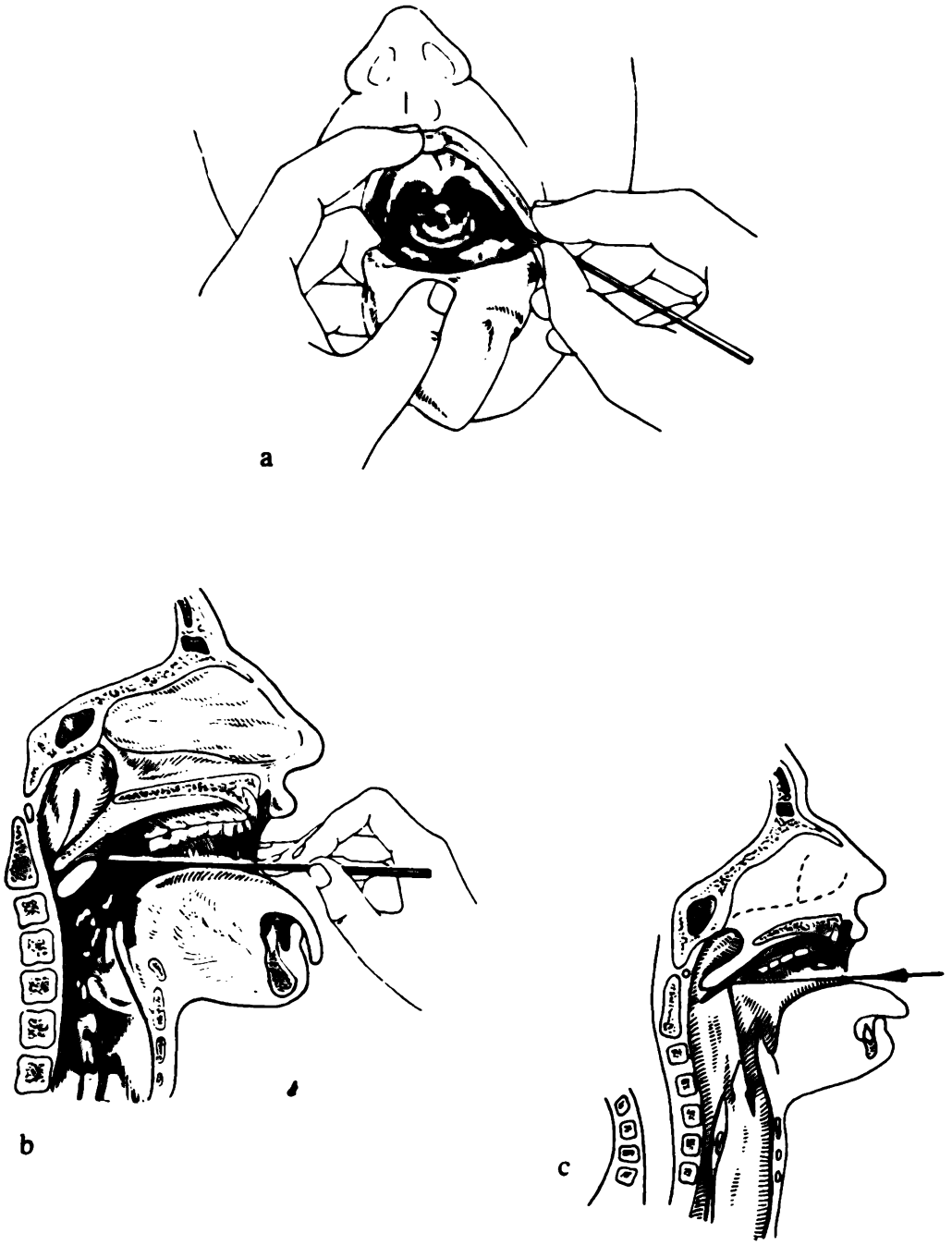

Figure 31
Indirect laryngo- and hypopharyngoscopy:

a – general view of the laryngopharynx;
b – position of the laryngeal speculum;
c – light path in mirror reflection

CLINICAL ANATOMY AND PHYSIOLOGY OF THE OESOPHAGUS

The oesophagus is continuous with the pharynx at the level of the inferior edge of the cricoid cartilage (the sixth cervical vertebra). This is a 24-25-cm long muscular tube with a shorter anteroposterior diameter. The oesophagus opens into the stomach at the eleventh thoracic vertebra, at the point where the 7th costal cartilage is attached to the sternum. In adults, the total length of the part of digestive tract from the incisor teeth through the mouth, the pharynx, and the oesophagus to the stomach is 40–42 cm. The oesophagus deviates from a straight line.

The fact that the oesophagus is tightly connected with the heart, the great vessels, the trachea, the bronchi, and the mediastinal pleura is clinically important.

The oesophagus has the following three anatomical narrowings: (1) the proximal end of the oesophagus, known as the mouth of the oesophagus; (2) the bronchial narrowing, at the level of the tracheal bifurcation; and (3) the diaphragmatic narrowing in the oesophageal opening of the diaphragm. These anatomical constrictions play an important role in the pathology of the oesophagus.

The cervical portion of the oesophagus is supplied with blood from the oesophageal arteries and from the inferior thyroid artery. The thoracic part of the oesophagus is supplied from the branches of the thoracic aorta; and the abdominal part, from the diaphragmatic artery and the left gastric artery.

The veins of the cervical portion of the oesophagus are emptied into the inferior thyroid veins; the blood from the veins of the thoracic part of the oesophagus drains into the hemiazygos and azygos veins, and the veins of the abdominal part into the branches of the portal vein.

The oesophagus is innervated by the branches of the vagus nerve and sympathetic nerves.

The main function of the oesophagus is to propel food actively into the stomach. At the moment of swallowing, the mouth of the oesophagus opens and food is propelled by the pharyngeal muscles into the proximal end of the oesophagus. The oesophageal muscles then contract peristaltically to move food further to the stomach.

EXAMINATION OF THE OESOPHAGUS

The oesophagus is examined for various pathological conditions, such as foreign bodies, diverticula, and cicatricial constrictions caused by burns, tumours, infectious granuloma, etc. Two objective methods of examination are now used: X-ray (rhoentgenoscopy and rhoentgenography) and endoscopy (oesophagoscopy).

The apparatuses used for oesophagoscopy are the same as those used for tracheobronchoscopy. Their designs are quite varied. Some of them can be used under local anaesthesia to the pharyngeal and oesophageal mucosa (Friedel, Brunnings systems), while others can be used only under general anaesthesia.

GENERAL THERAPY AND NURSING

The treatment of various pathological conditions of the pharynx includes measures aimed at preventing inflammatory complications and eliminating the disease. This can be attained by using medicinal preparations locally. The medicines can be administered by irrigation, inhalation, and insufflation. Cold and warm compresses are also used.

The throat should be gargled with 200-250 ml of a medicinal solution that should be prepared and warmed to 40-42°C by the nurse. The patient takes a small amount of the solution into his or her mouth; the head is tilted back and to the involved side, and, in this position, the patient gargles with the liquid. All of the solution (200-250 ml) should be used up in one gargling session. The number of sessions per day should be determined by the physician.

Inhalation of medicines should be carried out either in a special room of the policlinic or at home using portable inhalators. Mouthpieces should be disinfected before and after inhalation by boiling or by washing with alcohol. Medicinal solutions (e.g. Lugol's solution) should be applied using a long applicator that has cotton wool wound around one end. The nurse should squeeze out any excess solution from the cotton. The pharyngeal mucosa should be cauterized in a similar way. But the cotton tampon should be very thin and the amount of the solution used should be minimal.

A cold compress or an ice-bag can be applied at the initial stage of inflammation of the pharynx, or following surgery. The

patient should be placed on his or her side and an ice-bag (wrapped in a towel) applied to the submandibular area of the involved side (30-minute sessions should be followed by a 10-15-minute rest).

The nurse should be able to prepare and apply a warming compress to the patient's neck. An alcoholic solution (1:2) has the best therapeutic effect. The compress should be applied for 2-3 hours, 2-3 times per day.

Hospitalized patients with pathology of the pharynx require special care. If the first signs of tonsillitis appear, the patient should be isolated from others (in a special room or behind a screen). His glassware should not be used by other patients. The condition of the mouth cavity should be checked constantly. The body temperature should be taken at 3-hour intervals. The room should be well aired and a quartz lamp should be used to treat the air. The personnel who come in contact with the patient should wear a face mask and wash their hands with disinfecting solutions. Infectious patients should be isolated (in a special department) as soon as possible. If a person develops tonsillitis at home, he should not visit the doctor at the policlinic during the first 6 days in order to protect others from infection.

First aid in burns of the oesophagus includes drinking neutralizing substances such as fresh or sour milk (alkali burn) or sodium bicarbonate in small doses (acid burn). Vaseline oil and small lumps of ice should be given per os to the patient several times a day. In order to lessen pain, 1 ml of a 1-2 per cent promedol solution should be administered subcutaneously to adults. Salivation is decreased by subcutaneous injections of 0.5-1 ml of a 0.05 per cent solution of scopolamine hydrobromide or 1 ml of a 0.01 per cent atropine sulphate solution, once or twice a day. An isotonic sodium chloride solution (0.5-1 litre) is administered subcutaneously and 10-20 ml of a 40 per cent glucose solution is infused intravenously; nutrient solutions are given by enema.

The nurse must observe the patient's respiration because oedema of the pharynx and stenosis can develop. Diuresis should be monitored by measuring the amount of liquid taken in and excreted; the colour of the urine and the presence of sediment are also important for the diagnosis of possible renal dysfunction. The diet should be sparing.

INJURIES AND FOREIGN BODIES

Foreign bodies in the pharynx are encontered rather often. They can be of various type and shape: fish bones, metal objects, (pins, nails), pieces of wood, fruit peels, and the like. Large lumps of food or artificial dentures are also found in the pharynx.

Foreign bodies get into the pharynx as a result of careless eating, or talking and laughing during meals. Without adult supervision, children often try to swallow various objects. Dental prostheses impair the sensitivity of the mucosa of the hard and soft palate in the aged and therefore a foreign object can unnoticeably get into the pharynx.

Depending on the size and shape, foreign bodies can get in the lacunae of the palatine tonsils, and sometimes can penetrate the tissues, especially those of the tonsils, or between the palatine arch and the tonsil. Sometimes a foreign body can get stuck in the tubal elevation or in the region of the lingual tonsil, in the piriform recess, etc. Foreign bodies in the nasopharynx occur less frequently. They enter the nasopharynx from the nasal cavity or through the sinus (shot or cut wounds). Some foreign objects that are alive (e.g. leeches) can get into the pharynx during bathing or by drinking from stagnant water sources.

The *symptoms* depend on the properties of the foreign body, its size and shape, its location, and the depth to which the foreign body penetrates the tissue. As a rule, all foreign bodies cause piercing pain immediately upon penetration. Then swallowing becomes very painful. If a foreign body obstructs the entrance to the larynx, its lumen is narrowed causing asphyxia and coughing.

There may be no objective symptoms of a foreign body present in the nasopharynx, but as it remains there, bleeding and unpleasant odour can occur due to trophic ulcer that develops at later periods. A foreign body left in the pharynx for a long time usually causes inflammation of tissues at the site of penetration. Pharyngoscopy reveals hyperaemia and swelling in such cases; salivation is excessive.

Diagnosis is based on the patient's complaints and the anamnestic and examination findings. X-ray examination of the pharynx helps establish the exact location of the foreign body, especially if it is metallic. In order to reveal sharp foreign bodies inside the palatine or lingual tonsil, the suspected site should be pulpated. To prevent the vomiting reflex, the pharyngeal mucosa should

first be anaesthetized by irrigation using a 5 per cent cocaine solution and a common pulverizer. A spatula for direct laryngoscopy should be used during inspection of the laryngopharynx. Pain is often due to the injured mucosa rather than to the presence of a foreign object. In order to rule out the possible presence of a foregn body, it is not sufficient to inspect the patient only once; the patient's condition should be assessed every day and changes in the pharyngoscopic picture should be followed up throughout the first week.

Treatment. As a rule it is not difficult to remove a foreign body. The mucosa of the posterior wall should in some cases be anaesthetized to prevent the vomiting reflex. To do so, the root of the tongue and the piriform recesses are treated with a 5 per cent cocaine solution using a cotton applicator. The foreign body can be taken by laryngeal or nasopharyngeal forceps, or a similar instrument.

After removal of a foreign body, a wounded surface may remain which should be treated with a 5 per cent iodine tincture. The patient should gargle with a furacin solution (1 : 5000) or a dilute potassium permanganate solution. Hard food must not be taken for the next 5-7 days.

Wounds of the pharynx. Wounds of the pharynx are usually not dangerous because only the surface layer of its walls is injured without involvement of the surrounding tissues. Abrasions of the mucosa, surface wounds and punctures are among common wounds of the pharynx and they require only cauterization with silver nitrate solution. But some wounds of the pharyngeal walls can be dangerous and require treatment and primary suturing, e.g. in lacerations of the soft palate and the arches. Penetrating wounds of the pharynx should always be regarded as combined, and should be treated appropriately.

Symptoms depend on the location of the wound. The most severe symptoms immediately following the injury are bleeding, contusion, and respiratory distress. Bleeding can be external, intratissue or into the cavity. It can occur immediately following the injury or several days after the injury (secondary haemorrhage). If only small vessels are injured, bleeding is not dangerous, but if the carotid artery or its branches are injured, blood is rapidly lost and the patient may die. Blood can pass into the pharynx and the larynx interfering with normal respiration; coughing and tachypnoea then develop. Wounds penetrating the root of the tongue and the laryngopharynx can interfere with respiration and

speech. Haemorrhage into the cavity is dangerous because blood gets into the airways to induce respiratory distress (to asphyxia). Moreover, even small amounts of blood can cause aspiration pneumonia. Intratissue haemorrhage can compress the pharynx and the dependent airways. At later stages, intratissue haemorrhage (haematoma) may become infected to give abscesses and phlegmons. This in turn destroys the blood vessels and causes secondary haemorrhage.

Pharyngeal wounds are always associated with dysphagia (because the organ integrity is broken), penetration of food into the larynx, and pain in the wound whose walls are compressed and stretched during swallowing. Pain can, however, subside after a period of time and swallowing of the saliva and food becomes normal. Such cases are fraught with the danger of wound infection with subsequent separation of tissues and penetration of the infection in the paraoesophageal and mediastinal space.

During the first two days, before the wound edges are infiltrated, emphysema (accumulation of air in the tissues) can develop; it mostly occurs in laryngeal and tracheal wounds. Emphysema is diagnosed by swelling and crepitation of the tissues, first in the immediate vicinity of the wound; then air may descend along the interfascial spaces to the mediastinum. This condition can be diagnosed by X-ray. Emphysema facilitates spreading of the infection because it separates the tissues. Compression of the chest organs by the air can be so significant that their function can thus be upset.

Injuries to the pharynx can damage the pharyngeal nervous plexus and the upper portion of the vagus nerve, which is attended by paresis or paralysis of the soft palate on the involved side. Affection of the sublingual nerve is characterized by deviation of the tongue to the involved side (as the tongue is produced outside). Affection of the inferior laryngeal nerve or the vagus nerve is always associated with paralysis of the larynx on the involved side and hoarseness.

Wounds of the nasopharynx are rarely encountered. They are usually combined with wounds of the surrounding tissues and organs. The symptoms of nasopharyngeal wounds are nasal and pharyngeal bleedings, upset respiration through the nose due to obstruction of the nasal meatuses with blood clots and injured tissues, and impaired swallowing due to affection of the soft tissues and pain; speech becomes nasal (rhinolalia clausa). Radiation of pain into the ear suggests affection of the lateral walls

of the nasopharynx and the orifices of the auditory tubes. A blue colour of the eardrum indicates blood in the tympanic cavity (haematotympanum). Secondary diseases are likely to occur: otitis media, maxillary or sphenoid sinusitis, etc. Headache and pain when the head is moved develop soon after nasopharyngeal injury.

Treatment. Arrest of bleeding, restoration of the respiratory function, and antishock therapy are the emergency measures to be taken following wounds of the nasopharynx. If bleeding is profuse, the common carotid artery should be compressed below the wound (as a rule in the region of the anterior process of the sixth cervical vertebra). Posterior nasal tamponade should be performed, the wound inspected, and the injured blood vessels ligated if possible. If these measures fail, the external carotid artery should be ligated on the involved side, or on both sides, if necessary. The blood of the wounded patient should be examined to determine its group and Rh factor. Blood and biological fluids should be transfused. To prevent penetration of saliva and food into the wound, a gastric tube should be passed through the nose or mouth. Measures should be taken to ensure the drainage of saliva. The antitetanus serum should be administred according to the accepted method and antibiotics should be prescribed.

Wounds of the oropharynx and the laryngopharynx are relatively rare but more frequent than wounds of the nasopharynx. These wounds are similar to wounds of the nasopharynx. If a penetrating wound opens into the pharynx, the jugular vein is sometimes injured. This is dangerous not only because bleeding is profuse, but also because there is a danger of air embolism. Combined injuries to the oropharynx and the laryngopharynx are often associated with intertissue emphysema which quickly spreads in the presence of cough.

Treatment is aimed primarily at restoration of respiration and then arrest of bleeding. Tracheotomy is often required. In the presence of penetrating wounds, it is often necesarry to use a nasogastric tube to feed the patient. The antitetanus serum and antibacterial preparations are obligatorily administered in all cases.

Injuries to the oesophagus can be internal or external. External injuries rarely occur. These are abscesses of the lymph nodes opened into the oesophagus, or endophytic tumours. Gun-shot and incised wounds can combine with injuries to the pharynx and the

trachea. Internal injuries of the oesophagus are all cases where the mucosa is affected by foreign bodies, corrosive chemicals, or unskilled medical manipulations.

Combined wounds of the cervical portion of the oesophagus are dangerous because of the concomitant injuries to the large vessels, nerve trunks, vertebral column, and airways. Only in the absence of such concomitant injuries can the patient survive the trauma. A penetrating wound to the oesophagus often exhibits few symptoms. Difficult passage of food and pain during swallowing are noted when the entrance to the oesophagus is wounded. These symptoms are less pronounced if lower parts of the oesophagus are injured. Determining the direction of the wound and its depth (in the presence of the above-mentioned symptoms) can reveal the suspected injuries to the oesophageal wall. A communication between the wall defect and the wound is often revealed after swallowing a sterile stained fluid (furacin, ethacridine lactate, etc.). But if the defect is not gaping, or if it is displaced with respect to the wound canal, the swallowed liquid may not leak into the wound. In the absence of a wound and bleeding in the upper airways haematemesis suggests a wound of the oesophagus. X-ray examination reveals such a wound by the presence of air or a radiopaque substance in the space around the oesophagus. An oesophageal wound is often characterized by deep-seated pain over the jugular notch which radiates to the retrosternal space and the spine.

External injuries. These injuries often run a more severe course than internal injuries to the oesophagus because the saliva, food, or the vomitus can pass into the tissues around the oesophagus (i.e. into the mediastinum). A joining secondary infection can provoke severe inflammation that involves the organs of the chest and often causes death. The general condition of the patient is even more aggravated by the blood loss. Erosive bleeding can arise during disintegration of a tumour.

Symptoms depend on the character of the external wound. Like in penetrating wounds, neck wounds in the vicinity of the oesophagus can be asymptomatic in the acute period because the edges of the wound in the mucous membrane can quickly stick together. Only after several days, when the focus of inflammation is formed, will the wound manifest by local symptoms such as painful swallowing, difficult (or absence of) passage of food, or the appearance of saliva and food in the wound. Saliva and food in the wound below the cricoid cartilage level is a direct

indication of the presence of an oesophageal injury. Dysphagia is characteristic of all cases of such pathology.

Diagnosis is not difficult in the presence of the described symptoms. Simple and contrast roentgenography and, whenever necessary, oesophagoscopy are obligatory for a correct diagnosis of penetrating wounds of the oesophagus.

Treatment. The swallowing of food and saliva should first of all be avoided. Large doses of antibiotics, glucose (intravenously, with insulin), vitamins, blood, and protein solutions should be administered. The mouth cavity should regularly be cleaned. Food and liquid should be given per rectum and parenterally. The wound should be examined with a usual approach through the lateral pharyngotomy. A gastric tube can be passed into the oesophagus only several days after the trauma (under oesophagoscopy control). During this time the wound margins will thicken due to infiltration and oedema of the surrounding tissues. This will considerably decrease the danger of wound infection from the oesophagus. The gastric tube should be removed in 2 weeks and a diet of soft food is prescribed. In the presence of signs of cicatricial stricture of the oesophagus, bougienage should be carried out regularly.

Treatment is, as a rule, surgical: debridement and suturing of the wound and passing a tube into the stomach for feeding the patient.

The *prognosis* in external wounds of the oesophagus is bad but not hopeless. Infection of the mediastinum aggravates the prognosis.

Internal injuries. Foreign bodies and chemical burns are the most frequent causes of internal affections.

Foreign bodies usually get into the oesophagus with food. These can be fish and meat bones, dental prostheses, coins and other objects. Foreign bodies in the oesophagus occur mostly in adults. When a foreign body is embedded in the mucosa of the oesophagus or injures it, oesophagitis or perioesophagitis occurs due to secondary infection. Sometimes a foreign body (usually a bone) injures not only the mucosa but also the muscles of the oesophagus (perforating the oesophageal wall). A severe complication, mediastinitis, occurs in such cases. If a foreign body is smooth, it can pass freely to the lower portions of the alimentary tract without causing any damage to the oesophagus, or such a body can stop at a natural narrowing of the oesophagus.

Symptoms depend on the properties of the foreign body, the character of the injury, the duration of the disease, and the site of injury. Patients often experience pain when they turn

their head or move their neck; they feel discomfort and burning in the retrosternal space. Swallowing of food or saliva is painful; pain can radiate into the spine. The general reaction of the body (elevated temperature, changes in the blood or urine) is usually not pronounced during the first period of the disease.

Diagnosis is based on the anamnestic data, findings of indirect inferior pharyngoscopy and roentgenography (contrast X-ray included.) If a foreign body cannot be visualized by X-ray while clinical observations indicate its possible presence, oesophagoscopy is necessary to establish the presence or absence of pathology. Medical manipulations in the oesophagus are also aided by oesophagoscopy.

Treatment. Foreign bodies in the oesophagus are removed during oesophagoscopy under X-ray control (before and after the removal). In children oesophagoscopy should be performed under intubation endotracheal anaesthesia. Local anaesthesia is sufficient for adults. When oesophagoscopy cannot be carried out under local anaesthesia, it should be done under endotracheal anaesthesia. It is prohibited to push foreign objects farther down the oesophagus without visual control. Swallowing a bread crust for the same purpose is inadmissible.

After the foreign body is removed and the mucosa of the oesophagus is found to be injured, the patient should be given soft food only. Anti-inflammatory and desensitizing therapy is prescribed. If the oesophagus is perforated (or its perforation is suspected), feeding by mouth is prohibited. Antibacterial and general anti-inflammatory treatment is necessary. Food should be given parenterally and per rectum. The patient should be treated by a thoracic surgeon.

Prognosis is good in the absence of complications.

Burns of the pharynx and the oesophagus can be thermal, chemical, electrical and those induced by radiation. Thermal burns of the mouth, pharynx and the oesophagus occur mainly during swallowing of hot food (usually liquid). Inhalation of hot air, gas or vapour can also cause thermal burns. Chemical burns of the pharynx and the oesophagus are usually more severe. Corrosive liquids (strong acids or alkalies) ingested by mistake or intentionally (a suicidal attempt) cause severe burns of the pharynx and the oesophagus. Among commonly ingested poisons is concentrated acetic acid. Less frequently ingested are caustic soda, spirit of ammonia, concentrated sulphuric, nitric, hydrochloric, chromic and other acids.

If a large amount of a concentrated poison is ingested, the patient usually dies in several days because of intoxication and affection of the parenchymatous organs, and perforation of the stomach or the oesophagus, and due to deep necrosis of the walls of these organs. Three clinical degrees of pathological changes in the affected tissues in thermal and chemical burns are distinguished: degree I–erythema; degree II–blistering; and degree III–necrosis.

Weak acids or alkalies and slight thermal effect cause usually catarrhal inflammation (erythema) of the pharyngeal and oesophageal mucosa; this affection usually ends in complete recovery without leaving any cicatrices. If the muscle layer of the pharynx or oesophagus is necrotized, deep scars occur throughout the entire thickness of the organ wall. Elasticity and distensibility of the oesophageal and pharyngeal walls decrease considerably. Severe tubular stenosis occurs in such cases.

Complications of oesophageal burns are oedema of the larynx, tracheobronchitis, perioesophagitis, oesophagotracheal fistula, pneumonia, sepsis, and cachexia. First- and second-degree burns in children cause extensive reactive processes in the form of oedema of the pharynx and the larynx and hypersecretion of sputum, which seriously impair respiration because of stenosis in the pharynx and the larynx.

Treatment should begin as soon as possible (see the Table). In chemical burns, the poisonous substance should be neutralized during the first 6 hours. If the poison is an alkali, the patient should be given a weak solution of acetic, tartaric, or citric acid. If it is an acid, a solution of sodium hydrocarbonate, magnesia or chalk should be given. If the antidotes are not available, warm boiled water should be given, adding half of the volume of milk or egg white. If a gastric tube cannot be passed into the stomach, the patient should drink 5-6 glasses of washing liquid and then the tongue root should be pressed down with the fingers or a spatula to induce vomiting. The stomach should be lavaged several times with 3-4 litres of liquid.

In thermal burns, the affected surface should be treated with a 5 per cent potassium permanganate solution and a pink $KMnO_4$ solution should be used for gargling.

In addition, antishock and detoxicating measures should be taken in cases of second- and third-degree burns. Pantopon or morphine should be injected subcutaneously. A 5 per cent glucose solution, haemodez, blood plasma and fresh erythrocytes

First Aid and Stage-by-stage Complex Treatment in Chemical Burns of the Oesophagus

First aid at home or in hospital	Treatment during first 24 hours	Treatment during first week
1. 1% morphine or pantopon (papaverine) solution, or 2% promedol solution subcutaneously (1 ml to adults, 0.1 ml/year to children aged over 2). 2. Cardiotonics: 10% caffeine solution, 2 ml (0.1 to 0.75 ml to children); 20% camphor solution subcutaneously; mesaton, slowly intravenously (0.1-0.3 ml of 1% solution). 3. Oral administration of 1% novocain solution (1 tablespoonful) or intranasal instillation of 1% dicaine solution (2-5 drops), followed by lavage of the stomach through a gastric or duodenal tube, preferably with a neutralizing solution, e.g. magnesium oxide solution (20 g per 2 l of water) for acid burns, or 0.1% citric or hydrochloric acid for alkali burns – 4-5 l irrespective of the patient's condition. 4. The first dose of steroids (maximum therapeutic dose for a given age) parenterally.	1. Corticosteroids, antibiotics, 0.5% novocain solution per os (1 tablespoonful 3 times a day), vitamins C, B_1, B_{12}, cocarboxylase (parenterally) to all patients. 2. If the burn is deep and intoxication is marked, hydrocortisone or prednisolone intravenously (100-150 mg in 100 ml of 5% glucose solution). Slow injection: 0.2% norepinephrine by intravenous drip (2 ml in 500 ml of 5% glucose solution warmed to 36 °C); neocompensan (haemodez), intravenous drip (300-500 ml; 5-10 g/kg for children). In the presence of dehydration, if swallowing is very difficult or the patient refuses drinks, 1.5-3 l of 5% glucose solution and isotonic sodium chloride solution should be administered by intravenous or subcutaneous drip. 3. In the presence of severe pain, anaesthesine (0.25-0.5 g) should be given 3 times a day, vagosympathetic blockade.	1. Steroids, antibiotics and vitamins should be continued; analgesics and cardiotonics when indicated. Spasmolytics and ganglioblockers: Nospa (1-2 tablets 3 times a day). If the patient is unable to swallow, the preparation should be administered parenterally. 1% methacyne or atropine solution subcutaneously. During 2 weeks, 25% magnesium oxide solution intramuscularly (10 ml to adults, 0.2 ml to children). If large doses of steroids are given, 10% potassium chloride (1 dessert spoonful 3 times a day) should be given per os. Dietary restrictions during the first 3-5 days. Later diet limitations are unnecessary.

Table concluded

First aid at home or in hospital	Treatment during first 24 hours	Treatment during first week
	4. In the presence of signs of threatening lung oedema, blood-letting (150-200 ml) is indicated; 0.05% strophanthine solution intravenously (0.25-0.75 ml in 10 ml of 40% glucose solution). Inhalation of humidified oxygen. 5. In acid burns, it is necessary to administer intravenously 4% sodium bicarbonate solution (100-300 ml). In the presence of persistent anuria, paranephric block is necessary. 6. Replacement blood transfusion may be necessary for severe intoxication. 7. Diet: milk, apple puree with equal quantities of honey, eggs, and sweet or sour cream.	

should be infused intravenously. Cardiac and antibacterial preparations should also be given. If the patient can swallow, a sparing diet and much liquid should be prescribed. If the patient is unable to swallow, parenteral and rectal nutrition is indicated.

Oedema of the larynx is an indication for elimination of stenosis with diprazine, prednisolone, and calcium chloride. Severe stenosis occurs in some cases and tracheostomy is then required. Antibiotics should preferably be administered during the entire course of ulcer healing (1-2 months).

Early bougienage or introduction of a tube into the oesophagus for a long time is the most common method to prevent cicatricial stenosis of the oesophagus during the recovery period. Steroids, biogenic stimulants, and resolving therapy are helpful to prevent excess granulation and scarring.

HYPERTROPHY OF LYMPHOID TISSUE OF THE PHARYNX

The volume of lymphoid tissue of the pharynx can vary significantly depending on its functional activity. But hypertrophy of the pharyngeal lymphoid tissue can sometimes be persistent. Hypertrophy may be so significant that respiration not only through the nose but also through the mouth becomes difficult; food is swallowed with difficulty and speech is impaired. The function of the auditory tubes is affected as well. In the overwhelming majority of cases, the palatine tonsils are hypertrophied significantly only before the onset of sexual maturation. Less frequently they are enlarged in persons aged under 30 and rarely in persons aged over 30.

Hypertrophy of the pharyngeal tonsil (adenoids). Adenoids usually grow at the age from 3 to 15, but they also occur in younger patients and in adults.

Adenoids are lodged in the posterior part of the nasopharyngeal vault, but they can also grow over its entire dome and involve the lateral walls, downwards to the pharyngeal openings of the auditory tubes. They are usually attached to the underlying tissue by their wider base. Adenoids are irregular rounded formations divided by a deep cleft along the median sagittal line. Each half is, in turn, divided into two or three lobes.

The main *symptoms* of adenoids are upset respiration through the nose, constant serous nasal discharge, dysfunction of the auditory tubes, and recurrent inflammation of the nasopharynx and the nasal cavity.

Three degrees of adenoid growth are distinguished: degree I–adenoids cover to one third of the vomer; degree II–about half of the vomer is covered; degree III–the vomer is covered to two thirds or almost completely. Degree I adenoids do not impair significantly respiration through the nose in a wake child, but during sleep the volume of the adenoids is enlarged due to increased filling of the veins. Therefore, if it has been established

Figure 32
A child with adenoid growth (adenoid facies)

anamnestically that a sleeping child breathes through the mouth, the presence of adenoids is possible.

If a child is ill for a long time, the face bones become distorted: the dropping jaw becomes narrow and long, while the hard palate undergoes malformations: it becomes high and narrow; incorrectly growing teeth cause malocclusion. These changes give a specific dull expression to the face of children with adenoid growths (adenoid facies; Fig. 32).

Children with hypertrophy of the pharyngeal tonsil can develop pigeon chest. Anaemia also possible. The size of the blind spot on the fundus of the eye can increase. Children with adenoids are usually flaccid; they are absent-minded, their advance at school is slow; they often complain of headache.

Palpation and if necessary X-ray examination of the nasopharynx confirm the diagnosis.

Treatment of adenoids is commonly surgical. Conservative treatment is helpful only if hypertrophy is insignificant or there are contraindications for the operation. Climatotherapy (highland and marine climate) is effective. Antihistaminics and calcium gluconate help in some cases.

The surgical removal of the adenoids (adenoidectomy) is performed in cases where the enlarged tonsil impedes respiration through the nose. The operation is usually performed at the age from 5 to 7, but infants and adults can also be operated on if nasal breathing is pathologically impeded, the hearing function is impaired, or other diseases concur. Children can be operated under out-patient conditions, while adults only in hospital. Children should fast

on the eve of the operation; should not take breakfast on the day of the operation. They may only drink a cup of tea $2^1/_2$ hours before the operation. The operation can be performed either without anaesthesia, or after instilling 5 drops of a 1 per cent dicaine or a 5 per cent cocaine solution into each side of the nose. Contraindications for adenoidectomy are diseases of the blood, severe diseases of the cardiovascular system, and infectious diseases (the patient may be operated on only in 1-2 months after the disease); in the presence of a dangerous epidemiological conditions (influenza, measles, etc.) the operation should be postponed. An important pre-operative measure is immobilization of the child. The nurse sits on a stool or in a surgical chair facing the surgeon and holds the child in her laps so that his legs are fixed between the nurse's knees; the right arm is used to hold the child's arms and the trunk, while the left arm holds the child's head. A sterile cloth should cover both the nurse and the child (Figs 33 and 34).

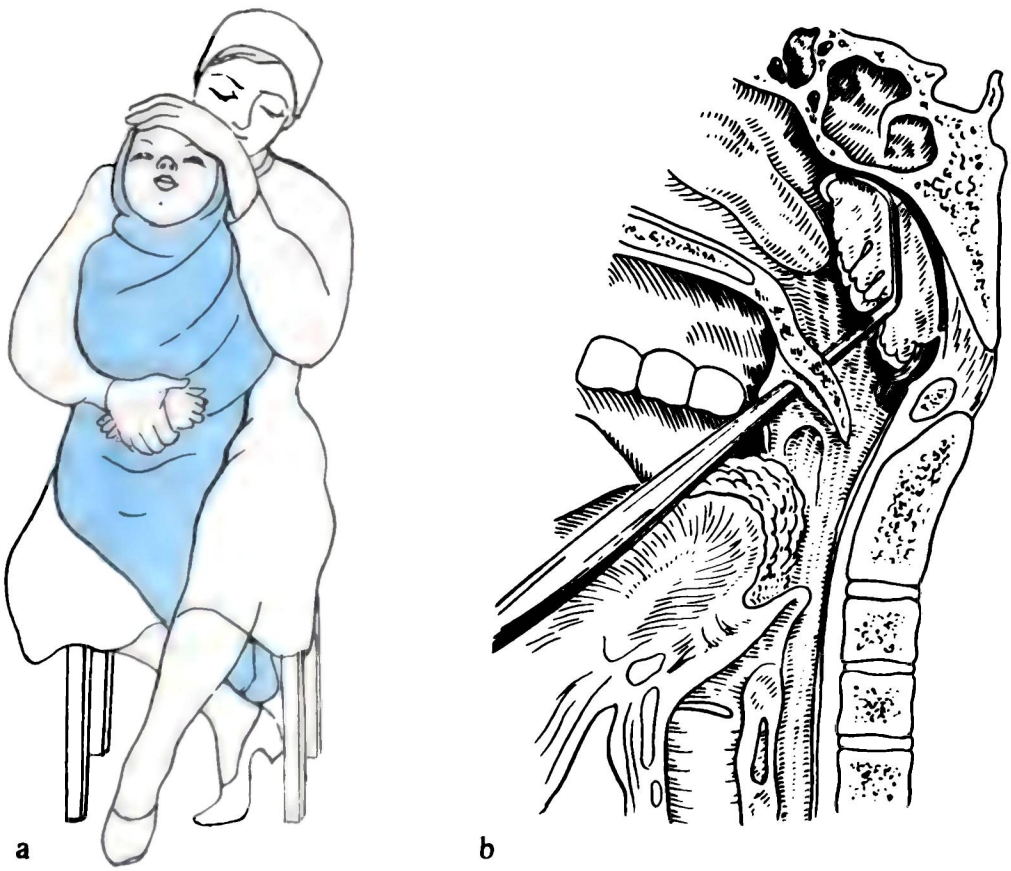

Figure 33
Adenoidectomy:

a immobilizing a baby for adenoidectomy; *b* removal of a pharyngeal tonsil

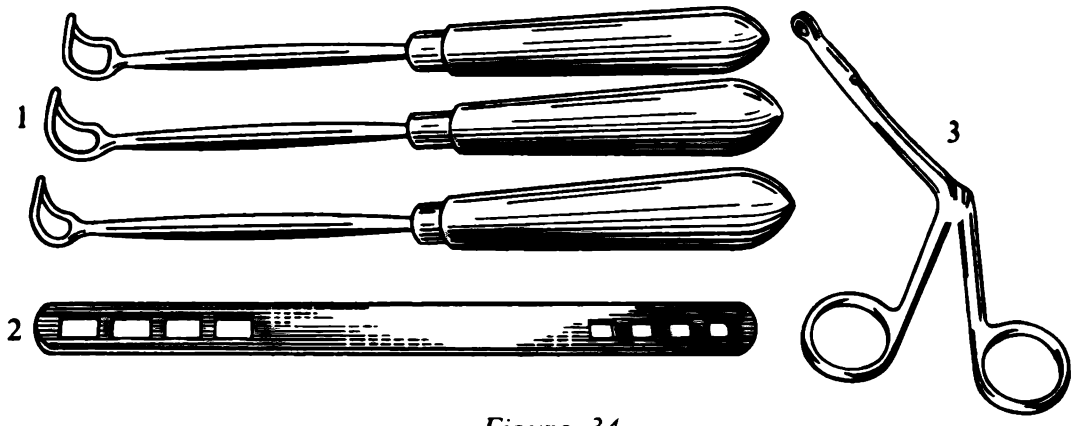

Figure 34
Adenoidectomy tools:
1 – adenotomes; *2* – spatula; *3* – fenestrated forceps

The operated child is placed on his side in bed on a low pillow for 25-30 minutes. Ice or ice-cream should be given to swallow in small portions. Local cooling helps to arrest bleeding. In two hours the patient can take cool liquid food. Hot or spicy foods should not be given, since bleeding can resume. This diet should continue for 4-5 days. Physical strain, active movements and chilling should be avoided.

Hypertrophy of the palatine tonsils occurs mostly in children. It often concurs with adenoids, which is a manifestation of the general hyperplasia of the lymphoid tissue.

Hypertrophied tonsils (Fig. 35) can interfere with normal respiration through the mouth, speech, and swallowing of food. If hypertrophy of the palatine tonsils concurs with adenoids, the respiratory function is severely upset. The child suffers from paroxysmal asphyxia during sleep, he is tortured by cough and

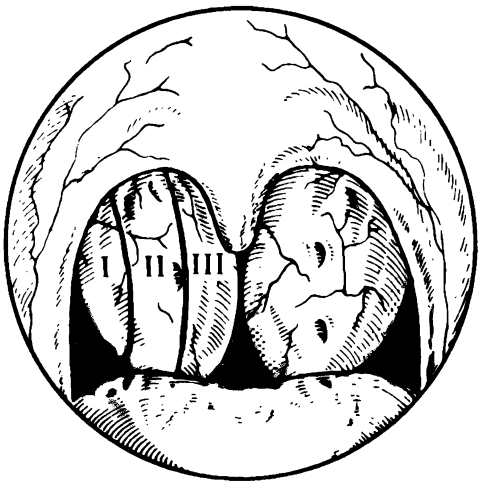

Figure 35
Degrees of tonsillar enlargement

frequently wakes up during sleep. These factors cause neurasthenia and other disorders.

Diagnosis is made during pharyngoscopy. Simple hypertrophy of the palatine tonsils should be differentiated from chronic hypertrophic tonsillitis which is characterized by recurring acute tonsillitis in the anamnesis and pharyngoscopic signs of chronic inflammation. The palatine tonsils are enlarged significantly in lymphosarcoma (one tonsil is commonly involved), leukaemia, and lymphogranulomatosis.

Treatment of pronounced forms of the disease is surgical. The tonsils are partly removed (the parts protruding beyond the palatine arches are excised). The pre- and postoperative treatment is the same as in adenoidectomy. If hypertrophy is insignificant, it can be left without treatment, except that astringent and cauterizing preparations are used to diminish the swelling; a 0.5 per cent sodium bicarbonate solution or a tannin solution (1:1000) is used for gargling; Lugol's solution or a 3-5 per cent silver nitrate solution is used to smear the tonsils.

Warm marine or highland climate is indicated. Contraindications for the operation are acute and severe chronic infectious diseases and diseases of the blood; threatening epidemiological conditions are also a contraindication. As a rule, children aged 5 to 7 are tonsillectomized (under out-patient conditions); infants are operated in rare cases; in adults the operation is performed in exceptional cases.

INFLAMMATION OF THE PHARYNX

Acute inflammation of the nasopharynx. Acute rhinopharyngitis is in most cases secondary to inflammation of the inferior portion of the pharynx and the nasal cavity which is associated with acute or exacerbated chronic pharyngitis, rhinitis or sinusitis.

The aetiological factors of acute rhinopharyngitis are the same as of acute rhinitis. The disease is common in infants and children, especially in the presence of adenoid growths in asthenic children with various forms of diathesis. Children's acute infections (measles, scarlet fever, etc.) often promote the onset of acute nasopharyngitis. Various cocci, e.g. streptococci, staphylococci, diplococci, pneumococci, and other microflora found in the nasopharynx in a non-pathogenic form, are the causative factors of the disease.

Symptoms include discomfort in the nasopharynx (burning,

dryness, tickling), accumulation of mucous secretion which is sometimes stained with blood and drains with difficulty from the nasopharynx. Headache and pain in the occipital region are frequent. Respiration through the nose is impeded; the voice becomes nasal, especially in children. If the inflammation extends to the mucosa of the auditory tubes, the patient complains of clicking and pain in the ears, and impaired hearing (defective conduction).

Nasopharyngitis in adults is usually apyretic, while in children the body temperature can significantly rise, especially if the inflammation extends to the larynx and the trachea, as in acute respiratory infection.

Acute non-specific rhinopharyngitis differs from diphtheria by the absence of fibrinous exudate. In dubious cases, the discharge should be tested for *Corynebacterium diphtheriae*. The disease lasts from a few days to two weeks.

Treatment is the same as in acute rhinitis. Instillation of a 2 per cent (5 per cent for adults) solution of protein silver or colloid silver, 5 drops 3 times a day into each nostril, is effective. If inflammation is marked, a 0.25 per cent silver nitrate solution should be instilled into the nose for a few days; this should be followed by instillation of vasoconstrictors. Acetylsalicylic acid and antibacterial preparations are recommended for elevated temperature. Vitamins and physiotherapy (UV rays on the soles and also UHF on the nose) are indicated.

Acute inflammation of the oropharynx. Acute inflammation of the middle portion of the pharynx alone occurs in rare cases. More frequently it occurs as a descending acute inflammation from the nasal cavity and the nasopharynx, or in combination with inflammation of the mouth cavity and the tonsils (Plate IV).

Symptoms of the disease are dry and sore throat, and hyperaemic mucosa. Pain intensifies and can radiate to the ear when the swallowing act is imitated. A mucopurulent discharge can be seen on the posterior wall of the pharynx. Hyperaemia and swelling extend from the posterior wall of the pharynx onto the posterior palatine arches and the uvula. Marked forms of acute pharyngitis are associated with regional lymphadenitis and elevated temperature (in children). Complications of acute pharyngitis are the same as in rhinopharyngitis. The disease lasts up to two weeks.

Treatment. Coarse or irritating food should be excluded. Inhalations and spraying of warm alkaline and antibacterial solutions are prescribed. In the presence of elevated temperature, anti-

bacterial preparations and acetylsalicylic acid are indicated per os. The disease has the tendency to convert into its chronic form. The acute inflammation should therefore be thoroughly treated.

Chronic pharyngitis. The disease is classified as chronic catarrhal, hypertrophic (granular and lateral) and chronic atrophic pharyngitis.

Chronic pharyngitis is a common disease of the pharynx. It occurs in children mostly in its simple and hypertrophic forms. Middle-aged and aged persons often develop chronic pharyngitis. The incidence is higher in men (the hypertrophic form), while in women it occurs mostly in the atrophic form.

The aetiology of chronic pharyngitis is determined in most cases by local irritation of the pharyngeal mucosa, which is usually persistent. The hypertrophic form of pharyngitis is characterized by thickening and oedematous loosening of the connective-tissue stroma of the mucosa proper and of the submucous layer. Serous exudate which fills the mucosa is gradually organized and replaced by cell elements. The mucosa becomes thicker and firmer. The lymphoid granules that are hardly seen on normal mucosa thicken and broaden significantly and often fuse into larger formations. Hypertrophy affects mostly the mucosa of the posterior wall of the pharynx (granular pharyngitis) or the lateral parts of the pharynx (lateral hypertrophic pharyngitis).

In atrophic chronic pharyngitis the mucosa is thin; its lymphoid tissue and the submucous layer are partly replaced by connective tissue. The number of mucous glands and their size descrease. The number of vessels decreases too. The walls of the vessels are often thick while their lumen narrow; the vessels are sometimes obliterated. The mucosa is covered with epithelium which is mostly keratinized and desquamated at places.

The *symptoms of the simple and hypertrophic forms of catarrhal pharyngitis* are sore throat and tickling in the throat, which provokes slight hacking coughing with expectoration and swallowing of the accumulated discharge, especially in the morning. These symptoms are more pronounced in hypertrophic pharyngitis. The patient sometimes complains of stuffed ears (the symptom subsides after several swallowing movements). The *main complaint in atrophic pharyngitis* is dry throat, especially during long conversation, difficult swallowing, especially during imitation of the swallowing act, and unpleasant breath. It should be noted that the complaints often do not agree with the objective pharyngoscopic picture: no complaints while the changes in the pharyngeal

mucosa are significant, and vice versa, complaints may be numerous in the presence of only slight objective changes in the throat.

Simple chronic catarrhal pharyngitis is characterized pharyngoscopically by hyperaemia, mild oedema and thickening of the pharyngeal mucosa, the presence of clear or cloudy mucus on the posterior wall of the pharynx.

Treatment should first of all be directed at elimination of the general and local causes of the disease (chronic purulent foci in the nose and the paranasal sinuses, in the tonsils, etc.). Possible irritating factors such as smoking, exposure to dust or harmful gases, inhalation of polluted air, spicy foods and others should be eliminated. Systemic chronic diseases that promote the development of pharyngitis should be treated properly.

Local treatment includes removal of mucus and crusts by irrigating the pharyngeal mucosa. Inhalation of medicinal aerosols, surface application and instillation of drops into the nose are also prescribed.

Hypertrophic forms of pharyngitis should be treated by gargling the throat with a 0.5-2 per cent warm solution of sodium hydrocarbonate and a 1 per cent sodium chloride solution. These solutions are also helpful when inhaled in the atomized form. Application of a 5-10 per cent tannin emulsion in glycerol, 1-2 per cent silver nitrate solution, 3-5 per cent (sometimes 10 per cent) solution of protein silver or colloid silver lessens oedema of the pharyngeal mucosa. Gargling with tea or sage (*Salvia officinalis*) decoction is also recommended. Large granules should be better removed by using extreme cold; cauterization of these lymphoid formations with a concentrated (30-40 per cent) silver nitrate solution (or with the solid substance) is also recommended. Ultrasound (phonophoresis) also produces a good therapeutic effect on the pharyngeal mucosa.

Treatment of atrophic pharyngitis includes daily irrigation of the pharynx to remove the mucopurulent discharge and crusts from its surface. An isotonic or a 1 per cent sodium chloride solution containing 4-5 drops of a 10 per cent iodine tincture per 200 ml of the liquid should be used for the purpose. Regular and prolonged irrigation of the pharynx with this solution removes irritation of the mucosa, and alleviates the unpleasant symptoms of pharyngitis. The posterior wall of the pharynx should be treated with Lugol's solution (with glycerol). Ten-day courses should be repeated at intervals. The composition of the solution is as follows: iodine tincture 0.1 g; potassium iodide, 0.2 g; glycerol 10.0 ml. The posterior

pharyngeal wall should be treated once a day. A 30 per cent potassium iodide solution is prescribed: 8 drops 3 times a day per os; a 3 per cent sodium iodide solution should be injected subcutaneously (10-15 injections for a course of treatment). The patient should first be tested for sensitivity to iodine. Concentrated vitamin A should be given per os, 2 drops 2 times a day for 2 weeks.

Pronounced symptoms of chronic pharyngitis such as paraesthesia, burning, dryness, etc. can be removed with novocain block into the lateral parts of the posterior wall of the pharynx; novocain block is often combined with aloe injections.

Among the hypertrophic forms of pharyngitis is *hyperkeratosis of the tonsils* (pharyngomycosis), in which the surface of the lymphoid tissue of the pharynx is covered with white-yellowish pyramid-like formations of keratinized epithelium; the size of such formations is 2 mm, and in rare cases 3 mm. They are firmly attached to the underlying tissue and leave bleeding erosions when detached. They may be found on an intact surface of the tonsils, the tubal elevations and the granules of the posterior wall of the nasopharynx, and on the tongue papillae. The epithelial formations contain *Leptotrichia buccalis*, a natural inhabitant of the oral cavity in man; it is believed to be of aetiological importance. Hyperkeratosis is treated with sulpha drugs; tonsillectomy is indicated in severe cases.

INFLAMMATION OF THE TONSILS

Acute tonsillitis is a general infectious disease in which the lymphoid tissue of the tonsils is affected by inflammation. In most cases the palatine tonsils are affected, while the other tonsils are involved less frequently. Acute tonsillitis is classified by its aetiology, pathogenesis and the clinical course.

When treating acute tonsillitis it is important to remember that various complications such as rheumatic fever, non-specific infectious polyarthritis, nephritis and some other diseases can occur. Acute tonsillitis can also aggravate the course of these and other systemic diseases. It can convert into its chronic form characterized by frequent exacerbations.

Aetiology and pathogenesis. Among many microbes that can provoke acute tonsillitis (cocci, bacilli, viruses, spirochetae, fungi, etc.) the leading aetiological role belongs to beta-haemolytic

streptococcus of group A. *Staphylococcus aureus* is another common causative agent of acute tonsillitis; it often prevails during acute tonsillitis in children with rheumatism. Outbreaks of acute tonsillitis of the alimentary aetiology caused by *Streptococcus viridans* have been reported. Virological and clinical studies have shown that adenoviruses can also cause various forms of tonsillitis, which cannot be differentiated pharyngoscopically from the microbial forms of the disease.

The exogenic factor attacks the tonsillar mucosa via airborne and alimentary route, and also by direct contact. But commonly the disease develops due to auto-infection with microbes or viruses that vegetate on the normal pharyngeal mucosa. The exogenic source of infection is not only an acute tonsillitis patient but also carriers of the virulent infection.

Three main forms of the development of common acute tonsillitis are distinguished: (1) ocassional acute tonsillitis manifested as auto-infection due to impaired environmental conditions, often as a result of chilling; (2) epidemic form arising as a result of infection from a tonsillitis patient; (3) exacerbation of chronic tonsillitis.

Acute tonsillitis is usually an exacerbation of chronic disease.

There exist many *classifications* of acute tonsillitis which are based on various principles, e.g. clinical, morphological, pathophysiological, aetiological, etc. The commonly used classification includes the following forms: I–catarrhal; II–follicular; III–lacunar; IV–fibrinous; V–herpetic; VI–phlegmonous (intratonsillar abscess); VII–necrotic (gangrenous); and VIII–mixed forms.

The pathological changes occurring in acute tonsillitis are characterized by pronounced dilatation of small blood and lymphatic vessels in the parenchyma of the tonsil, thrombosis of small veins, and stasis in the lymphatic capillaries.

Clinical forms. Common (trivial) acute tonsillitis due to infection with a microbe or a virus is the usual form among the great variety of the disease. The disease is commonly diagnosed by the pharyngoscopic signs. Catarrhal, lacunar, follicular, fibrinous and phlegmonous (intratonsillar abscess) tonsillites are thus diagnosed.

Acute catarrhal tonsillitis. The onset is acute and is marked by dryness, burning and tickling in the throat; then swallowing becomes slightly painful. The patient complains of general indisposition, fatigue, and headache. The body temperature is usually subfebrile; insignificant inflammatory changes in the peripheral

blood are found. Pharyngoscopy reveals diffuse hypertrophy of the tonsils and the margins of the palatine arches; the tonsils are somewhat enlarged and at sites coated with a thin mucopurulent film. The tongue is dry and coated. The regional lymph nodes are often slightly enlarged. The clinical signs are more pronounced in children than in adults. The disease usually lasts 3-5 days.

Follicular tonsillitis. The prodromal period is short, usually only a few hours, and in rare cases some days. The disease usually begins with elevation of temperature to 38-39° C, but it can also be subfebrile. The patient feels strong pain during swallowing from the very beginning of the disease. The pain radiates into the ear; salivation is often increased. More severe symptoms can develop in children: febrile temperature is often associated with vomiting; signs of meningism develop; consciousness is dimmed. The changes in the blood are often pronounced: neutrophilic leucocytes count from 12 000 to 15 000; moderate shift to the left and eosinophilia are observed; ESR is often 30-40 mm/h; traces of protein are found in the urine. As a rule, the regional lymph nodes are enlarged; their palpation is painful; the spleen is enlarged. Appetite is poor; diarrhoea is not infrequent in infants.

Pharyngoscopy reveals diffuse hyperaemia and infiltration of the soft palate and the arches; the tonsils are hyperaemic and enlarged, with numerous yellowish or yellowish-white spots (1-3 mm) elevated over the surface. These formations are suppurating follicles. The disease lasts 5-7 days.

Lacunar tonsillitis. The onset of the disease and its general symptoms are the same as in follicular tonsillitis. Lacunar tonsillitis usually runs a more severe course than follicular. Pharyngoscopic picture is characterized by enlargement of hyperaemic tonsils which are covered with islets of yellowish coat, first in lacunar orifices and then over the entire surface of the tonsils. The disease lasts 5-7 days, but can run a longer course in the presence of complications.

Fibrinous (fibrinomembranous) tonsillitis. Follicular or lacunar tonsillitis can sometimes develop like fibrinous tonsillitis when a membrane is formed from the ruptured purulent follicles. The fibrinous membrane spreads over onto the sites of necrotized epithelium in the lacunar orifices; it fuses with the adjacent sites of affection to form a confluent patch which can extend beyond the boundaries of the tonsils. Fibrinous tonsillitis sometimes develops from the very first hours of the disease. Other names of this disease are pseudodiphtheritic, pseudomembranous, and diph-

theroid tonsillitis. These synonyms indicate that despite the outer resemblance this disease is not diphtheritic. Differential diagnosis of such cases is based only on bacteriological studies of smears from various parts of the pharynx, mouth and the nose.

Treatment. Rational treatment includes sparing conditions, local and general therapy. The patient must remain in bed during the first days of the disease and then abstain from physical work which is very important not only for the treatment of the disease proper but also for prevention of possible complications. The patient should be separated from the others; he should use separate dishes and other objects. Children are quite susceptible to this disease and they should not therefore be admitted to the sick. In very severe cases the patient should be hospitalized. Food should be nutritious, rich in vitamins, soft, and not irritating; milk and vegetables should be preferred. After the local and general symptoms of acute tonsillitis have subsided, the patient is allowed 2 or 3 days of rest before he is admitted to his routine work. The patient should be recommended to avoid physical strain during several days afterwards.

Treatment includes also gargling with a warm solution of sodium chloride or hydrocarbonate (1 teaspoonful of sodium chloride or hydrocarbonate per 200 ml of water), furacin, potassium permanganate, hydrogen peroxide, calendula or camomile tea. A warming compress should be applied to the neck. Salicylates and antibacterial preparations should be used for general treatment.

The choice of antibacterial preparations depends on the gravity of the disease and the danger of complications. After testing the patient for sensitivity to penicillin, it should be administered in a dose of 1 500 000-2 500 000 U/day depending on age. The antibiotic is administered usually for 5 days, which is, as a rule, sufficient to normalize body temperature and to improve the patient's condition. Penicillin injections should not however be suspended because the pathology in the tonsils has not yet been extinguished by that time. In order to eliminate reliably the infectious focus, it is necessary to continue the penicillin therapy for another 3-5 days, or it is better to replace common penicillin by bicillin. If the patient is sensitive to penicillin, broad-spectrum antibiotics such as tetracyclin, ceporin, oleandomycin, or erythromycin should be given in appropriate doses. Neomycin, streptomycin and other ototoxic preparations are contraindicated. If injections are infeasible for some reasons, the preparations can be given per os: phenoxymethylpenicillin 50 mg 5 times a day for 10 days to adults;

children are given this preparation in doses calculated per kg body weight. Nystatin is given to patients to prevent candidiasis. If the course of acute tonsillitis is not aggravated by any factors, sulpha drugs are used instead of antibiotics (sulphadimezine, streptocid, and other sulpha drugs). The drugs should be given in doses of 1 g 4 times a day. Antibiotics can be given per os. Desensitizing preparations such as promedol, chloropyramine, diazoline, etc. are recommended.

Acute tonsillitis in children sometimes begins with convulsions. Measures should be taken to lower the body temperature by giving antibiotics, acetylsalicylic acid, chloral hydrate (enema), and by wet pack. Toxaemia is severe, and it is therefore necessary to monitor the cardiovascular and respiratory functions.

Phlegmonous tonsillitis. Intratonsillar abscess is a rare disease. It is associated with purulent destruction of a part of the tonsil. One side is usually involved. The aetiological role in the onset of the phlegmonous tonsillitis belongs to trivial tonsillitis and injuries caused by food or foreign bodies.

The affected tonsil is hyperaemic and enlarged. Its surface is tense; palpation is painful. Minor intratonsillar abscesses can run a symptomless course or be associated with insignificant local and general symptoms, as distinct from the peritonsillar abscess, which as a rule is characterized by intense clinical symptoms.

Treatment includes opening of the abscess. Unilateral tonsillectomy is indicated for recurrent affections. True abscess of the tonsil should be differentiated from retention cysts which are yellowish sacs located under the epithelium.

Herpangina. Viral tonsillitis is caused by adenoviruses. The causative agent of herpangina is type A Coxsackie virus. The disease is usually sporadic in winter and spring and epidemic in summer and autumn. It occurs usually in children, especially in infants. The incubation period, 2-5 days; in rare cases 2 weeks. The disease is highly contagious.

The onset of herpangina is acute. The body temperature rises to 38-40°C, the patient complains of pain in the throat during swallowing, headache, and muscular pain in the abdomen. Vomiting and diarrhoea are also possible. Changes in the blood are moderate: slightly increased leucocyte counts, more often slight leucopenia, insignificant shift to the left. In rare cases (especially in children) serous meningitis can occur as a complication.

During the first hours of the disease diffuse hyperaemia of the

pharyngeal mucosa can be revealed pharyngoscopically. Small reddish vesicles can be seen on the soft palate, tongue, palatine arches, and, less frequently, on the tonsils and the posterior wall of the pharynx. The vesicles open in 3-4 days and resolve. The mucosa is normalized.

Necrotic (ulcerous-necrotic) tonsillitis. Symbiosis of *Bacillus fusiformis* and *Spirochaeta buccalis* that is often found in the mouth of healthy people in the avirulent state is believed to be the pathogenic factor. The incidence of the disease is low and sporadic. But during social disasters (war, famine) the incidence increases and the disease runs a more severe course.

The morphological changes are characterized by necrosis of the faucial surface of one tonsil with formation of an ulcer whose floor is covered with a loose fibrinous membrane underlied by necrotized lymphoid tissue.

Symptoms. The patient complains of discomfort in the throat (as if a foreign body is present) during swallowing, fetid breath and hypersalivation. The body temperature is usually normal; its elevation indicates possible complication. The leucocyte count moderately increases. The regional lymph nodes are enlarged on the involved side; they are moderately painful to palpation. Swallowing is usually painless. The disease lasts 1 to 3 weeks but can in some cases persist for several months.

Treatment consists in tending the mouth cavity, cleaning the ulcers from necrotized matter, gargling with disinfectant solutions (potassium permanganate solution, diluted 1:2000, ethacridine lactate, diluted 1:1000). The surface of the ulcer is treated with an iodine tincture, silver nitrate or other solution, but neosalvarsan or novarsenol is believed to be the most effective. These preparations can be rubbed, or applied superficially as powders or ointments. Novarsenol (0.3-0.4 g at 1-2-day intervals) and also penicillin (which also has the spirochaetocidal action) should be injected intravenously in severe cases.

Fungal tonsillitis. This disease occurs mostly in infants, usually during the cold season. The onset of the disease is acute. The body temperature is 37.5-37.9°C but it often rises higher. The general symptoms are not pronounced in cases with subfebrile temperature. Pharyngoscopy reveals enlarged and slightly hyperaemic tonsils (sometimes one tonsil only) and brilliant white loose (curd-like) patches that can be removed without injuring the underlying tissues. The patches are resolved in 5-7 days. The regional lymph nodes are enlarged. Yeast cells, mycelium of

the fungus causing white mouth, and bacterial flora are found in smears from the fauces.

Treatment includes envigorating measures and administration of vitamins B, C, and K, and nystatin, 50 000 U 3-4 times a day for 2 weeks. The affected sites should be smeared with a 2 per cent aqueous or alcoholic solution of methyl violet or gentian violet, and also with a 5-10 per cent sodium hydrocarbonate or Lugol's solution.

Adenoiditis (inflammation of the nasopharyngeal tonsil). Acute adenoiditis occurs mostly in children because the adenoid tissue of the nasopharynx grows during childhood. Adenoiditis in adults is rare and only occurs in patients in whom the nasopharyngeal tonsil has not yet undergone the age involution. The aetiological and pathological processes in adenoiditis are substantially the same as in acute inflammation of the other tonsils.

Symptoms of acute adenoiditis in older children and in adults are slight indisposition, subfebrile temperature, local burning in the nasopharynx, which is later attended by acute rhinitis. Respiration through the nose is difficult. Watery, mucous, and then purulent discharge from the nose is characteristic. The patient complains of pain in the ears and nasal speech. Acute otitis media concurs in some cases. The regional lymph nodes are enlarged. Acute adenoiditis in infants begins with elevation of body temperature to 40 °C and general symptoms of toxaemia, such as vomiting, liquid stools, and meningeal irritation. The symptoms of acute rhinitis and acute pharyngitis prevail. Severe cough usually indicates penetration of the mucous discharge into the larynx and the trachea which can cause tracheobronchitis or bronchopneumonia.

The possible dangerous complications are catarrhal or purulent otitis media, retropharyngeal abscess, suppuration of the regional lymph nodes, and also general infectious complications.

Treatment (local and general) is the same as for other acute tonsillites, acute rhinitis, and catarrh of the upper respiratory tract. Nursing babies should be given vasoconstrictors (into the nose) before each feeding; the nasal discharge should regularly be removed by suction.

Inflammation of the tonsilla tubaria and tubal elevations. Acute inflammation of the lymphoid tissue of tubal elevations usually occurs after removal of the tonsils or in combination with acute adenoiditis. The clinical picture is the same as in usual acute tonsillitis.

Lingual tonsillitis. Acute inflammation of the lingual tonsil is a relatively rare disease of middle and old age. Injuries to the mucosa inflicted during eating are of certain aetiological importance. The body temperature is febrile, swallowing is severely painful; speech is impaired. Protrusion of the tongue during its inspection and palpation of its root are very painful; a tonic spasm of the masticatory muscles sometimes occurs. Inspection with a laryngeal speculum reveals enlarged and hyperaemic lingual tonsil; punctate patches are sometimes formed. Oedema and stenosis of the larynx are dangerous complications.

Treatment is the same as for other acute tonsillites. Abscesses should be opened surgically.

COMPLICATIONS OF TONSILLITIS

Peritonsillitis. Inflammation (oedematous, infiltrative or with an abscess) of the peritonsillar cellular tissue arises due to virulent infection spreading, usually from the palatine tonsil to the peritonsillar cellular tissue in the presence of predisposing local or general factors. In most cases, peritonsillitis is a complication of acute tonsillitis; less frequently it is an exacerbation of chronic tonsillitis.

Symptoms. In the overwhelming majority of cases, the process is unilateral. Tonsillogenic peritonsillites usually occur several days following a recurrent exacerbation of chronic or acute tonsillitis. A peritonsillar abscess can be found in the anterior or anterosuperior (supratonsillar) part, between the tonsillar capsule and the upper part of the anterior palatine arch; the area above the tonsil is also involved. The supratonsillar location of the abscess is most common. Posterior peritonsillitis (developing between the tonsil and the posterior arch) may cause oedema of the larynx. Peritonsillitis can also be inferior, with location of the focus between the inferior pole of the tonsil and the lateral pharyngeal wall, or lateral, occurring between the middle portion of the tonsil and the lateral wall of the pharynx. Lateral abscess runs the most severe course because of difficult spontaneous drainage.

The onset of the disease is manifested by pain during swallowing; pain later becomes permanent, and intensifies significantly at the attempt to swallow the saliva. The patient complains of headache and fatigue; the body temperature rises to febrile. Spontaneous pain in the throat becomes more intense, it radiates into the ear, teeth, and becomes so intense during swallowing

that the patient refuses food and drinks. The saliva drains spontaneously at the angle of the mouth. Trismus of the masticatory muscles develops. The speech becomes nasal and slurred. Inflammation of the pharyngeal muscles and also cervical lymphadenitis cause pain as the patient moves his head. The patient holds his head inclined to one side and turns it together with the body. The leucocyte counts are $10\text{-}15 \times 10^9$ per l; the blood count is shifted to the left; the erythrocyte sedimentation rate increases.

The general condition of the patient is bad not only because of the presence of a purulent focus in the pharynx and toxaemia, but also because of severe pain in the throat, deranged sleep, and inability to swallow liquids or food.

Pharyngoscopy is difficult due to trismus: the mouth usually would open not wider than 2-3 cm. Anterosuperior and anterior peritonsillites are characterized by marked protrusion of the upper pole of the tonsil together with the palatine arches and the soft palate toward the median line. Half of the soft palate, together with the superior tonsillar pole and the upper part of the arches form a sphere whose surface is tense and hyperaemic; the uvula is moved to the opposite side, the tonsil is displaced posteriorly and inferiorly. The tongue is covered with a thick coat, the saliva is tenacious. Fluctuation is observed in the region of the strongest protrusion; the abscess opens at this point, often through the supratonsillar recess or the anterior arch. Emptying of the abscess is followed by alleviation of all symptoms of the disease.

It is necessary to exclude tumours (sarcoma, and others) which are usually not associated with elevated temperature, severe pain in the throat or painful palpation of the swelling in the throat and the regional lymph nodes. Secondary inflammatory changes can sometimes mask these differentiating signs.

Treatment. The patient must be hospitalized in severe cases; bed rest is obligatory. Warm and soft food and much liquid should be given. Thermotherapy is prescribed locally: warming compresses on the neck, gargling and irrigation of the mouth and the pharynx with sage or camomile tea; vapour inhalation is also useful. Narcotics are recommended in severe cases. Hypnotics should be given for insomnia. Acetylsalicylic acid is indicated for high body temperature. Regional or vagosympathetic cervical intracutaneous novocain block is sometimes helpful.

Antibacterial therapy is indicated for all stages of peritonsillitis. If the patient can swallow, sulpha drugs and antibiotics are given

per os. Antibiotics are injected intramuscularly in severe cases; penicillin should be preferred, but other antibiotics are also possible.

As soon as the abscess is ripe (the 3rd or 6th day) it should be opened surgically, without waiting for its spontaneous rupture. It is recommended to open the abscess, the more so that the opening of a spontaneously ruptured abscess is often insufficiently large to ensure a rapid and effective drainage of its contents. The abscess is usually incised without any anaesthesia, or after spraying over the pharynx with a 5-10 per cent cocaine or a 2 per cent dicaine solution. The incision should be done at the most prominent site. A dull tool, e. g. a bulbed probe or a packer, is often used to open the abscess, although this method is more painful (Fig. 36).

A more rational tactics is used at some clinics. After diagnosis of infiltrative or peritonsillar abscess is established, the frequency of acute tonsillitis in the anamnesis should be established. Relapses of acute tonsillitis during the past years indicate the presence of chronic tonsillitis which is complicated in this particular patient with peritonsillitis. Tonsillectomy is indicated in such cases. Sometimes tonsillectomy is indicated for lateral peritonsillitis, abortive attempt to open the abscess, persistent course of the disease, and in the presence of signs of complications, such as sepsis, pharyngeal abscess, phlegmon of the neck, and mediastinitis. The advantage of this approach is that the entire purulent focus is removed, whatever its location may be. This ensures quick recovery not only from peritonsillitis but also from chronic tonsillitis. Relapses of the disease and its complications are thus usually prevented.

Retropharyngeal abscess. This is a purulent inflammation of the lymph nodes and loose connective tissue found between the fascia of the pharyngeal muscles and the prevertebral fascia. The disease occurs almost exclusively in children because the lymph nodes and the loose connective tissue in this region are well developed up to the age of 4, after which they undergo involution.

The first symptoms are usually pain in the throat during swallowing and impeded respiration. The child refuses food, becomes restless and often cries; sleep is deranged. The temperature rises to 38-39°C; sometimes it is subfebrile. If the abscess is found in the nasopharynx, respiration through the nose becomes difficult, speech is nasal and the voice timbre dull. If the abscess is located in the mesopharynx, a pharyngeal stridor can develop. The voice becomes hoarse and respiration noisy. If the abscess extends onto the inferior parts of the pharynx, paroxysmal asphyx-

Figure 36
Peritonsillar abscess (posterior and anterior):

I – the site of incision;
II – stages of tonsillectomy:
a – incision of a tonsil pulled medially;
b – separation of the tonsil;
c – placing a loop on the tonsil

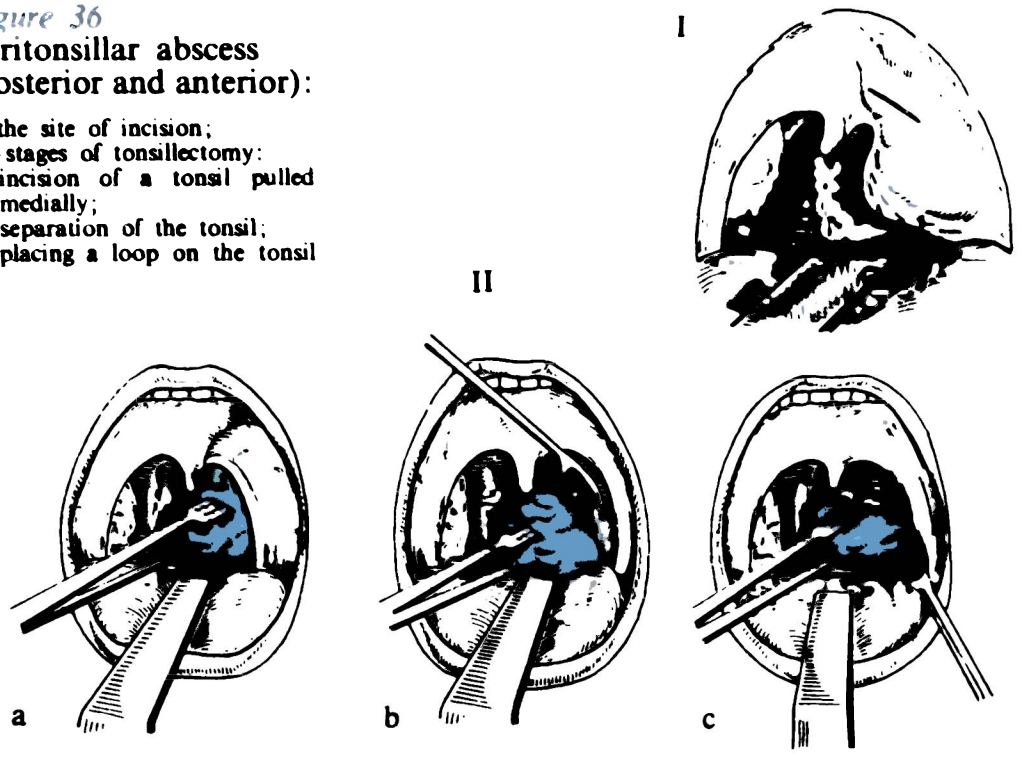

ia and cyanosis develop. The entrance to the larynx can be constricted, and the oesophagus and the trachea compressed.

The reaction of the regional lymph nodes is usually pronounced; they swell and become tender so that the child has to hold his head in a forced position. Pharyngoscopy reveals bulging and hyperaemic mucosa; the affection is often asymmetric so that only one half of the posterior pharyngeal wall is involved.

The blood reacts to the inflammation: the leucocyte counts increase to 10-15 × 10^9 per l; the blood count shifts to the left; the erythrocyte sedimentation rate accelerates to 40-50 mm/h. The disease lasts 5-6 days or sometimes longer.

Treatment should be conservative until the abscess develops. Antibiotics and sulpha drugs are prescribed; warm gargling with weak disinfectant solutions is recommended to older children, while infants may be treated by irrigation from a syringe. When an abscess develops, it should immediately be opened; measures should be taken to prevent aspiration of pus. This can be attained by preliminary suction of pus during puncture; the abscess should preferably be opened on a half-lying patient (Fig. 37).

Peripharyngeal abscess develops due to various causes, such as extention of infection to the cellular tissue of the peripharyngeal

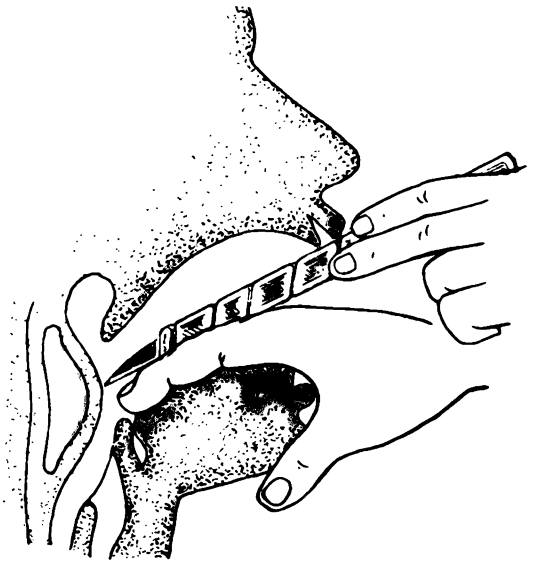

Figure 37
Opening a retropharyngeal abscess

space during acute tonsillitis, often during peritonsillitis; possible injury to the pharyngeal mucosa; purulent discharge from the mastoid process through the incisura mastoidea and the pharyngomaxillary space.

Symptoms. The patient experiences severe pain during swallowing (the mouth opens with great difficulty). The head is inclined to the involved side; respiration can be difficult. The body temperature is usually elevated, the general condition bad. The leucocyte counts are 12-14 $\times$ 10^9 per l, the erythrocyte sedimentation rate 45-50 mm/h. Inspection reveals levelling of the submandibular region. Fluctuation is sometimes revealed during palpation of the swelling.

Treatment at the initial stage of peripharyngitis includes intravenous injections of big doses of antibiotics in combination with oral administration of sulpha drugs. UHF-therapy on the submandibular region (12 sessions) and UV light on the lateral pharyngeal wall (through a cone) are also recommended during this period.

Ripe abscess should be opened surgically. There are two approaches: external, by the anterior margin of the sternocleidomastoid muscle, and through the oropharynx.

AFFECTIONS OF THE PHARYNX IN SYSTEMIC DISEASES OF THE BLOOD

Infectious mononucleosis. This infectious disease is probably caused by a special lymphotropic virus which occurs together with *Listerella* genus. It is believed that infection occurs by air-borne

droplets or by contact; the nasal cavity and the pharynx are the portals of infection.

Children and the young usually develop mononucleosis. The disease is characterized by a fever, tonsillitis-like changes in the fauces, adenosplenomegaly, and changes in the blood (high counts of leucocytes and atypical monocytes). The incubation period lasts 4-5 days (sometimes 10 days). At the onset of the disease the body temperature rises to 38-40° C and persists at this level from 5 days to 2-4 weeks (for longer periods in rare cases). The symptoms are sometimes alleviated periodically during this stage. An early and permanent sign of the disease is enlarged lymph nodes, first on the neck and then in the groin, armpits, and the abdomen. The spleen and the liver are also enlarged in most patients.

Changes in the fauces usually follow the enlargement of the lymph nodes; they are similar to those occurring in catarrhal, lacunar, fibrinous, and less frequently necrotic tonsillitis.

The most characteristic symptom of the disease is a great number of altered monocytes (60-80 per cent).

Treatment. Bed rest and high-calorie diet rich in vitamins are prescribed. Antibacterial preparations prevent secondary infection; the causative agent is insensitive to them. Gargling with disinfectant or astringent solutions is useful. Necrotized areas are treated with a 10 per cent silver nitrate solution. General light (UV) treatment is recommended.

Agranulocytosis (agranulocytic angina). Affection of the tonsils is the specific symptom of this disease. Agranulocytosis is considered not as an independent nosological disease but as a response of the haemopoietic system to various pathological factors (such as infection, toxicosis, radiant energy) or as a result of altered haemopoiesis in systemic diseases of the blood. Agranulocytosis occurs mostly in women; it is a rare disease affecting mostly adults.

Symptoms. The prodromal period is characterized by indisposition; it lasts 1-2 days. Fulminant, acute, and subacute forms of agranulocytosis are distinguished. In the former two cases the disease begins with high temperature (to 40°C), chills, and bad general condition. Necrotic and ulcerative changes in the pharynx, mainly in the region of the palatine tonsils, occur simultaneously. Necrosis often speads onto the mucosa of the pharynx, gums, and the larynx. In rare cases, the destructive changes occur in the intestine and the urinary bladder. Necrosis can extend onto deep underlying soft tissues and bones.

The blood is characterized by a very low count of polymorphonuclear leucocytes, or they can be absent.

Diagnosis is established by examining the blood. The disease should be differentiated from Simanovsky-Plaut-Vincent angina, the aleukaemic form of acute leucosis (leukaemia).

Treatment is aimed at activizing the haemopoietic system and controlling secondary infection. Administration of all medicines that can cause agranulocytosis (amidopyrine, sulphanilamide, salvarsan, etc.) should be suspended.

Blood transfusion, hormone preparations and other means of treating agranulocytosis are prescribed. The diet should be sparing; the patient must gargle the throat with antiseptic solutions; the necrotized matter should be removed.

CHRONIC TONSILLITIS

Inflammation of the palatine tonsils prevails among chronic inflammations of the other tonsils of the lymphoid pharyngeal ring. Therefore by chronic tonsillitis is usually understood chronic inflammation of the palatine tonsils. According to some authors, the incidence of chronic tonsillitis is 4-10 per cent among adult population and 12-15 per cent among children.

The factors predisposing the onset of chronic tonsillitis are the anatomo-topographic properties of the tonsils (the presence of crypts, and some others) and their histological properties, the presence of microflora in the lacunae and conditions favourable for its cultivation, and disordered biological and protective-adaptation mechanisms in the tonsil tissue.

In chronic tonsillitis the flora is not polymorphous in deep parts of the lacunae. Monoflora is usually found: various forms of streptococci (especially of haemolytic staphylococcus), adenoviruses (mostly in children), and others. Chronic tonsillitis should be regarded as an infectious disease caused mostly by autoinfection.

Chronic tonsillitis is usually secondary to acute tonsillitis. Acute inflammation of the tonsillar tissue is not followed by complete resolution; it continues and turns into a chronic form. In rare cases chronic tonsillitis can develop without preceding acute inflammation.

Permanent autoinfection from chronic foci such as carious teeth, chronic inflammation in the nasal cavity and the paranasal sinuses, or in the pharynx, and also bacterial and local tissue and general autoallergy provoke the onset of chronic tonsillitis.

The pathological inflammatory changes are localized in the epithelial coat of the fauces and in the walls of the tonsillar lacunae, in their parenchyma and stroma, and also in the peritonsillar connective tissue.

Symptoms and clinical classification of chronic tonsillitis. Frequently recurring acute tonsillitis in the anamnesis is the most reliable evidence of chronic tonsillitis. According to various authors, chronic tonsillitis can develop without preceding acute tonsillitis in about 2-4 per cent of cases. The diagnosis should be based on the assessment of all symptoms taken together because each separate sign can be caused by some other disease of the pharynx, teeth, jaws, nose, etc. Chronic tonsillitis cannot be diagnosed during exacerbation because all pharyngoscopic symptoms will characterize acute rather than chronic tonsillitis. Only 2-4 weeks after exacerbation it is possible to assess the objective signs of chronic inflammation of the palatine tonsils.

Chronic tonsillitis would be usually exacerbated 2 or 3 times a year, but acute tonsillitis can also occur 5 and 6 times during one year. In some patients chronic tonsillitis is exacerbated once or twice in the course of 3 or 4 years, but this recurrence should also be considered frequent.

The complaints of the patients are frequently recurring acute inflammation of the tonsils, unpleasant breath, discomfort and feeling of a foreign body in the throat during swallowing, dryness and prickling. But these complaints are characteristic not only for chronic tonsillitis but also for various forms of pharyngitis, dental caries, etc. The patient often complains of fatigue, flaccidity, headache, decreased working capacity, the temperature is often subfebrile. For many patients, sore throat in the anamnesis is the only complaint.

Inspection of the tonsils and the surrounding tissues reveals ridge-like thickening in the margins of the anterior and posterior palatine arches, their oedema, especially of the upper parts, hyperaemic margins of the palatine arches, often their adhesion to the tonsils and the triangular fold.

The tonsils of most adults with chronic tonsillitis are small, in children they are enlarged, but hyperplasia of the lymphoid tissue of the pharynx (of the palatine tonsils included) is considered normal for children. The surface of chronically inflamed tonsils can be loose, especially in children; but in most cases the tonsils remain smooth.

The presence of fetid caseous matter or purulent plugs in the

tonsillar lacunae is an important and most common sign of chronic tonsillitis. The lacunar contents are usually taken for diagnostic studies by expressing with a spatula.

A common local sign of chronic tonsillitis is enlargement of the regional lymph nodes: upper deep cervical, those located by the anterior edge of the sternocleidomastoid muscle.

The *simple form* of chronic tonsillitis is characterized by the above described symptoms in the absence of toxaemia or allergic reaction of the body associated with the chronic process in the palatine tonsils. Chronic tonsillitis in its simple form does not impair the general condition of the patient between exacerbations.

The *toxico-allergic form* is diagnosed by the same criteria as the simple form, and also by the symptoms of toxaemia and allergization: periodical elevation of temperature to subfebrile readings, increasing fatigue and decreasing working capacity, periodic pain in the joints and the heart, functional disorders of the nervous, renal and other systems. The intensity of the toxico-allergic changes and their severity can vary. First and second degrees are distinguished. Haematological, biochemical, immunological and other pathological changes can occur periodically in this form of the disease.

Chronic tonsillitis can concur with some other diseases that are classified as concomitant and concurrent.

Concomitance of systemic diseases with chronic tonsillitis is established by the presence or absence of the same aetiology, including the aetiology of exacerbations. For example, streptococcus or other microbe is known to be an aetiological factor for chronic tonsillitis and rheumatism (as well as for nephritis, infectious polyarthritis, etc.). In this concomitance, the connection between the diseases is manifested by periodic or constant direct effect of one disease on the other, especially during exacerbations. This phenomenon determines the physician's tactics in the treatment of chronic tonsillitis in the presence of concurrent chronic infections. If chronic tonsillitis concurs with another disease, it should be classified as toxico-allergic tonsillitis of the second degree.

Chronic tonsillitis often concurs with diseases of different aetiology which are, however, related to it through common reaction of the body. Essential hypertension, hyperthyroidism or diabetes mellitus can concur with chronic tonsillitis. In the presence of a *concurrent* disease, chronic tonsillitis can be simple or toxico-allergic, depending on the presence or absence of toxico-allergic reaction.

The course of concurrent diseases is aggravated by the presence of chronic infectious foci in the tonsils, but the pathogenetic

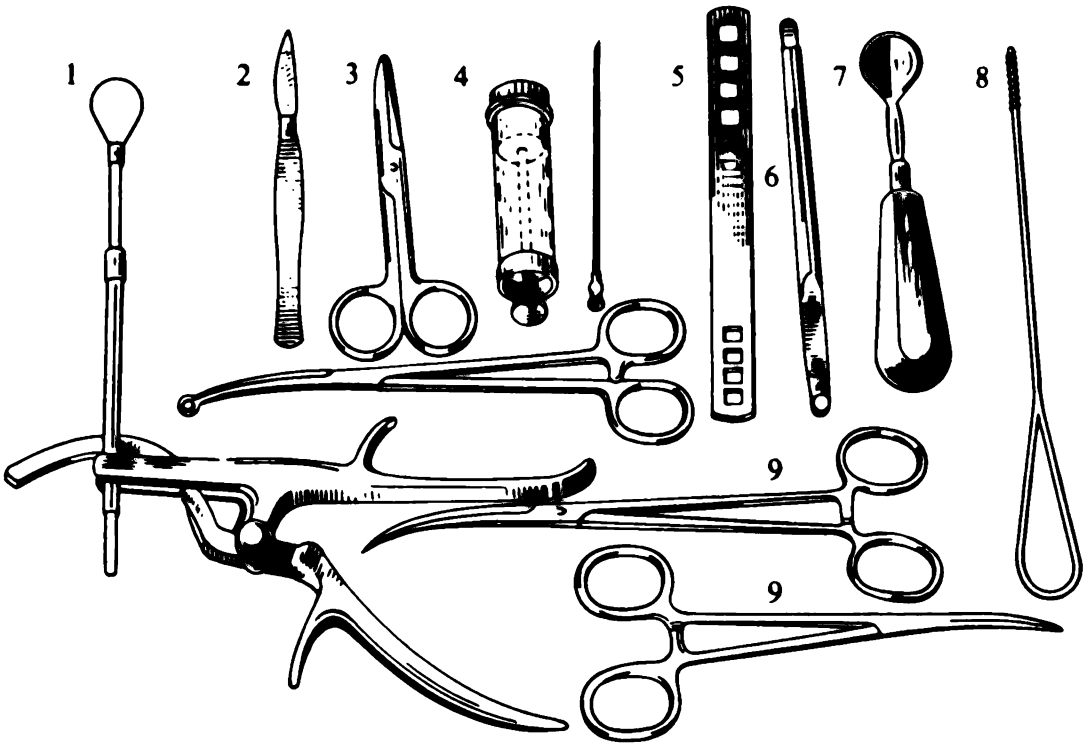

Figure 38
Tonsillectomy tools:

1 - wire loop;
2 - scalpel;
3 - scissors;
4 - syringe and a long needle;
5 - spatula;
6 - raspatory;
7 - curette;
8 - anaesthesia applicator;
9 - forceps

connections here are realized through the general reaction of the body.

Treatment. Treatment of chronic tonsillitis depends on its form. Simple chronic tonsillitis is as a rule managed conservatively, and only if this treatment proves ineffective in 3-4 courses, the tonsils should be removed (Fig. 38).

The toxico-allergic form should be treated surgically, but the first degree of this disease can also be treated conservatively (1-2 courses). If treatment is not sufficiently effective, tonsillectomy is indicated. Toxico-allergic symptoms of the second degree are direct indications for tonsillectomy. If this operation is contraindicated (e.g. in the presence of haemophilia), cryotherapy with liquid nitrogen should be recommended. Unfortunately the lymphoid tissue cannot be removed completely by this method.

Methods of conservative treatment are quite varied. Irrigation of the lacunae with various antiseptic solutions (furacin, boric acid, ethacridine lactate, potassium permanganate) and also mineral alka-

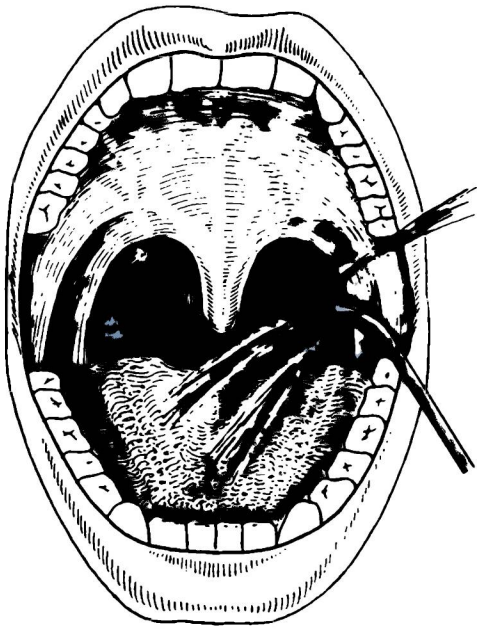

Figure 39
Irrigation of tonsillar lacunae

line water, peloidin and interferon is effective. A special syringe with a long curved cannula (Fig. 39) is used for the purpose.

Expression of the lacunar contents is used for diagnostic purpose only.

Among physiotherapeutic methods are UV rays, electromagnetic UHF and SHF oscillations, and ultrasound. UV light is applied to the outer surfaces (to the regional lymph nodes) and to the internal surfaces of the mouth: directly to the tonsils (using a cone). The course includes 10-15 sessions.

Oncological diseases (or suspicion of their presence) are absolute contraindications for any physiotherapy.

Indications for tonsillectomy are the following:

1. Chronic tonsillitis, simple and toxico-allergic (the first degree), in the absence of effect from conservative treatment.
2. Toxico-allergic chronic tonsillitis of the second degree.
3. Chronic tonsillitis complicated with peritonsillitis.
4. Tonsillogenic sepsis.

Tonsillectomy is absolutely contraindicated in the presence of severe systemic diseases of the cardiovascular system with circulatory insufficiency of the second and third degrees, renal failure with threatening uraemia, severe diabetes mellitus with threatening coma, severe hypertension with possible vascular crises, haemophilia (haemorrhagic diatheses), and other diseases of the blood and the circulatory system (chromocytopaenic purpura, Osler-Rendu syndrome) that are attended with haemorrhage and resist any therapy.

acute systemic diseases, exacerbations of chronic systemic diseases.

Dental caries, inflammation of the gums, pyogenic diseases, menstruation, and last weeks of pregnancy are temporary contraindications for tonsillectomy.

Pre-operative management is carried out in out-patient conditions. It includes laboratory tests (blood tests, including thrombocyte counts, coagulation and bleeding time, urinalysis), measuring arterial pressure, examination by a stomatologist, and examination of the internal organs. If any pathology is revealed, the patient must be examined by the appropriate specialist. If a patient is older than 40, ECG is taken before examination by an internist.

Before the night sleep on the eve of the operation, the patient should be given a hypnotic; 30-40 minutes before the operation, 1 ml of a 0.1 per cent atropine solution should be administered subcutaneously and a sedative (diazepam, trioxazine) given per os. The last meal should be taken not less than 4 hours before the operation.

In the majority of cases the operation is performed under local anaesthesia with the patient in the sitting position. Whenever necessary, tonsillectomy is performed under inhalation intubation anaesthesia.

During the first 24 hours after the operation the patient must not eat; only a few gulps of water are allowed in severe thirst. The patient should stay in bed for 4-5 days, during which he eats pureed or liquid food (warmed to body temperature). As a rule, the patient is discharged from hospital on the fifth day and is subsequently observed in out-patient conditions. The patient can also be discharged in 3-4 days; he must fulfil doctor's orders when he is at home: he must not perform hard physical work, must not wash with hot water, and eat a sparing diet. As a rule, the patient can resume his routine work in 2-3 weeks after the operation.

In children tonsillectomy is often performed simultaneously with adenotomy. Children better tolerate the operation and the post-operative period.

The most common complication of tonsillectomy is bleeding from the tonsillar fossa. It occurs in 1-8 per cent of patients operated on (usually during the first hours following the operation). During the first day after the operation, the discharge from the mouth should be constantly controlled. It is necessary to remember that blood can pass into the oesophagus. In suspected bleeding, the patient's pharynx should immediately be inspected and blood

clots, if any, should be removed and examined thoroughly. The bleeding sites should be clamped and ligated with catgut after preliminary anaesthesia. Pulse and pressure should be taken. If blood loss exceeds 300 ml, replacement blood transfusion is carried out.

As distinct from vascular bleeding, parenchymatous bleeding is usually not profuse. It can be managed by haemostatics, such as vitamin K (vicasol) parenterally, a 10 per cent calcium chloride (or calcium gluconate) solution intravenously, and transfusion of haemostatic doses of blood (to 100 ml). The tonsillar fossa should be packed with a tampon soaked with haemostatics. If a tampon has to be held in place for a long time, the palatine arches can be ligated above it. If bleeding is profuse and all measures to arrest it fail, the external carotid artery is ligated on the involved side. In rare cases bleeding occurs at later terms: in 7-10 days after the operation. It should be arrested as described above. The patient should be hospitalized.

PREVENTION OF ACUTE AND CHRONIC TONSILLITIS

Prophylactic measures against chronic tonsillitis are substantially the same as against acute tonsillitis. There exist individual and social aspects in prevention of tonsillitis.

Individual prophylaxis includes envigorating measures which strengthen the patient's resistance to infection and unfavourable environmental conditions. Acute tonsillitis is often preceded by local or general chilling. Hence the importance of general and local hardening of the body: regular exercises and sports, morning exercises, air baths, and sponging with water (with gradually lowering temperature); sponging of the neck with cold water and subsequent rubbing with a towel. But all these measures should be taken gradually and regularly, with due consideration of the individual properties of the patient's body.

Social prophylactic measures include control of microbial and other kinds of contamination of the environment, including improvement of working and living conditions.

The resistance of the body increases after UV-therapy during the cold season. Treatment of infectious foci in the mouth and nose is also very important for prevention of acute and chronic tonsillitis. Health education of population is another important measure. Adequate labour and rest conditions and rational nutrition increase the body's resistance to infection.

Revealing cases with chronic tonsillitis and their subsequent treatment are important aspects of health care, since it is an important measure in control of cardiovascular pathology. Prophylaxis and treatment of various other diseases depend on control of chronic tonsillitis as well.

Children at kindergartens and schools, students, industrial and agricultural workers should be regularly examined for chronic tonsillitis in out-patient conditions. The main objectives of out-patient observation are the early diagnosis and timely treatment of chronic tonsillitis.

FUNGAL DISEASES OF THE PHARYNX

Fungal diseases of the pharynx, and especially of the mouth, have been known for long. Candidiasis prevails among them. Some endogenic and exogenic factors are responsible for this morbidity. Systemic diseases of the blood and malignant newgrowths are among the former factors, while the main exogenic factor is injury. It should also be emphasized that long use of antibiotics provides conditions for the development of fungal diseases as well.

Mycosis of the pharynx occurs in both children and adults; the incidence among women is higher.

The *aetiological agents* are usually yeast-like fungi, less frequently moulds.

The *pathogenesis* of the disease substantially depends on incorrect diagnosis and hence incorrect treatment.

Clinic of tonsillar candidiasis. The onset of the disease is characterized by tickling in the throat, malaise, and subfebrile temperature. Pharyngoscopy reveals white or grey patches on the hyperaemic tonsillar mucosa. The patches can sometimes have curdy consistency; less frequently patches are granular. The patches are easily removed, the mucosa remaining smooth. If deeper tissues are involved, the underlying surface is eroded. Diphtheria should be excluded in such cases.

If the pharynx is affected with moulds, the coat is yellowish. Erosion occurs after removal of the coat even if the affection is only superficial.

Diagnosis is based on the clinical and laboratory findings.

Treatment. The main preparation to treat fungal diseases of the throat is nystatin (from 2 to 4 million U/day). The patient should either suck the tablet or chew it to ensure local application

of the medicine. This therapy should be given in 2-3-week courses with ten-day intervals.

Another helpful preparation is levorin (sodium salt). It is given in 500 000 U doses 4 times a day. If this dose proves inefficient, it should be doubled. A solution of the sodium salt of levorin (70 000 U in 1 ml of distilled water) is used for gargling.

Iodine therapy is effective for fungal pharyngeal affections (potassium iodide solution of gradually increasing concentration: 2-3-4-5-6-8-10 per cent aqueous solution, a tablespoonful three times a day with milk). This treatment is long. More effective is irrigation of the mucosa with chinosol solution.

Repeated courses of medicamentous therapy should be prescribed after recovery for prophylactic purposes.

Review questions

1. How many parts of the pharynx are distinguished?
2. Define acute tonsillitis. What forms of acute tonsillitis do you know?
3. How can lacunar tonsillitis be differentiated from diphtheria?
4. What is chronic tonsillitis?
5. What forms of chronic tonsillitis do you know?
6. What methods of treating chronic tonsillitis do you know?
7. Tell about injuries to the oesophagus and methods to treat them.

Problem

A patient in a hospital develops signs of acute lacunar tonsillitis. What prophylactic measures should be taken?

DISEASES OF THE LARYNX, TRACHEA AND BRONCHI

CLINICAL ANATOMY

The larynx. This is the wider part of the upper airways, which opens with its superior end into the pharynx; its inferior end opens into the trachea. The larynx is located under the hyoid bone in the anterior part of the neck. The outlines of the larynx are readily seen in lean males.

The upper edge of the larynx in adult males borders on the fourth and fifth cervical vertebrae, while the lower edge – on the sixth and seventh cervical vertebrae. The larynx is located slightly higher in neonates, in the young, and in women. Its position is, on the contrary, lower in the aged.

The lateral surfaces of the larynx border on the lobes of the thyroid gland and the vasculonervous bundles of the neck. The posterior surface of the larynx borders on the lower part of the pharynx; at the level of the inferoposterior edge it is adjacent to the upper part of the oesophagus.

During swallowing and phonation, the external muscles of the larynx move it up and down. This mobility of the larynx is a functional necessity. The larynx moves because its muscles are connected through the agency of the hyoid bone with the tongue and the mandible superiorly and with the sternum and the clavicles inferiorly.

The framework of the larynx has the shape of a truncated pyramid. It consists of cartilages interconnected by ligaments. The cartilages are as follows: three unpaired, namely, epiglottis, thyroid, and cricoid, and three paired cartilages – arytenoid, corniculate, and cuneiform cartilages.

The laryngeal cartilages are interconnected by ligaments and joints which allow articulation with respect to one another (Fig. 40).

External and internal muscles of the larynx are distinguished. The external muscles (three paired muscles) fix the larynx in a certain position or move it up and down. The internal muscles are divided according to their function into three groups:

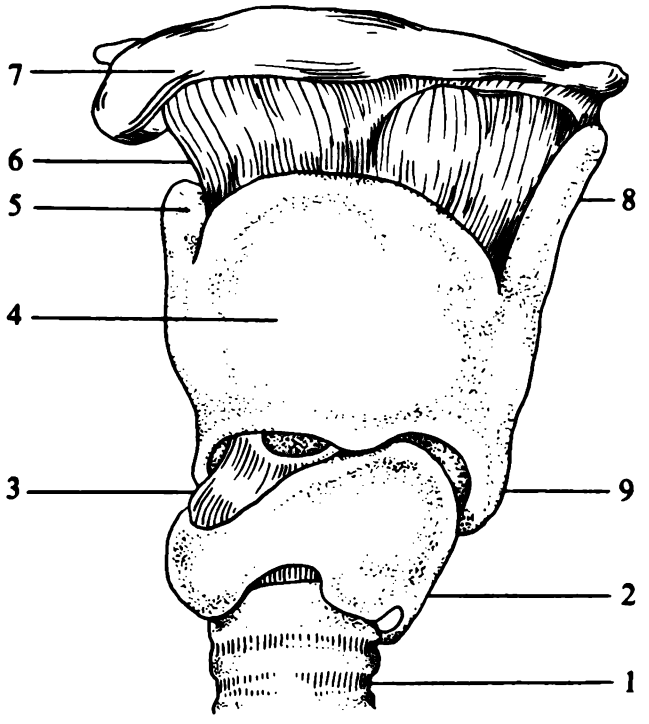

Figure 40
Larynx framework:

1 – trachea;
2 – cricoid cartilage;
3 – conus elasticus;
4 – thyroid cartilage;
5 – thyroid notch;
6 – thyrohyoid membrane;
7 – hyoid bone;
8 – superior horn of the thyroid cartilage;
9 – inferior horn of the thyroid cartilage

(1) one (paired) muscle dilates the larynx lumen during inspiration;

(2) three muscles narrow the lumen of the larynx and thus perform the vocal function;

(3) two muscles stretch the vocal cords;

(4) two muscles lower the epiglottis and incline it posteriorly.

The laryngeal cavity is formed by the cartilages, ligaments, and the muscles. The larynx is lined with mucous membrane. Three parts are distinguished in the larynx: the upper (the vestibule) part overlying the vocal folds, the middle part including the vocal folds, and the lower (infraglottic) part found below the vocal folds.

The inlet to the larynx is bounded anteriorly by the epiglottis; posteriorly, by the apices of the arytenoid cartilages; and laterally, by the aryepiglottic folds with the piriform recesses by their sides. Three glosso-epiglottic folds extend from the anterior surface of the epiglottis to the root of the tongue, the epiglottic valeculae are lodged between them. Two pairs of horizontal folds of mucous membrane are found at the lateral walls inside the laryngeal cavity. The upper folds are called vestibular, while the lower are called the vocal folds. The part of the larynx found above the vocal folds has a cone-shaped cavity, called the vestibule of the larynx. The space between the vocal folds is known as the rima glottidis (or glottis). It communicates the infraglottic part of the laryngeal cavity with the supraglottic part. The vestibular and

the vocal folds are paired. Laryngeal ventricles are located on each side of the larynx between the vestibular and the vocal folds. Each ventricle has a diverticulum, the laryngeal saccule extending upwards.

The vocal folds are 20-22 mm long in men and 18-20 mm long in women. The width of the rima glottidis in its posterior part varies in adults from 17 to 20 mm.

The laryngeal mucosa is continuous with the mucosa of the laryngopharynx. In its lower portion it is continuous with the mucosa of the trachea.

Blood is supplied to the larynx from the superior and inferior laryngeal arteries, while the blood outflows through the venous plexus of the larynx, tongue, and the neck. The main outflow of the venous blood from the larynx occurs through the superior thyroid vein which empties into the internal jugular vein.

The lymphatic network of the larynx is mostly found in the ventricular mucosa and the mucosa of the upper portion of the larynx. The lymph is collected in deep cervical lymph nodes located along the course of the internal jugular vein. The lymph from the lower part of the larynx is collected in the nodes, found before the conus elasticus, along the course of the internal jugular vein, and also in the pretracheal nodes.

The larynx is innervated by the sensory and motor branches of the vagus nerve. The superior laryngeal nerve is primarily sensory; it originates from the vagus nerve in its inferior region. The inferior laryngeal nerve is motor; the left nerve originates from the vagus nerve at the point where it passes over the aortic arch, while the right nerve begins at the level of the subclavian artery. These two branches enter the larynx at its sides, between the cricoid and the thyroid cartilages.

The **trachea** is the continuation of the larynx, with which it is connected through the cricotracheal ligament. The trachea is a long tube, about 11-13 cm long, beginning at the level of the seventh cervical vertebra; at the level of the fourth and fifth thoracic vertebrae it divides into two main bronchi. The point of division is called the bifurcation. In neonates, the lower end of the trachea is found at the level of the third-fourth thoracic vertebrae. The tracheal wall consists of 16-20 U-shaped hyaline cartilages, whose free ends are directed posteriorly. The cartilages are connected by a membranous wall and annular ligaments owing to which the tracheal lumen broadens during inspiration and narrows during expiration. The tracheal lumen varies between 15 and 22 mm

in men and between 13 and 18 mm in women. In infants, the lumen is 6-7 mm and in a 10-year-old child from 8 to 11 mm. The trachea is lined with mucous membrane with columnar ciliated epithelium. The cilia move in the upward direction.

The posterior membranous part of the tracheal wall is adjacent to the anterior wall of the oesophagus. This should be remembered when performing tracheostomy in order to prevent possible injury to the oesophagus wall and formation of a tracheo-oesophageal fistula. A semilunar projection, known as the carina of the trachea, is found at the point of bifurcation. One of the main bronchi, the right one, is wider and shorter than the left. The right bronchus is 3 cm long and the left one, 5 cm long. Foreign bodies usually get into the right bronchus.

The blood to the trachea is supplied by the inferior thyroid and the bronchial arteries. The veins of the trachea and the bronchi empty into the thyroid veins.

The trachea and the bronchi are innervated by the recurrent laryngeal branch of the vagus nerve and its tracheal branches which form a plexus in the inferior portion of the airways. The muscular fibres of the bronchi are innervated by the fibres of the vagus nerve and the nerves of the sympathetic trunk.

CLINICAL PHYSIOLOGY

The larynx, the trachea and the bronchi perform three functions: respiratory, protective, and voice producing (phonation).

The respiratory function. The larynx is a part of the respiratory tract. It conveys air during inspiration into the lower portions of the tract, viz., the trachea, the bronchi, and the lungs. During expiration the air passes in the reverse direction. The respiratory act is performed by the respiratory muscles, and in the larynx by the cricoarytenoid muscles which contract to widen the rima. The glottis is always open during respiration.

The protective function. Being part of the airways, the larynx and the trachea act also as a barrier to prevent penetration of foreign bodies into the lower parts of the respiratory tract. On the other hand, these are the organs where the inspired air is humidified, warmed, and cleaned. The protective mechanism is associated with the presence of three reflexogenic zones in the laryngeal mucosa.

When irritated by food or any solid particles, or by some chemical agents, the mucosa of these zones evokes the spasm of

the glottis. The reflex is transmitted to the muscles responsible for the expiratory act. A reflex cough is thus provoked: sputum is expectorated and respiration accelerated. The larynx performs a series of complicated movements during swallowing. As it rises, the epiglottis moves anteriorly to cover the inlet of the larynx. The epiglottis moves together with the root of the tongue, and the upper portion of the epiglottis comes in contact with the posterior wall of the larynx. Food passes over the epiglottis by its sides to the widened entrance to the oesophagus.

The protective function of the trachea and the bronchi consists in expulsion of extraneous matter that may penetrate into the airways with the inspired air. Ciliated epithelium of the mucosa, and also the secreted mucus facilitate removal of the extraneous matter from the airways.

The voice-producing function. Three main parts of the respiratory apparatus are involved in the formation of sounds. These are: (1) the lungs, bronchi, trachea (lower resonator); (2) the vocal apparatus of the larynx, including the vocal folds; (3) the resonating chambers of the mouth, nose and the paranasal sinuses, which change their shape due to movement of the jaw, lips, soft palate and the cheeks (the upper resonator).

During phonation the glottis is first closed; the vocal folds are tense and pressed together. Under the thrust of the air expelled from the lungs, the trachea and the bronchi, the glottis opens for a short time and part of the air passes through it, after which it closes again. The pitch of sounds depends on the frequency of these vibrations. To produce a sound of the wanted pitch, the laryngeal muscles contract and give reflectorily the necessary length and tension to the vocal folds and the necessary shape to the upper resonator.

When we whisper, the vocal folds are adducted only over their anterior parts and as air passes the glottis, noise is formed in the posterior part of the glottis which is actually a whispered voice.

Voice differs in pitch, timbre, and intensity. The larynx and the vocal folds are larger in men and their voice is therefore an octave lower than in children and women. Mutation of voice occurs during sexual maturation. At the age between 12 and 16, alto or treble of boys converts into tenor, baritone or bass, while the voice of girls turns into soprano, mezzosoprano, or contralto.

The character of speech sounds depends not on the larynx but

on the shapes of the mouth, pharynx, and the arrangement of the organs in these cavities.

METHODS OF EXAMINATION

Laryngoscopy is visual inspection of the larynx interior. Direct and indirect laryngoscopy are distinguished.

Direct laryngoscopy is used in cases where inspection with a speculum is infeasible (in infants) or if inspection is not sufficiently informative. Direct laryngoscopy is also used when specimens of live tissue have to be taken (biopsy) for histological studies, or if a newgrowth should be removed. At the present time direct laryngoscopy precedes the intubation of the airways under anaesthesia and is the first step in tracheobronchoscopy. The larynx should be inspected on a fasting stomach (except in emergency cases). Direct laryngoscopy in children can be performed without anaesthesia.

Indirect laryngoscopy is carried out using a laryngeal speculum (Fig. 41). The mirror is fixed in the handle, warmed in hot water (to 40-50 °C) for 2-3 seconds and dried up with a piece of cloth. (The temperature of the speculum should be tried by touching it with the back of the hand.) The patient is asked to open the mouth, produce the tongue and breathe through the mouth. The tip of the tongue should be held between the first and the third fingers of the left hand using a piece of gauze, with

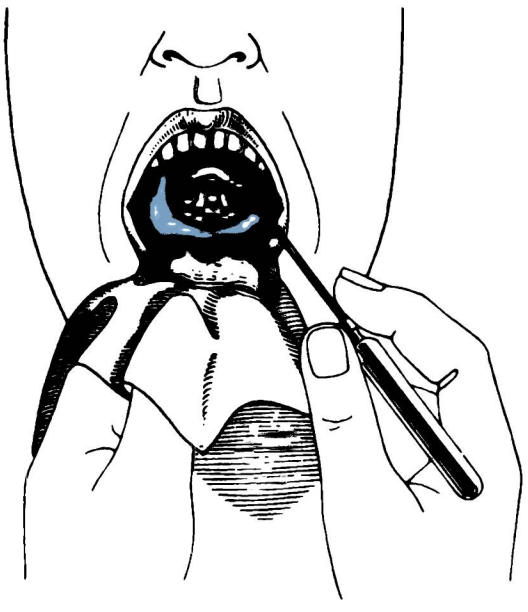

Figure 41
Indirect laryngoscopy

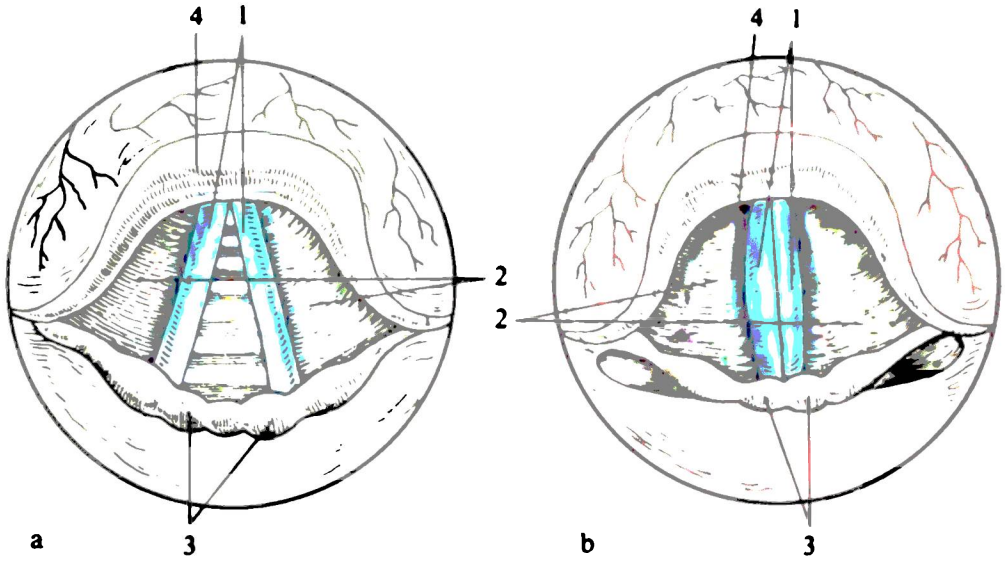

Figure 42

Larynx as viewed by indirect laryngoscopy:

a - larynx during inspiration; *1* - vocal folds; *3* - arytenoid cartilages;
b - larynx during phonation; *2* - vestibular folds; *4* - epiglottis

the second finger placed on the upper lip. The tongue can now be slightly pulled forward and down.

The laryngeal speculum is held in the right hand as a writing pen and introduced into the mouth with the mirror down. The speculum should be moved parallel to the tongue without touching its root or the posterior wall of the pharynx as far as the soft palate; then the mirror is positioned at an angle of 45° to the middle axis of the pharynx; whenever necessary the soft palate can be lifted slightly backwards; the light of the head mirror is now directed on the speculum. The position of the speculum should be corrected carefully so that the larynx can be seen in it. The patient is asked to utter a long sound 'ah' and take a deep breath. During phonation, and then during inspiration the inner surfaces of the larynx become visible in two phases of the physiological activity.

When the inspection is over, the speculum is removed, the mirror detached from the handle and placed in a disinfectant.

The image reflected in the mirror differs from the natural view of the larynx: the anterior parts of the larynx are seen below and therefore appear as if they are located posteriorly, while the posterior parts are seen in the upper part of the image and appear anteriorly. The left and right sides in the mirror reflection and in reality are the same (see Fig. 42).

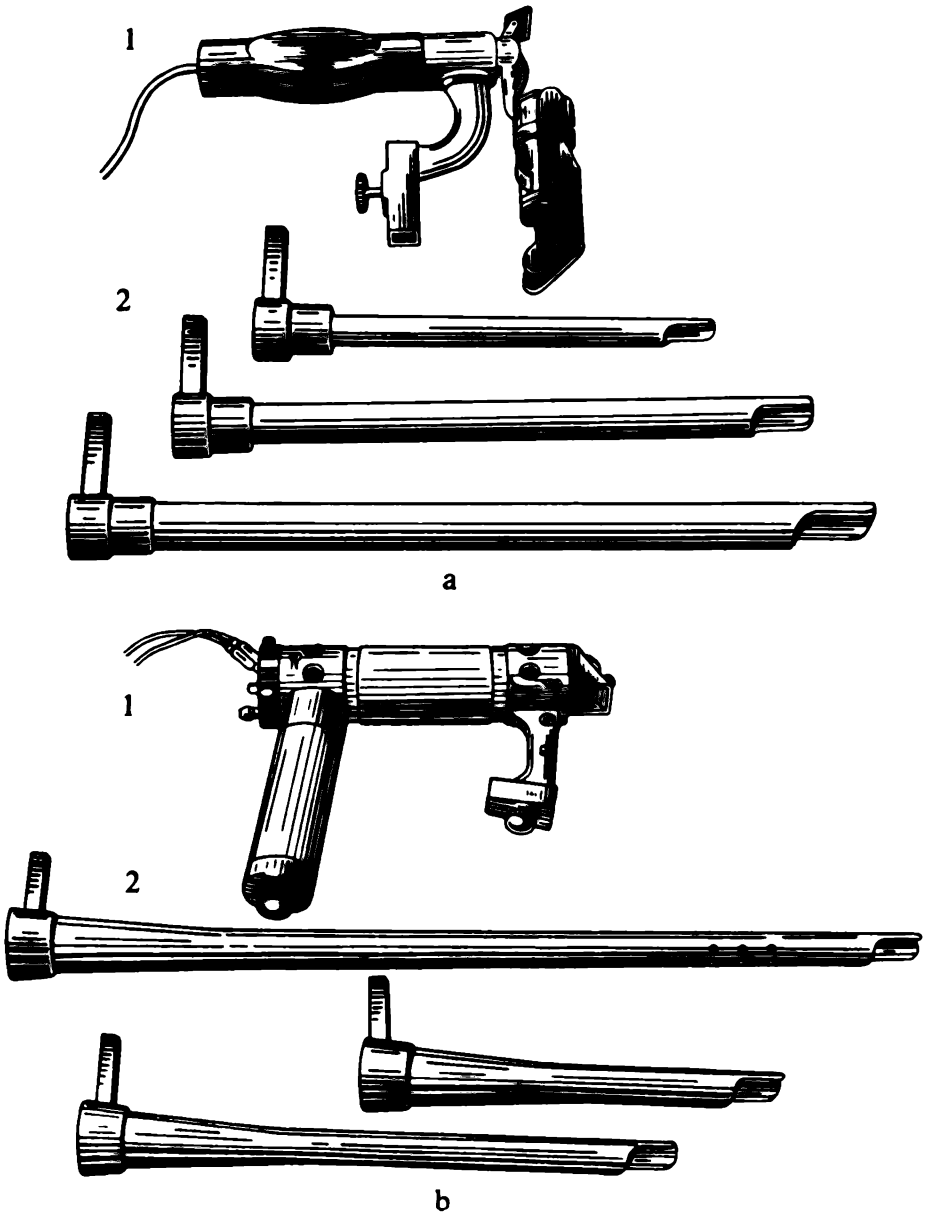

Figure 43
Broncho-oesophagoscopes:

a - Brunnings' broncho-oesophagoscope:
1 handle with an illuminating system;
2 - set of endoscopic tubes;
b - Mezrin's broncho-oesophagoscope:
1 - handle with an illuminating system;
2 - set of endoscopic tubes

The general view of the larynx and the condition of its separate parts should be examined. The root of the tongue with the lingual tonsil are first of all seen in the mirror, then viewed is the leaf-shaped epiglottis. The mucosa of the epiglottis is normally pale-pink or slightly yellowish. Two valeculae are seen between the epiglottis and the tongue root; they are bounded by the lateral and middle glosso-epiglottic folds. During phonation and deep

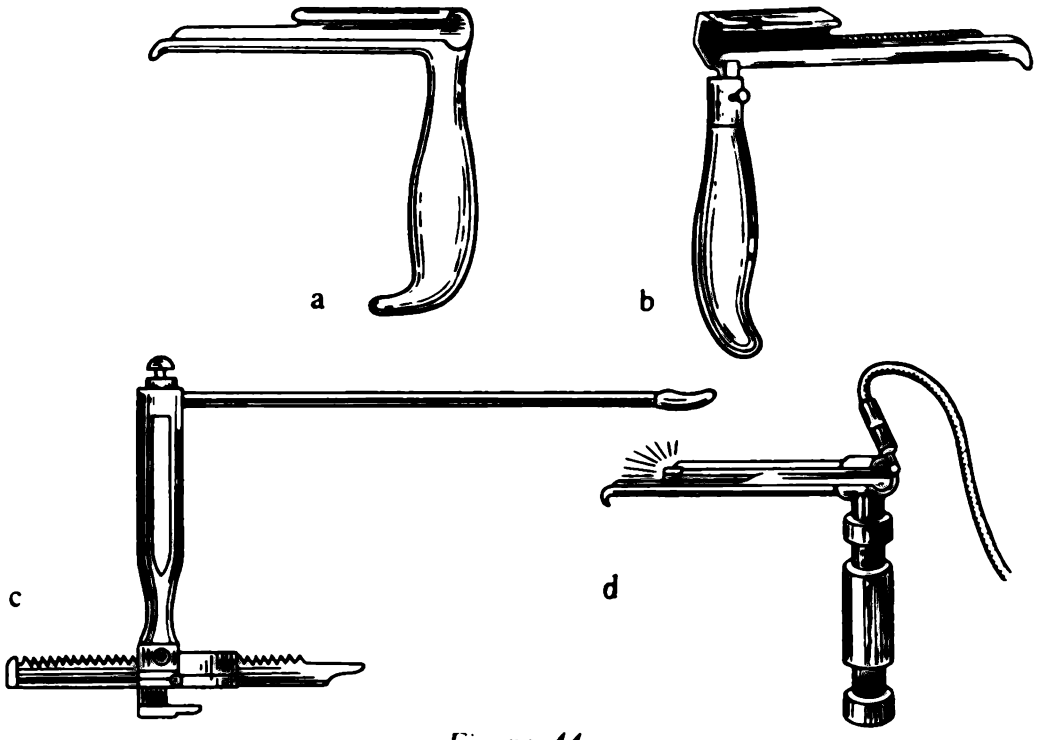

Figure 44
Instruments for direct laryngoscopy:

a – Undrits' spatula;
b – Tikhomirov's spatula;
c – Zimont's orthoscope;
d – Undrits' directoscope with an illuminating system

inspiration, the vocal (true vocal) folds are well seen. Normally they are pearl-white. Their anterior ends, at the point of their origination from the thyroid cartilage, form an acute angle, the anterior commissure. Pink vestibular folds (false vocal cords) can be seen above the true vocal cords. Laryngeal ventricles are found between the vocal and vestibular folds. The posterior parts of the larynx can be seen in the frontal part of the mirror image. These are the arytenoid cartilages which appear as two tuberosities covered with a pink smooth mucous membrane; attached to the vocal processes of these cartilages are the posterior ends of the vocal folds; the interarytenoid notch is seen between the bodies of the cartilages. Smooth pink aryepiglottic folds extend from the arytenoid cartilages to the epiglottis. The piriform recesses are located laterally to the aryepiglottic folds; their mucosa is smooth and pink.

Roentgenotomography is an important paraclinical method of examination of the larynx.

The trachea and the bronchi are examined for diagnostic and therapeutic purposes using the same apparatus as those used for

Figure 45
Tracheobroncho-oesophagoscopy on a sitting patient

the examination of the oesophagus. The airways can be examined repeatedly.

The diagnostic inspection of the trachea and the bronchi is indicated for respiratory dysfunction in the presence of newgrowths, tracheo-oesophageal fistula, atelectasis of any location, etc. Therapeutic *tracheobronchoscopy* is indicated mainly for the presence of foreign bodies, scleroma, and infiltrations or cicatricial membranes in the infraglottic compartment (Figs 43, 44). The bronchoscope is used as a probe in such cases. Tracheobronchoscopy is an important means of treating abscessing pneumonia, lung abscess, etc. Instrumental examination of the lungs is also important in treating pulmonary tuberculosis. Lower and upper tracheobronchoscopy are distinguished, depending on the level to which the tube is introduced. In upper bronchoscopy the tube is passed through the mouth, the pharynx and the larynx, while in lower tracheobronchoscopy, through a preliminarily formed tracheostomic opening, the tracheostoma. Lower tracheobronchoscopy is used mostly in infants under 3 years of age and in persons that have undergone tracheostomy (Figs 45, 46, 47).

The anaesthetic aspect of this manipulation is important. At the present time general anaesthesia would be normally preferred, the

Figure 46
Tracheobroncho-oesophagoscopy on a patient in the prone position

Figure 47
Inferior tracheobronchoscopy on a lying patient (the bronchoscope is introduced through the stoma)

more so that special breathing systems (Friedel) are available. Inspection of the trachea and the bronchi in children is carried out only under general anaesthesia. Induction anaesthesia is therefore performed in the operating room. The patient lies on his back with the head tilted backwards. Anaesthesia is given by an anaesthesiologist. The advantage of general anaesthesia over local analgesia is the reliability of narcosis, prevention of psychic trauma, relaxation of the bronchial tree, and others.

After tracheobronchoscopy, the patient should be kept under physician's observation for at least two hours because oedema of the larynx and its stenosis are likely to occur during this period.

GENERAL THERAPY AND NURSING

Most inflammatory diseases of the larynx, the trachea and the bronchi should be treated locally by applying medicines externally to the affected surfaces, instilling liquids into the larynx, the trachea and the bronchi, by insufflation of powders into the larynx, and inhalation (in gas or vapour form) of medicines. Medicines *are applied externally* to the mucosa of the larynx using cotton tightly wound around an applicator; care should be taken to prevent excess liquid as it can cause laryngospasm. A laryngeal syringe is used *to instill* liquids into the larynx or the trachea. The procedure should be performed under visual control. Laryngospasm is practically absent with this method of treatment. Powders *are insufflated* using a special tool with a curved endpiece. The amount of medicine administered into the airways should be minimal, because instantaneous insufflation of a large amount of powder can cause laryngospasm.

Inhalation implies breathing in of medicines atomized in air or vapour. Manual, portable, or stationary apparatuses can be used for the purpose. Alkaline and oil inhalations are distinguished. Antibiotics, corticosteroids, proteolytic enzymes and other agents are also administered by inhalation. Alkaline inhalations thin tenacious mucus and crusts, and facilitate expectoration. Oil inhalations (vegetable oils alone are used) protect the mucosa by forming a thin film.

Patients with diseases of the larynx require special care. The voice-producing function is impaired to a greater extent than the respiratory function in patients with acute laryngitis. Patients with

acute laryngitis or with exacerbated chronic laryngitis are prohibited to talk.

Crusts can be formed from mucus in patients with exacerbated chronic laryngitis which narrow the glottis. When the first signs of stenosis appear, 1.5-2 ml of an alkaline-oil solution should be instilled into the larynx.

The most dangerous form of laryngeal affection is oedema of the larynx and its stenosis. Oedema of the larynx is usually of allergic aetiology and can develop very quickly. This should be borne in mind and the medical personnel must be able to render emergency aid in such cases. In order to eliminate oedema or to prevent its fulminant development, the patient is given antihistaminics (pipolphen, dimedrol); counterattractive measures should also be taken (hot bath for feet). The respiratory function of patients with oedema of the larynx should be constantly controlled.

Respiratory distress can develop in subglottic laryngitis. Special care should be given to children with false croup because the attacks usually occur during night sleep, and the children, in addition to the respiratory distress, experience the sense of fear. In order to relieve the attack, fresh air should be immediately supplied (the window should be opened) and counterattractive measures taken (hot bath for the feet, mustard plasters on the calves, hot liquids); it is very important to soothe the child.

Very often tracheostomy is performed urgently in the absence of special conditions (in the patient's bed), and the assistant physician on duty and a junior nurse have to assist the physician.

The patient requires especially thorough care and constant observation during the first days following tracheostomy. The junior nurse must see to it that the tracheostomy tube is not clogged with mucus or diphtheritic membranes. To prevent this, 2 or 3 drops of sterile vegetable oil, a 4 per cent baking soda solution, or a freshly prepared chymopsin solution should be instilled into the tracheostomy tube at 2-3-hour intervals. It is recommended to instill these solutions alternatively.

During the first days after the operation, the inner tracheostomy tube should be removed 2 or 3 times a day and its lumen cleansed using a flexible probe with cotton wool wound round its serrated end; the tube should then be sterilized by boiling water. If the tracheostomy tube is made of plastic, it can only be cleansed, washed with water, and then treated with alcohol. Never sterilize a plastic tube by boiling it! Before passing the inner tube (either a metal or a plastic one) into the outer tube, it should be smeared

with oil. The outer tube can be removed only by a physician. If diphtheritic secretion is tenacious, the inner tube should be removed and cleansed at shorter intervals. As the patient breathes through a tracheostomy tube, the air bypasses the natural cavities where it is otherwise warmed up and humidified. The nurse must therefore check air humidity in the room. In the absence of an air conditioner, the air in the room can be humidified by hanging wet bed sheets or by covering the tube orifice with two layers of wet gauze. The gauze should be replaced as soon as it dries up.

It is very important to remove the bronchial and tracheal discharge in patients with a tracheostomy tube. Weak patients cannot expectorate the secretion effectively, and the tracheal contents should therefore be removed by suction. Thirty minutes before this procedure, the patient's bed is adjusted so that the patient's head is slightly lower than his legs and his chest is massaged. Then, ten minutes before the procedure, 1 ml of a 2 per cent sodium bicarbonate (baking soda) solution should be instilled into the tracheostomy tube to thin the mucus.

Suction apparatus is used for the purpose. The end-piece and the catheter should be sterilized by boiling. Rules of asepsis must be observed during suction. The catheter should be passed to a depth of at least 10 cm.

As a rule, patients with a tracheostomy tube are given liquid food. After each meal the nurse must check the condition of the tube.

It is also necessary to see that the sputum expectorated by the patient does not cause maceration of the skin round the tracheostoma. To that end, the skin should be adequately treated (the sputum removed and disinfectant solutions applied) and coated with Lassar's paste. The dressing should be renewed without withdrawing the tube. When the patient is restless and has attacks of cough, the tube can move from its correct position. The nurse must check regularly if air passes to the lower airways through the tube. It is easy to do so: a piece of cotton wool should be held close to the tube orifice and its fluctuations will be quite obvious if air passes through the tube properly. Subcutaneous emphysema can develop in strong coughing.

A patient can develop severe hypoxia after a long and serious operation. The personnel of the hospital must therefore see to it that an oxygen bag should always be available at the patient's bedside (if the oxygen supply is not centralized). In order to prevent congestive changes in the patient's lungs, the patient should

be assisted to a half-sitting position; 24 hours following the operation remedial exercises (10 deep inspirations and expirations) should be done at 2-3-hour intervals.

Adult tracheostomy patients require constant observation; a child should be constantly observed by nurses.

After removal of the tracheostomy tube, adult patients begin breathe freely through the natural airways, while children, especially infants cannot adapt immediately to new conditions and therefore require thorough observation.

Nutrition of patients operated for diseases of the larynx and the trachea is important. The first ten days following the operation, the patient should be fed through a gastric tube. This is not a physiological nutrition because food enters the stomach bypassing the mouth and the pharynx. Adequate nutrition is very important for the course of the postoperative period. The nurse must see to it that the food for tube intake is well homogenized, warmed up to the body temperature, and contain all the necessary components such as proteins, fats and carbohydrates. Feeding should be regular, at 3-4-hour intervals, and given in small portions (300-400 ml for one intake).

Food should be delivered into the tube slowly, through a funnel. After meals, the nurse must tie the tube and fix it to the patient's head using a bandage.

The patient is allowed to sit up in his bed on the first day after the operation. He can leave his bed in two or three days, depending on his general condition.

INJURIES AND FOREIGN BODIES

Injuries to the larynx in peace time are rare. They are classified into open and closed; closed injuries are in turn divided into internal and external injuries. In open injuries, in addition to the larynx proper, the other organs of the neck are also damaged. Depending on the damaging factor mechanical, chemical and thermal affections are distinguished.

Open injuries and wounds of the larynx can be cut, stabbed, and gunshot. Cut wounds are inflicted by various sharp-edged tools. By the location of wounds they are classified as (1) wounds below the hyoid bone with incised thyrohyoid membrane; (2) infraglottic wounds.

Symptoms. The general condition of the wounded is always bad. Laryngeal stenosis, bleeding, fall of the arterial pressure and acce-

leration of the pulse are common symptoms. The body temperature can rise. Consciousness can be normal or dimmed, depending on the extent of damage. When inspecting the wound it is necessary first of all to assess bleeding: it can be profuse if the thyroid gland is injured; injury to the carotid arteries causes death in few seconds or minutes.

Treatment. At the first stage the treatment is surgical. It includes arrest of bleeding and replenishment of the blood loss, provision of respiration, and primary treatment of the wound. The respiratory function is of special importance. Tracheostomy, preferably the lower one, is usually performed. If located in the region of the thyrohyoid membrane, the wound should be sutured layer-by-layer, with obligatory suturing of the larynx to the hyoid bone using chromicized catgut or fascia taken from the lateral surface of the thigh. If the wound is located in the infraglottic region, a common layered suturing is sufficient.

The patient first should be fed only through a nasogastric tube that is introduced before suturing the wound in order to prevent infection of the injured tissues. The anti-inflammatory and general envigorating treatment should include large doses of antimicrobial and desensitizing preparations, and also preparations used to prevent shock.

Stab wounds are usually attended with difficult respiration due to laryngeal stenosis and emphysema of the soft tissues of the neck.

Treatment should in the first instance be aimed at restoring respiration. After primary treatment of the wound, antitetanus serum is administered. Anti-inflammatory therapy is then indicated.

Gunshot wounds of the larynx. These wounds are usually combined with the injury to the pharynx, the oesophagus, the thyroid gland, large vessels, nerves, the vertebral column, the skull, the spinal cord, and the brain. Gunshot wounds are classified as penetrating, blind, and tangential (oblique).

X-ray examination is very important for the diagnosis of gunshot wounds because the condition of the bony structures and the presence of foreign bodies can only be determined by this method.

Treatment of gunshot wounds includes (1) restoration of respiration, arrest of bleeding, primary treatment of the wound, and control of shock; (2) anti-inflammatory, desensitizing and envigorating treatment.

In order to restore respiration in gunshot wounds of the larynx, a tracheostomy should be performed. Bleeding is arrested by placing ligatures on the vessels in the wound, by ligating the

external and (in extreme necessity) of the common carotid artery. Common antishock measures should be taken.

The anti-inflammatory treatment includes administration of large doses of broad-spectrum antibiotics, semisynthetic antimicrobial preparations, sulpha drugs and desensitizing preparations.

Closed internal injuries to the larynx result from penetration of various foreign objects (e.g. bones, metal objects, and the like) into the throat. The laryngeal mucosa is often damaged by an unskilled physician during laryngoscopy or intubation anaesthesia. An intubation granuloma can form as a result of the irritating effect of the tube or its prolonged stay in the larynx. The most common site of granuloma is the free edge of the vocal fold because this is the point of the closest contact of the tube with the mucosa.

Symptoms. Injury to the laryngeal mucosa by a foreign object is characterized by painful swallowing, especially if the mucosa of the epiglottis or the arytenoid cartilage is affected. Oedema and infiltration often result in abscess, impeded respiration, and if inflammation spreads onto the adjacent organs and tissues (piriform recesses, cellular tissue of the neck, etc.) signs of dysphagia can develop. Due to severe pain the patient is unable to swallow saliva and holds his head in a fixed position. Pictures of the larynx and the neck (lateral views and, if necessary, contrast) are taken.

Treatment. When selecting therapeutic tactics, it is necessary to take into consideration the whole complex of anamnestic and examination findings. If respiration is moderately impeded by stenosis, and examination reveals a pronounced infiltration or an abscess in the outer ring of the larynx, it is necessary to open the abscess or incise the mucosa at sites of most pronounced swelling. In stenosis of the second and third degrees tracheostomy should be performed.

Big doses of broad-spectrum antibiotics and sulpha drugs are obligatory. If breathing is impeded by oedema, stenosis can be eliminated by medicinal preparations.

External closed wounds of the larynx. Contusion, compression, fractures of the laryngeal cartilages or the hyoid bone, and also separation of the larynx from the trachea are classified as external closed injuries to the larynx. These injuries can occur both at home and in industry. Closed injuries to the larynx are characterized by shock at the moment of injury which develops due to the reflex action through the cervical neurovascular

bundle, and severe pain in the throat during swallowing saliva. More severe cases are characterized by blood spitting (haemoptysis) and emphysema in the region of the neck which rapidly spreads onto the face, the abdomen and the spine. Respiration becomes difficult to complete stenosis.

Treatment. The patient with injured larynx should be taken to hospital immediately. During examination of the patient it is necessary to assess respiration: if respiration is difficult, tracheostomy should be performed. In order to remove shock, it is necessary to start the antishock therapy immediately (blood transfusion, administration of stimulants, vagosympathetic novocain block, etc.).

Food should be liquid and not irritating. If food gets into the airways, the patient should be fed through a tube.

Burns of the larynx can be of two types: chemical and thermal. Chemical burns of the larynx are caused by ingestion or inhalation of concentrated chemical agents such as acids or alkalies. The vestibular part of the larynx (epiglottis, arytenoid cartilages) are usually affected. At the site of contact with the chemical agent the injury is characterized by a local burn reaction of the mucosa which manifests itself as hyperaemia, oedema, and formation of a fibrinous coat. The framework of the larynx can be affected in severe cases.

Symptoms. The most important symptoms are functional disorders, such as difficult respiration and changed voice (to aphonia). Laryngoscopy reveals the location of the affection and its extent, changes in the glottis, the character of the oedema and the infiltration, fibrinous coat and its size. Diphtheria should be excluded in each particular case.

Treatment. The therapeutic tactics in burns of the larynx includes observation of special conditions by the patient and administration of the medicinal preparations. An obligatory condition is abstaining from talking for 10-14 days. Food should be warm, soft and contain little salt. The throat should be gargled with sage or camomile tea two times a day for 2-3 weeks. In the presence of foul breath and fibrinous coat on the mucosa of the mouth and the pharynx weak potassium permanganate solution should be used for gargling. Inhalation therapy with menthol, peach-kernel (persic) and apricot-kernel oil and antibiotics in combination with hydrocortisone suspension are very helpful. The course should include 15-20 procedures. Active anti-inflammatory and desensitizing therapy should be carried out.

Thermal burns of the larynx occur during inhalation of hot

vapours or gases. This type of affection is comparatively rare and is usually combined with affection of the pharynx.

The laryngoscopic picture is characterized mainly by oedema of the mucosa. The diagnosis is not difficult. Treatment of thermal burns is the same as treatment of chemical burns of the larynx.

Foreign bodies in the larynx, trachea and the bronchi. The incidence is higher in children. Foreign objects get into the child's airways due to careless eating and lack of care on the part of adults. Seeds of sunflower, melon, water melon, coins and pins most commonly get into the larynx.

Foreign bodies enter the airways of adults mostly due to careless use or misuse of such objects as needles, pins, hair pins. Vomitus, pieces of food, artificial teeth and the like objects can get into the bronchi in the state of alcoholic intoxication.

Another category are foreign objects that penetrate into the airways in gunshot, fragmentation wounds, and also wounds inflicted by cold steel.

Foreign bodies entering the lower respiratory tract usually cannot be expectorated, because at the moment of expiration the foreign body is tightly held between the walls of the bronchi (during inspiration the bronchus is dilated and during expiration it is narrowed).

Symptoms. The symptoms of foreign bodies presence in the airways depend on the properties of the foreign object and on the reaction of the patient's body. As a foreign object gets into the larynx, convulsive coughing develops. If the lumen of the glottis is closed completely, asphyxia develops immediately and the patient dies. If the lumen is only partly closed, the patient' voice becomes husky, he coughs and the respiration becomes difficult because of the oedema of the mucosa.

Roentgenoscopy and roentgenography help obtain accurate information on the properties of the foreign object and its location, and also determine the character of developing complications.

Diagnosis is established on the basis of anamnesis, the findings of the physical and X-ray examinations, and laryngoscopy. Infants are examined only by direct laryngoscopy, during which the foreign object can be removed from the trachea (Fig. 48).

Treatment consists in urgent removal of the foreign body from the airways. This manipulation is sometimes carried out under X-ray control. If a patient is cachectic or aged, or if the victim

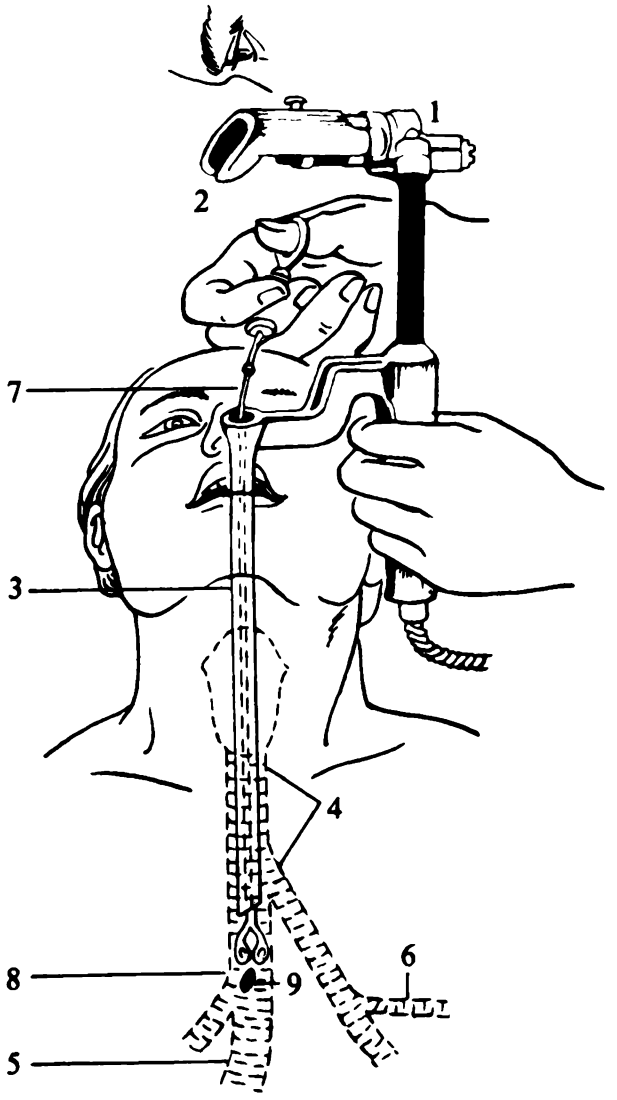

Figure 48
Removal of a foreign body from the right bronchus using a tracheobroncho-oesophagoscope:

1 – handle;
2 – mirror slit;
3 – tracheoscope;
4 – trachea;
5 and *8* – right bronchus branches;
6 – left bronchus branches;
7 – forceps;
9 – foreign body

is a child, the foreign body should be removed under anaesthesia. If respiration is strongly impeded, or in cases with asphyxia, tracheostomy should be done immediately, artificial respiration maintained, and lower tracheobronchoscopy performed using the Friedel apparatus.

Prophylaxis includes measures aimed at health education of the population: the danger of getting foreign bodies in the airways and possible complications should be explained.

Injuries to the trachea are less frequent than injuries to the larynx. This can be explained by its position, elasticity, and mobility. By location the injuries are divided into two groups: (1) injuries to the cervical part; (2) injuries to the thoracic part. This division is practically convenient because otorhinolaryngologists are engaged in treatment of the injuries to the cervical

Plate I. Choanal polyp

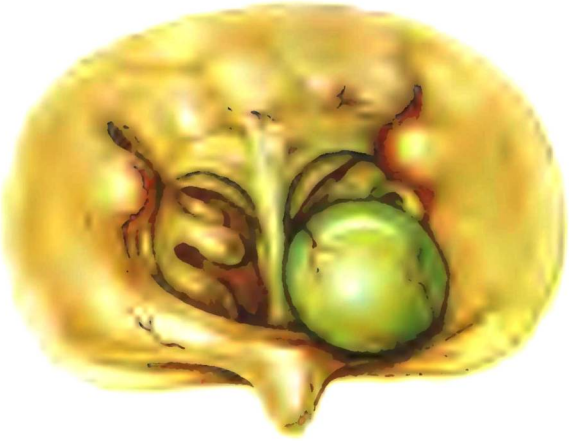

Plate II. Bilateral sinusitis as viewed during anterior rhinoscopy. The polyps and pus can be seen in the right side of the nose; pus emerging from under the middle concha can be seen on the left

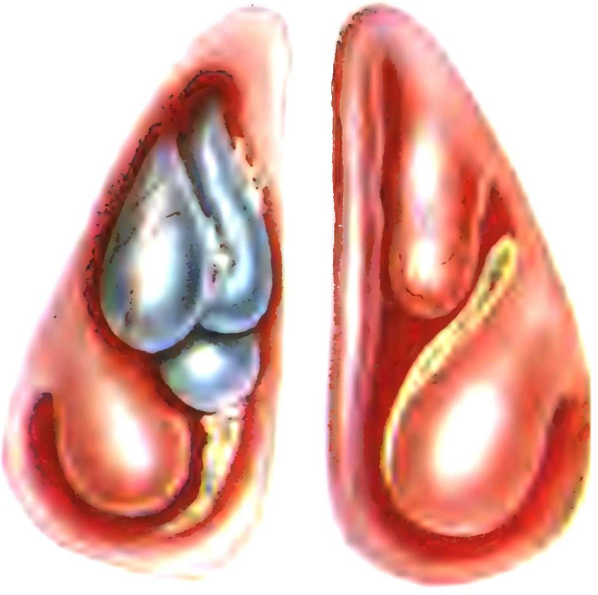

Plate III. Adenoids

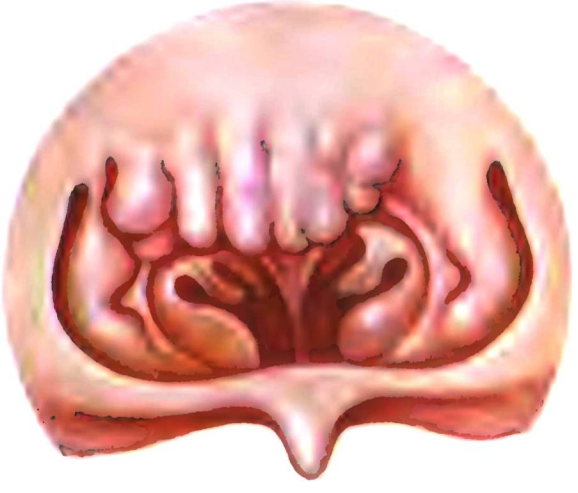

Plate IV. Inflammatory affections of the pharynx. Pharyngoscopic picture:

a – granular pharyngitis

b – follicular tonsillitis (right), lacunar tonsillitis (left)

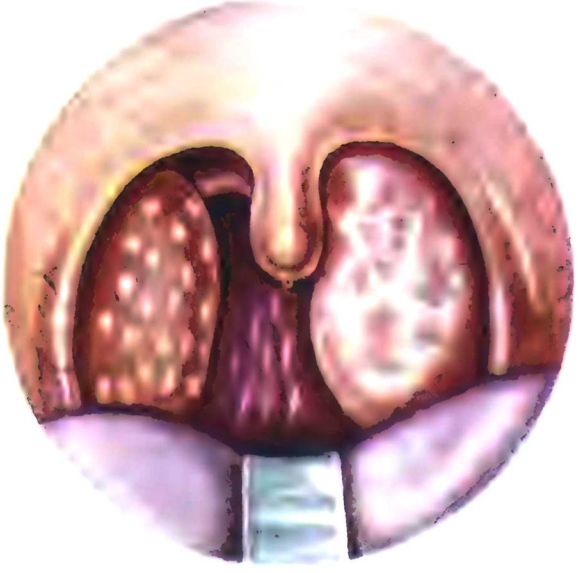

c – inflammation of the tubal elevations

d – retropharyngeal abscess

e – Zak's sign

f – Preobrazhensky's sign

g – Gize's sign

h – acute pharyngitis

i – hyperkeratosis

Plate V. Oedema of the larynx:

a – oedema of the epiglottis and the aryepiglottic folds;

b – oedema of the epiglottis;

c – oedema of the arytenoid cartilages and aryepiglottic folds

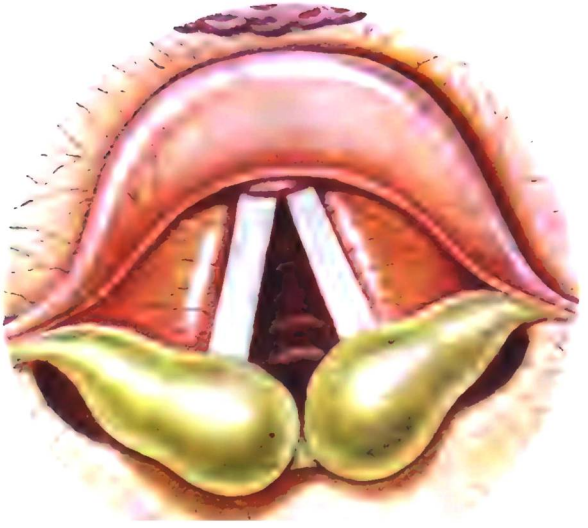

Plate VI. Acute laryngitis

Plate VII. Subglottic laryngitis (false croup)

Plate VIII. Laryngeal diphtheria

Plate IX. Barotitis (aero-otitis)

Plate X. Diffuse hyperaemia of the tympanic membrane (*a*); bulging tympanic membrane (*b*)

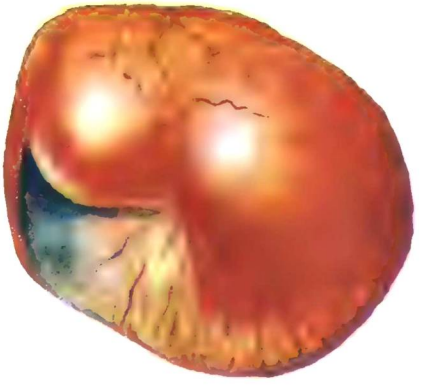

Plate XI. Exacerbation of chronic suppurative otitis media

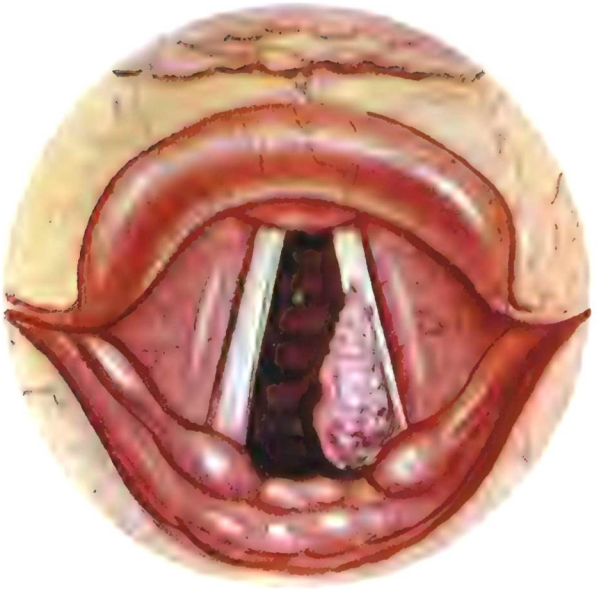

Plate XII. Laryngoscopic picture of laryngeal cancer

Plate XIII. Tuberculous otitis media

part of the trachea while treatment of the thoracic part of the trachea is the task of thoracic surgery.

Depending on the character of injury to the tracheal wall there can be penetrating and non-penetrating injuries.

Symptoms. A common sign of injury to the trachea is subcutaneous emphysema of the neck. In closed injuries emphysema is more pronounced and quickly developing. Another important sign is bleeding which can be internal and external. Internal haemorrhage is attended with constant coughing, stertorous respiration, and blood spitting. Impediment of respiration is usually insignificant in affections of the trachea.

Treatment. If respiration is difficult, a tracheostomy should be performed (below the wound), especially in the presence of increasing signs of subcutaneous emphysema, because otherwise the air will penetrate into the mediastinum. If respiration is not impeded in a cut or stab wound, bleeding should be arrested, and the wound sutured. If the oesophagus is also injured, a gastric tube should be inserted for nutrition. Penetration of food and saliva into the trachea should be excluded since pneumonia can develop. Antibiotics, sulpha drugs, and vitamins should be given.

OEDEMA OF THE LARYNX

Oedema of the larynx is a symptom of a disease. It can be inflammatory and non-inflammatory. Inflammatory oedema usually attends various diseases of the pharynx, larynx and other organs; it can develop in necrosis, acute and chronic infectious diseases associated with inflammation of the larynx, e.g. measles, scarlet fever, influenza, tuberculosis, scleroma, syphilis, etc. Injuries to the neck, burns of the larynx with hot food, acids or alkalies, or injuries caused by tracheobronchoscopy often cause oedema of the larynx as well. A special variety of oedema arises following radiotherapy of the organs of the neck.

Non-inflammatory oedema occurs in some forms of heart failure and in diseases of the liver and the kidneys. Quincke's oedema and allergic oedema can also be classified as this category of morbid conditions.

Symptoms. These depend on the degree of stenosis of the larynx and rapidity of its development. Inflammatory oedema of various parts of the larynx is characterized by pain on swallowing, the feeling of a foreign object in the throat, impeded respiration

(which can be impaired even more) and changed voice. If oedema develops rapidly, acute stenosis of the larynx can occur with pronounced signs of asphyxia endangering the patient's life.

Laryngoscopy reveals oedema of the affected parts of the larynx which appears as watery or jelly-like swelling (see Plate V).

Treatment. Outer respiration should be restored and possible asphyxia prevented. The patient must be taken to hospital immediately. Development of decompensated stenosis, and the more so of asphyxia, requires urgent tracheostomy, which is sometimes preceded by coniotomy.

Oedema of the larynx which does not cause severe stenosis (first and second degree) should be treated conservatively at hospital conditions.

The following treatment is recommended for inflammatory oedema of the larynx: (1) antibacterial preparations parenterally, after testing the patient for sensitivity to particular preparations; (2) 25 per cent pipolphen solution, 2 ml intramuscularly 2 times a day; 10 per cent calcium gluconate, 10 ml intramuscularly, once a day; 40 per cent glucose solution, 20 ml, and ascorbic acid, 5 ml intravenously, once a day; rutin, 0.02 g per os, 3 times a day; (3) hot bath for the feet (up to the knees) at 42-45°C for 5 minutes; (4) warming compress on the neck or mustard plasters for 10-15 minutes, 1-2 times a day; (5) intranasal block, once a day, with 1 per cent procaine solution, 2 ml into the anterior end of the middle concha; (6) terpin hydrate 0.25 g, codeine phosphate 0.015 g one tablet 3 times a day; inhalation of solutions (1 ampoule of chymotripsin, 1 ampoule of 3 per cent ephedrine solution, 15 ml of oil or isotonic sodium chloride solution, 2 times a day for 10 minutes) should be given for cough, expectoration of sputum, and crusts in the larynx and trachea.

The following medicines are given for allergic oedema: (1) 3 per cent prednisolone hydrochloride solution, 1 ml (30 mg) intramuscularly. If oedema is severe and stenosis of the larynx intensifies, the dose of prednisolone is doubled or tripled. Repeated administration is possible in 5-6 hours; (2) a more prolonged effect is produced by intravenous drip (instead of intramuscular administration) of the following: 200 ml of isotonic sodium chloride solution, 30 mg of prednisolone, 2 ml of diprazine, 10 ml of a 10 per cent calcium chloride solution, 1 ml of a 5 per cent ephedrine hydrochloride solution, and 1 ml of a 0.025 per cent strophantine solution; (3) the same therapy as for inflammatory

oedema; (4) if arterial pressure falls, 1 ml of 1 per cent phenylephrine hydrochloride should be given subcutaneously; (5) humidified oxygen should be given to breathe for 1 hour 3-4 times a day. Food should be cold and liquid; intake of liquids should be restricted, talking avoided, physical load limited. Frusemide and mannitol can be administered with obligatory control of concentration of sodium and potassium salts in the patient's body.

ACUTE LARYNGITIS

Acute catarrhal laryngitis. Acute inflammation of the laryngeal mucosa is usually extension of catarrhal inflammation of nasal and pharyngeal mucosa, e.g. in measles, pertussis, influenza, typhus, rheumatism, and some other diseases.

Symptoms. The disease is characterized by hoarse voice, tickling and dryness in the throat. The body temperature is usually normal and less frequently it rises to subfebrile. Simultaneously with the subjective signs, develops also dry cough, which later turns into wet cough. Voice production disturbances are characterized by various degrees of dysphonia to complete aphonia. Respiration is sometimes difficult because of accumulation of mucopurulent crusts and swelling of the mucosa (Plate VI).

Laryngitis in children should be differentiated from common diphtheria. Pathological changes in diphtheria are characterized by fibrinous inflammation with formation of greyish membranes closely adhering to the underlying tissues.

Treatment. The larynx should first of all be spared. The patient is not allowed to talk until acute inflammation subsides. Spicy or cold food, alcoholic drinks and smoking are prohibited. A warming compress should be applied to the neck. Medicamentous therapy is directed at eliminating inflammation in the larynx and preventing complications. Solutions of antibiotics (300 00 U of penicillin, 300 000 U of streptomycin or 200 000 U of sigmamycin, and 10 ml of isotonic sodium chloride solution) should be inhaled 2 times a day for five minutes (not less than 10 sessions). In some cases it is recommended to add 2 ml (60 U) of hydrocortisone suspension to the above mentioned mixture. Other antibiotics can also be given by inhalation, but in all cases the patient's sensitivity to the drug should be tested. In the presence of crusts, it is useful to administer 1 g of vegetable (persic) oil into the larynx, once a day for 7 days. Counterattracting hot foot baths, mustard plasters on the calves, and inhalation

of humidified oxygen are recommended to children. Air in the room where a sick child is treated should be moist.

When acute catarrhal laryngitis subsides, the upper airways should be thoroughly inspected and, if infectious foci are found in the teeth or tonsils, given the appropriate treatment.

Subglottic laryngitis (false croup) is a variety of acute catarrhal laryngitis which develops in the infraglottic space. It occurs in children ageing from 2 to 5 and is associated with the anatomy of their larynx (narrow lumen and loose connective tissue in the infraglottic space). The onset of the disease is as a rule connected with acute inflammation of the mucosa of the nose or the pharynx. False croup occurs mostly in children who tend to develop laryngospasm and suffer from diathesis.

Symptoms. The onset of the disease is sudden: an attack of barking cough occurs during night sleep. The child wakes up and tosses in his bed. Breathing becomes very difficult and whistling; inspiratory dyspnoea is pronounced. The nails and the visible mucosa become cyanotic. The child is frightened and this intensifies coughing.

Inspection of the child reveals retraction of the soft tissues of the jugular fossa, supra- and subclavicular spaces, and the epigastric region. This condition lasts from a few minutes to half an hour; the child then sweats excessively and his respiration becomes almost normal. The child falls asleep and feels well in the morning. The voice normalizes but in some children it remains hoarse. Another attack can occur in few days or in 1-2 weeks. Dyspnoea and cough can be more persistent.

The laryngoscopic picture in subglottic laryngitis is characterized by ridge-like swelling of hyperaemic mucosa in the infraglottic compartment. The ridges protrude from under the vocal folds to narrow significantly the laryngeal lumen and thus impeding respiration (Plate VII).

Treatment includes common hygienic measures, ventilation and humidification of air in the room, and therapeutic measures. The child is given warm milk and mineral water. Poultice and mustard plasters should be applied to the neck. Hot foot baths are also effective. Expectorants should be given to thin sputum.

The attack of asphyxia can be aborted by touching the posterior wall of the pharynx with a spatula thus stimulating the vomiting reflex. If this measure fails and asphyxia becomes threatening, tracheostomy is indicated. Intubation should be done for special indications because sores can be formed on the laryngeal mucosa.

In severe cases, direct laryngoscopy is performed with treatment of the subglottic mucosa with vasoconstrictors. If this measure is insufficient, tracheostomy should be performed without removing the laryngoscope.

Acute tracheitis. Acute tracheitis rarely occurs as an independent disease, and is usually secondary to acute rhinitis, pharyngitis, or laryngitis. The incidence is higher in autumn, winter and spring. Viral infection (following chilling) is a common cause of acute tracheitis.

Morphological changes in the trachea are characterized by oedema, infiltration and hyperaemia of the mucosa.

Symptoms. The onset of the disease is marked by frequent attacks of cough, especially during night. Cough is first dry and then sputum is expectorated. Attacks of cough are often followed by retrosternal and laryngeal pain. The voice is usually hoarse.

Treatment is the same as for acute catarrhal laryngitis. The condition of the lungs should be constantly controlled because bronchopneumonia is likely to develop in severe cases; capillary bronchitis can occur in children.

Haemorrhagic laryngitis develops mostly as a complication of toxic influenza, less frequently in diseases of the haemopoietic organs, cardiovascular system, or the liver, in some other morbid conditions and in pregnancy.

Morphologically the process is characterized by haemorrhage into the thickness of the laryngeal mucosa, especially into the vocal and aryepiglottic folds (in the form of petechiae and large maculae).

Symptoms. A permanent symptom is dry cough, usually in the morning. Later streaks of blood appear in the sputum during expectoration of crusts; scarlet blood is expectorated less frequently. Haemorrhage can develop in some cases with subsequent asphyxia. Among transient symptoms are dryness and the feeling of a foreign body in the throat.

Treatment. The patient must stay in his bed and rest his voice. Diet should be sparing; smoking is prohibited.

A 10 per cent calcium chloride solution (a tablespoonful 2-3 times a day), vitamin K (a tablet of 0.015 g 2 times a day), and an expectorant are quite effective to arrest small haemorrhage. If bleeding is more pronounced, an ice bag should be applied to the neck and 50-100 ml of blood should be transfused; 10 ml of a 10 per cent calcium chloride solution should be

administered intravenously. The subsequent treatment is the same as for acute laryngitis.

Submucous laryngitis (angina laryngea). This is an acute inflammation of the lymphoid tissue of the larynx. The disease can occur after chilling, influenza, injury to the larynx with foreign objects, and in some other conditions.

Symptoms. These are substantially the same as in inflammation of the palatine tonsils. The patient complains of painful swallowing, painful turning of the head, and dry throat. The voice is changed in some cases; the larynx can be stenosed significantly to impede respiration. The body temperature is often 37.5-38°C; the pulse rate is accelerated.

Palpation of the neck reveals enlarged and very tender lymph nodes, usually on one side. Laryngoscopy shows hyperaemia and infiltration of the laryngeal mucosa on one side or over a circumscribed area. Separate follicles with punctate patches can sometimes be seen. If the disease runs a prolonged course, an abscess can develop on the tongue surface of the epiglottis, the aryepiglottic fold, etc.

In some cases the disease is diagnosed erroneously as acute infiltrative laryngitis.

Treatment is the same as for acute catarrhal laryngitis, but antibacterial preparations should be given in bigger doses. Tracheostomy is indicated for significant stenosis.

Bed rest is indicated. The diet should be sparing. Thermotherapy and alkaline inhalations are prescribed. Anti-inflammatory therapy includes administration of sulpha drugs, antibiotics, and (obligatory) desensitizing preparations.

Phlegmonous laryngitis is a suppurative inflammation of the submucous layer, possibly of the muscles, tendons, and the laryngeal perichondrium. The disease is rare. Its aetiological factor is infection (staphylococcus, streptococcus, etc.). The disease occurs mostly in males ageing from 20 to 35. The affection can be circumscribed and diffuse.

Symptoms. The patient complains of severe pain on swallowing, especially if the phlegmona is located on the tongue surface of the epiglottis and the arytenoid cartilages. If the glottis tissues are affected, the first symptom is hoarse barking cough and respiratory distress (to asphyxia). The body temperature is high. Examination reveals inflammation of the regional lymph nodes. Laryngoscopy reveals hyperaemic and infiltrated laryngeal mucosa with sites of necrosis. The formation of an abscess is

characterized by circumscribed swelling; pus can be seen through the thinned mucosa. Mobility of some laryngeal structures is strongly restricted.

Treatment. The patient must be taken to hospital. Tracheostomy is indicated for increasing stenosis. Local and general antibacterial and anti-inflammatory therapy is started at the early period of the disease. If an abscess is present, it should be opened surgically. If the phlegmona spreads onto the soft tissues of the neck, external incisions are made to ensure adequate drainage of suppurative cavities. Bed rest is obligatory.

Laryngeal diphtheria (membranous croup) is usually the result of the process extending from the nose or the pharynx. But in some cases this is a primary disease. Diphtheritic inflammation rapidly spreads over the entire mucosa of the larynx (Plate VIII).

Symptoms. The first signs are husky voice or aphonia and specific (barking) cough. Laryngoscopy easily reveals diphtheritic greyish-white or dirty-grey thick fibrinous membranes which cover the laryngeal surface to a greater or lesser extent (true croup). The mucosa which is free from these membranes is hyperaemic and swollen. Simultaneously with these first signs, symptoms of rapidly intensifying stenosis develop; they are attended by marked inspiratory dyspnoea. In severe cases, if no medical aid is given in due time, asphyxia develops. The general reaction of the body is usually marked: the temperature rises to subfebrile or febrile; inflammatory changes appear in the blood; the patient is weak; his appetite and sleep are deranged.

Treatment consists in urgent administration of diphtheria antitoxin (Besredka's antivirus), isolation and hospitalization of the patient in an infectious department. Sanitary and epidemiological measures should be immediately taken. Tracheostomy is indicated for stenosis; intubation is sometimes necessary. In addition to the specific treatment of diphtheria, the mucosa of the nose and the pharynx can be irrigated with disinfectant solutions (potassium permanganate, furacin). Chymotrypsin in isotonic sodium chloride solution and oil solutions of antibiotics should be instilled into the larynx. Oil-alkaline solutions are indicated for inhalation to facilitate separation of the membranes. Expectorants are given per os. The function of the cardiovascular system should be constantly controlled, and the necessary preparations given whenever necessary.

FUNGAL DISEASES OF THE LARYNX

Mycotic diseases of the larynx occur more frequently than they are diagnosed. Males are mostly affected.

Fungi of the *Candida* genus prevail in the aetiology of the disease, but moulds can also be the causative agents. Laryngites of this aetiology are long-standing.

The *clinical* picture of the disease depends on the location of the affection.

The *symptoms* are the same as in inflammation. The main complaint of the patient is periodic tachypnoea which depends on the cyclic character of the fungal growth.

Diagnosis is based on the laboratory tests. The disease should be differentiated from newgrowths and tuberculosis.

Treatment. This includes inhalation of nystatin sodium salt solution (300 U/ml: 75 mg of the powdered nystatin sodium salt are dissolved in 5 ml of distilled water at a temperature of 25° C). The procedure should last for 15-20 minutes. The course includes 12-15 inhalations; it should be repeated at a month interval. If this measure is not effective enough, a sodium salt of levorin can be used for inhalation (200 000 U per inhalation, 2 times a day). The course is repeated as in the case with nystatin. Moreover, inhalation of a 0.1 per cent aqueous solution of gentian violet is recommended (5 ml for a procedure during the course of 10-12 days).

CHRONIC LARYNGITIS AND TRACHEITIS

Chronic inflammatory diseases of the larynx and the trachea are in the majority of cases secondary to acute inflammations.

Three forms of chronic inflammatory diseases of the larynx and the trachea are now distinguished: catarrhal, hyperplastic, and atrophic.

Chronic catarrhal laryngitis is in most cases secondary to acute laryngitis. The main aetiological role of this pathology in singers, actors, lecturers, etc. is the occupational overload on the vocal apparatus.

Laryngoscopy reveals congestive hyperaemia of the laryngeal mucosa, which is more pronounced in the region of the vocal folds; blood vessels are often dilated.

Treatment is aimed at eliminating the aetiological factor. The patient must rest his voice. Local therapy includes instillation of an antibiotic solution containing hydrocortisone suspension

(5 ml of isotonic sodium chloride solution, 150 000 U of penicillin, 150 000 U of streptomycin, and 30 mg of hydrocortisone suspension). This solution is instilled into the larynx once a day in a dose of 1.5-2 ml. The same mixture should also be given by inhalation 2 times a day (the isotonic sodium chloride solution and the antibiotics are taken in doubled quantities; the length of each inhalation is 3 minutes). The course includes 10 sessions.

This course can be followed, if necessary, by inhalations of a 5 per cent oil solution of citral (1-2 inhalations daily for 10 days). The use of only oil and alkaline-oil inhalations should be limited, because these preparations have an adverse effect on the ciliated epithelium (inhibiting its function); in addition, alkali has an inhibiting effect on the function of the glands in the mucosa of the upper airways.

Climatotherapy is very important to control chronic catarrhal laryngitis, because favourable climatic conditions can facilitate recovery of patients with catarrhs.

Chronic hyperplastic laryngitis is characterized by hyperplasia of the laryngeal mucosa. Local and diffuse forms of the disease are distinguished by the extent of involvement.

Symptoms. The main complaint of the patients is hoarseness and even aphonia, which are usually due to uneven thickening of the vocal folds and paresis of the vocal muscles. Symptoms of catarrhal laryngitis join during exacerbations. Direct and indirect laryngoscopy reveal hypertrophy of the mucosa which is usually symmetrical on both sides of the larynx and in the interarytenoid notch. This hyperplasia can however be malignant and the diagnosis of chronic hyperplastic laryngitis should be established not only by observing the clinical signs of the disease but also by the histologic and cytologic findings.

Treatment is, in the first instance, directed at removing the causative factors; talking must be prohibited. Exacerbations are treated like acute catarrhal laryngitis. If mucosal hyperplasia is significant, a 1-2 per cent silver nitrate solution is applied every other day during the course of 2 weeks. Application of extreme cold to hyperplastic mucosa of the larynx is also effective.

Chronic atrophic laryngitis. Atrophic laryngitis is usually connected aetiologically and pathogenetically with atrophy of the nasal and pharyngeal mucosa. It is often secondary to preceding diphtheria or scarlet fever. Pollution of air with dust or gases, smoking and abuse of alcohol are among the provoking factors.

Symptoms. Patients complain of dryness, tickling and the feeling

of a foreign body in the throat, and progressing dysphonia. In the early period of the disease laryngoscopy reveals bright hyperaemia of the mucosa which looks lustrous. Hyperaemia subsides at later stages and tenacious secretion appears, which thickens into dark-green crusts in the larynx. On coughing-up streaks of blood can be seen in the expectorated sputum due to destruction of the laryngeal epithelium during cough.

Treatment. The patient must not smoke or take irritating food; he should rest his voice. Preparations thinning sputum and facilitating its expectoration should be given. Throat irrigation and inhalations of an isotonic sodium chloride solution should be performed (200 ml of isotonic solution, 5 drops of a 10 per cent iodine tincture). The irrigations and inhalations are performed 2 times a day using 30-50 ml of the solution for a session. The course lasts 5-6 weeks. The procedures can be done at home in the morning and in the evening. Oil-alkaline inhalations are carried out for 3-5 days only in the presence of tenacious mucus and crusts in the larynx. A 1-2 per cent oil solution of menthol should be inhaled daily during 10 days. This preparation can also be instilled into the larynx (menthol has weak irritating and disinfecting properties and therefore the patient's sensitivity to the drug should be checked). Concurring atrophic process in the larynx and the pharynx can be effectively treated with submucous injection (into the lateral portions of the posterior wall of the pharynx) of a novocain and aloe solution (2 ml of a 2 per cent novocain solution and 2 ml of aloe, administered in a dose of 2 ml into each side every other day). In order to stimulate the action of the glandular apparatus of the mucosa, 8 drops of a 30 per cent potassium iodide solution should be given per os 3 times a day during two weeks (the patient should preliminarily be tested for iodine sensitivity).

CHONDROPERICHONDRITIS OF THE LARYNX

The disease is associated with spreading of the inflammation from the soft tissues onto the cartilage. Acute and chronic processes are distinguished.

Symptoms. These mainly depend on the location of the focus. Indurated soft tissues usually circumscribe the inflamed part of the cartilage; external and internal purulent fistulae are periodically formed. Laryngoscopy reveals indurated and oedematous areas

of the mucosa, which narrow the lumen of the larynx. The disease is usually long-standing; it can persist for several months and even years.

Treatment of acute chondroperichondritis includes administration of big doses of antibiotics and sulpha drugs which eliminate inflammation. Physiotherapy should be prescribed depending on the character of the inflammation: UV light, UHF- and SHF-therapy, ion-galvanization of the larynx with calcium chloride, chymotrypsin, and potassium iodide; warming compresses are effective. The patient with chondroperichondritis should be given pasty non-irritating food. Tube feeding is not recommended, because the gastric tube can irritate the laryngeal tissues. Chondroperichondritis of the arytenoid cartilage following tracheostomy, or arising due to protrusion of the cartilage into the tracheostoma, or due to pressure of the tracheostomy tube on the cartilage, should be treated by placing the tracheostoma on the lower portions of the trachea.

The general reactivity of the body can be increased by haemotransfusions, autohaemotherapy, and biological stimulants (aloe, vitreous body, etc.). Surgical intervention is indicated for an abscess which should be emptied to remove the necrotized tissues. The presence of fistulae is also an indication for surgery, by which the fistula is opened and necrotized tissue removed.

STENOSIS OF THE LARYNX

Stenosis of the larynx is the narrowing of its lumen interfering with normal passage of air to the dependent airways.

Acute stenosis. This is an acute narrowing of the airways in the larynx with immediate severe impairment of the vital functions to their complete inhibition and death of the patient.

Acute stenosis occurs suddenly or develops within a comparatively short period of time. It is usually a symptom of many diseases. Stenosis is in most cases reversible.

The main pathophysiological factors that should be assessed immediately in acute stenosis of the larynx are the following: (1) the degree of external respiratory insufficiency; (2) the body reaction to oxygen deficit.

The body reserves cannot be realized during acute development of stenosis, and this can account for paralysis of this or that vital function. The adaptation reactions of the body are respiratory, haemodynamic, blood and tissue reactions. The respiratory

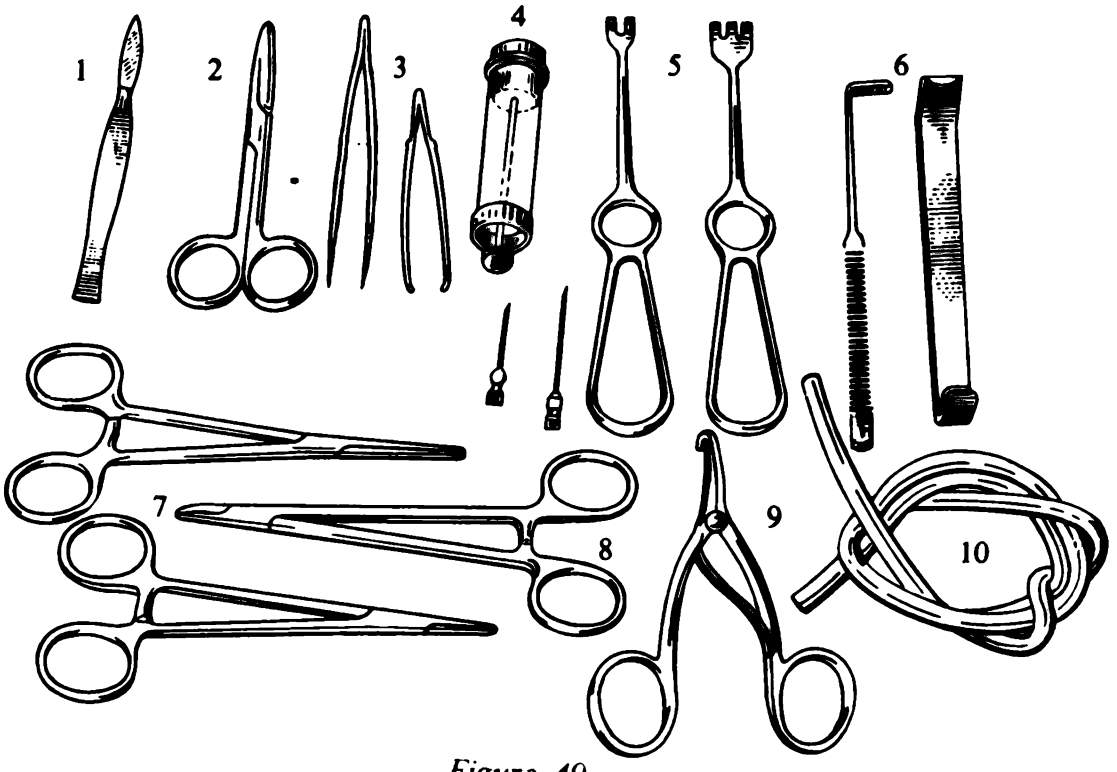

Figure 49
Tracheostomy tools:

1–scalpel;
2–scissors;
3–forceps;
4–syringe and needle;
5–sharp hooks;
6–blunt hooks;
7–clamps;
8–needle holder;
9–tracheostomic dilator;
10–suction tube

reaction is manifested by dyspnoea which increases ventilation of the lungs due to deeper breathing and higher respiratory rate. The haemodynamic compensatory reactions are characterized by tachycardia and increased vascular tone, which increase the minute blood volume 4 or 5 times.

These mechanisms can to a certain degree lessen hypoxia and hypercapnia; insufficient lung ventilation can be compensated for on the condition that a certain minimum volume (individual for each particular patient) of air is inhaled. In these conditions, increasing stenosis induces severe pathological reactions.

Acute stenosis of the larynx can be caused by local inflammatory diseases such as the laryngeal oedema, acute infiltrative or abscessing laryngitis, chondroperichondritis of the larynx or submucous laryngitis, local non-inflammatory processes, various injuries, foreign bodies, etc., acute infectious diseases such as measles, scarlet fever, diphtheria and the like, systemic diseases of the body such as diseases of the heart and vessels, of the lungs, the kidneys, etc. Depending on the degree of stenosis, stridor develops. Examination reveals retraction of the supraclavi-

cular fossae and the intercostal spaces; respiratory rhythm becomes upset. All these symptoms are associated with increasing negative pressure in the mediastinum. A patient with pronounced stenosis develops fear and motor excitation (the patient tosses in his bed and tries to run). The face is hyperaemic, the patient perspires; the heart activity and the secretory function of the stomach and the excretory function of the kidneys are upset.

If stenosis persists, the pulse is accelerated, the lips, the nose and the nails become cyanotic due to accumulation of carbon dioxide and the oxygen deficit. Inspiratory dyspnoea develops simultaneously.

The following stages can be classified in the *clinical course* of stenosis: stage I, compensation; stage II, subcompensation; stage III, insufficiency or decompensation; and stage IV, asphyxia.

At the stage of compensation the patient does not develop respiratory distress at rest, but tachypnoea develops during walking; the width of the glottis is 6-7 mm.

At the stage of subcompensation the patient develops inspiratory dyspnoea at rest, with involvement of the accessory muscles in the respiratory act; the intercostal spaces, soft tissues of the jugular and the supraclavicular fossae are retracted; stridor, pallor and restlessness are characteristic. The glottis width is 4-6 mm.

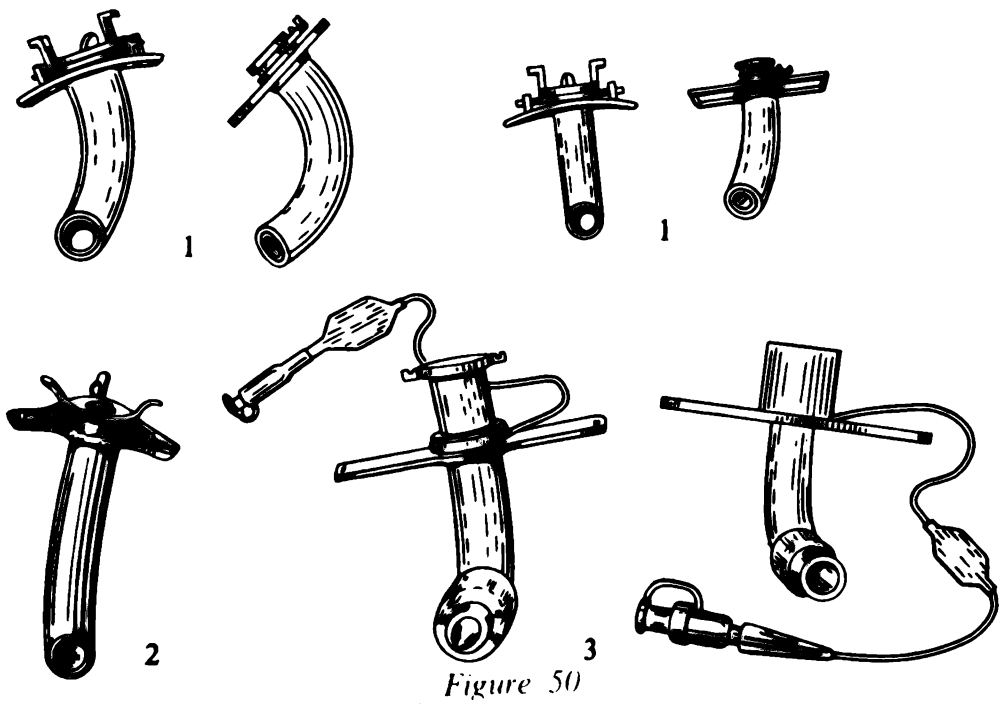

Figure 50

Tracheostomy tubes:

1 - tephlon;
2 - stainless steel;
3 - thermolabile plastic with an inflatable cuff

The insufficiency stage is characterized by shallow and accelerated respiration; the patient assumes a forced position (half-sitting in his bed and holding fast on the headrest or some other object). The larynx moves to maximum possible distance up and down. The face is pale and cyanotic; the patient is frightened, he perspires; his lips, the nose tip and the terminal phalanges are cyanotic; the pulse is fast. The glottis is 2-3 mm wide.

At the stage of asphyxia, respiration is hardly possible and discontinues at any moment. The width of the glottis is about 1 mm. The heart activity is distressed, the pulse is fast and thready, the skin is grey and pallid. In severe cases the patient is unconscious; exophthalmos is characteristic; the patient urinates and defaecates involuntarily; death ensues quickly.

Treatment depends on the cause and stage of acute stenosis. The compensated and subcompensated stages can be treated with medicinal preparations: stenosis is eliminated by the methods described for the treatment of laryngeal oedema. Decompensation (stage III) should be treated surgically: immediate tracheostomy is indicated. Asphyxia (stage IV) requires urgent coniotomy and then tracheostomy. Intubation is now rarely used because of the difficulties associated with engorgement of the laryngeal tissues; besides, it is less efficacious than tracheostomy. The patient can be intubated with elastic tubes used for intratracheal anaesthesia in intensive therapy departments (Figs 49, 50, 51).

Chronic stenosis arises due to persistent morphological changes in the larynx and the adjacent organs and tissues. As a rule, chronic stenosis develops slowly and gradually.

Causes of chronic stenosis of the larynx are quite varied. Common causative factors are (1) chondroperichondritis (traumatic, infectious, radiation); (2) disturbed mobility of the cricoarytenoid joint; (3) dysfunction of the inferior laryngeal nerves due to toxic neuritis, following strumectomy, compression by a tumour, and the like; (4) tumour, tuberculosis, syphilis, or scleroma.

Patients with chronic stenosis of the larynx often develop bronchitis and emphysema due to long-standing hypoxia; bronchopneumonia is frequent in children. The heart is enlarged and the myocardium hypertrophied. Prolonged presence of a tracheostomy tube causes sores, granulation and scars by the margins of the tracheostoma or in the trachea (at the lower end of the tube). These affections narrow the tracheal lumen and are therefore very dangerous.

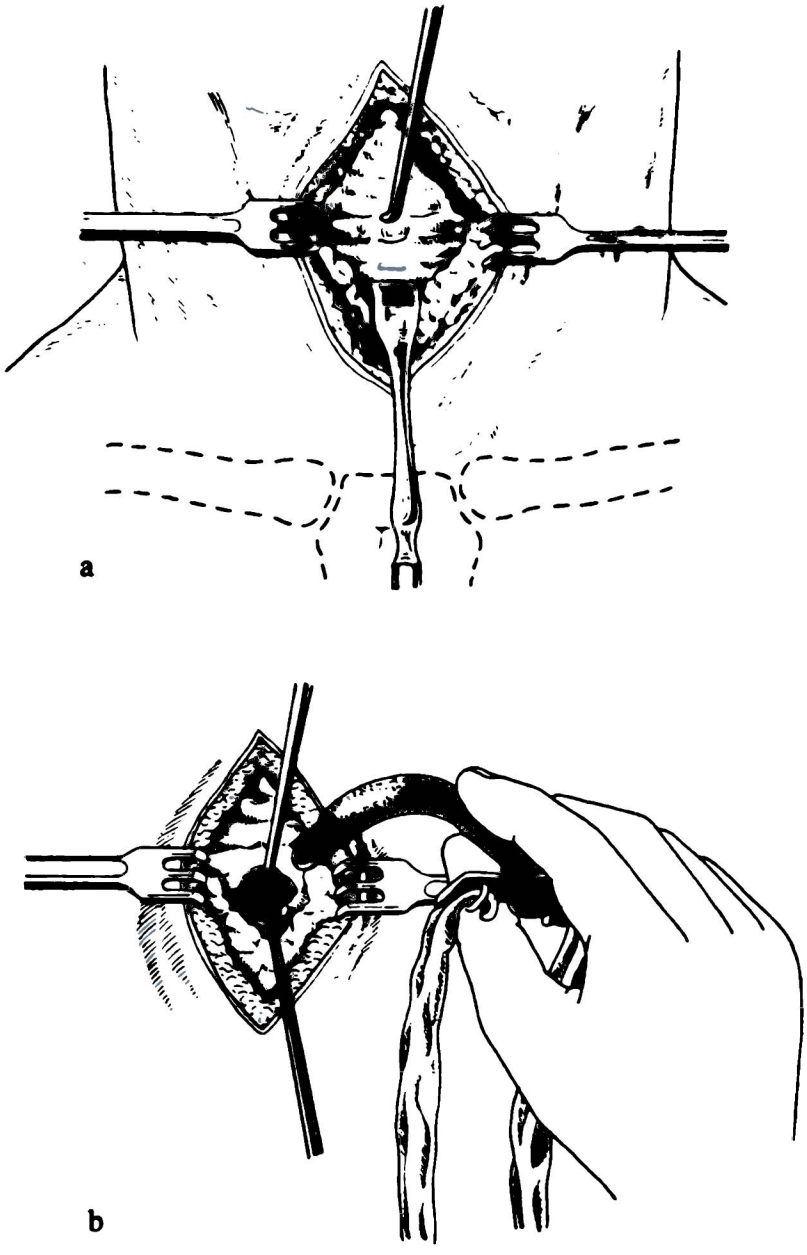

Figure 51
Longitudinal-transverse tracheostomy:

a – before incision of the trachea; *b* – introducing a tracheostomy tube

Treatment of chronic (cicatricial) stenosis is often very difficult and in some cases the lumen of the larynx is restored to normal size only after a prolonged treatment. Special dilators are used for regular artificial dilatation of the stenosed larynx. Laryngostomy and prolonged (for some months) dilatation of the larynx by T-tubes (better plastic) give more reliable results.

DISORDERS OF LARYNGEAL NERVES

Sensory and motor disorders of the laryngeal nervous apparatus are distinguished.

Disorders in the sensibility can be central and peripheral. Central disorders cause bilateral affections. The only exception is hysteria. The sensory disorders are anaesthesia, hyperaesthesia and paraesthesia.

Anaesthesia usually occurs in injuries to the larynx and the superior laryngeal nerve. Surgical intervention on the organs of the neck can also cause anaesthesia. Anaesthesia usually causes an insignificant subjective feeling. But in some cases it can be dangerous because food and liquid can pass into the airways.

Hyperaesthesia can be of various intensity. In some cases it can take the course of neuralgia. If sensitivity increases, perverted sensations may appear (paraesthesia). Hyperaesthesia is usually caused by the systemic nervous diseases (neurasthenia, hysteria) or changes in the peripheral nerves of the mucosa. The disorder is characterized by the tingling sensation when breathing and talking; sometimes the patient feels an urge to cough-up mucus. Children can feel like vomiting.

Paraesthesiae can be manifested by various sensations such as burning, tingling, foreign body in the throat, spasm, and the like.

Treatment. This includes measures acting on the nervous system, such as immersion and pine sedative baths, vitamin therapy, aloe, rational labour and leisure, etc. Novocain block is effective when administered into the ganglion or the conduction routes.

Physiotherapy of peripheral affections includes intra- or extra-laryngeal galvanization, diathermia, and the like.

Motor disorders (Fig. 52) of the larynx are manifested by partial or complete absence of function.

The larynx is innervated by the superior and the recurrent laryngeal nerves. Paralysis of only the superior laryngeal nerve occurs as anaesthesia of the laryngeal mucosa.

Paralysis of the recurrent laryngeal nerve is a common affection. This is explained by the large size of this nerve and its topography: adjacency to many organs of the neck and the chest whose diseases can upset the function of this nerve.

Paralysis of the recurrent nerve can be caused by the aneurysm of the arch of the aorta (for the left nerve) and of the right subclavian artery (for the right nerve), dilatation of the heart, newgrowths of the mediastinum, tumours of the thyroid gland,

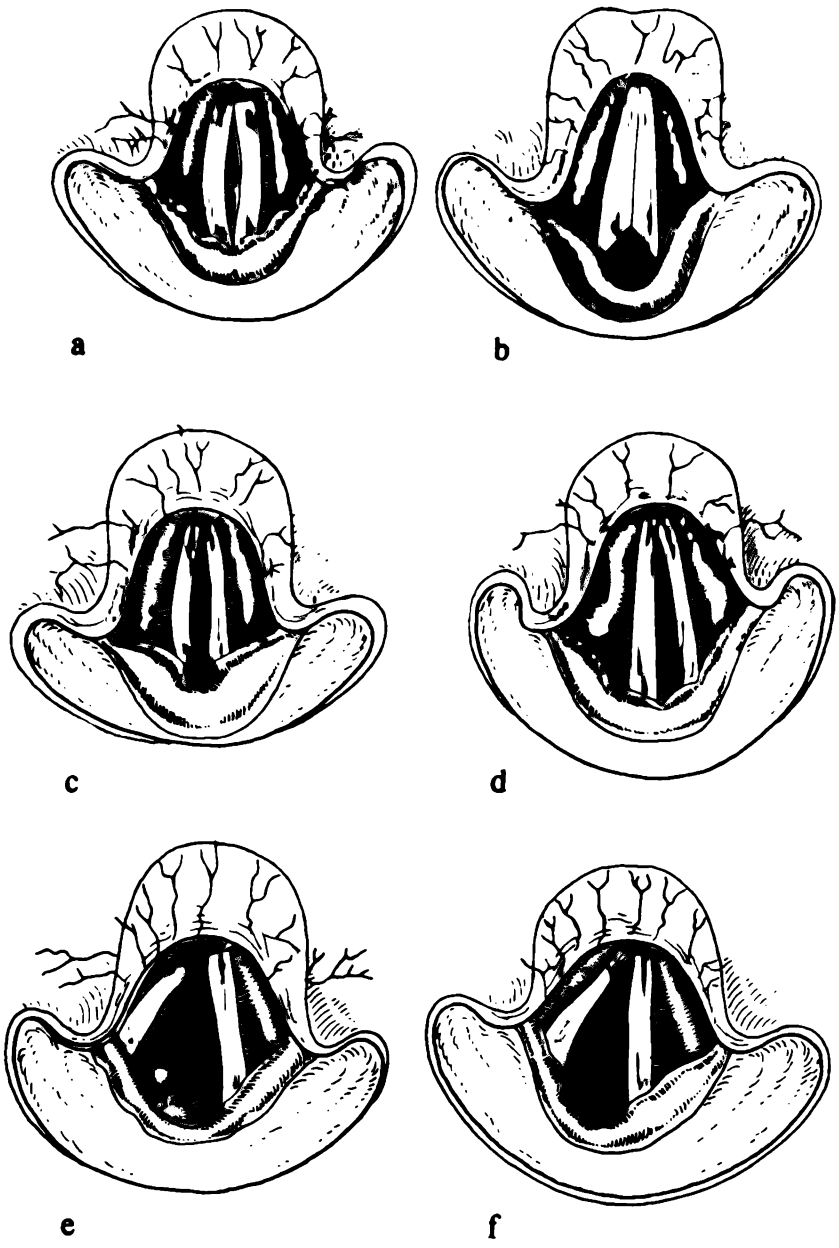

Figure 52
Paralysis of the laryngeal muscles:

a - bilateral paralysis of the thyroarytenoid muscle during phonation;
b - bilateral paralysis of transverse arytenoid muscle;
c - combined affection of these muscles;
d - paralysis of the left recurrent nerve during phonation;
e - same during inspiration;
f - paralysis of the left posterior cricoarytenoid muscle during inspiration

lymph nodes of the neck and the oesophagus, various intoxications, and surgical interventions. The left recurrent nerve is affected more frequently.

Unilateral paralysis of the recurrent nerve causes hoarseness because the vocal fold on the involved side becomes immobile and

is fixed in the middle position; the glottis is thus only half contracted, while respiration is virtually not upset. In bilateral paralysis of the recurrent laryngeal nerves, both vocal folds are set in the central position and thus impede respiration (stenosis of the larynx, degrees II and III). The voice remains sounded.

Treatment should be directed at elimination of the main disease. Local disorders in the form of difficult breathing sometimes require surgical intervention (tracheostomy). Electrotherapy (electrophoresis with medicinal preparations) can sometimes be carried out.

Review Questions

1. What cartilages make the framework of the larynx?
2. What functions of the larynx are upset by the injury to the vestibular part?
3. How can laryngeal oedema be treated?
4. Tell the difference between false and true croup.
5. How many degrees of stenosis of the larynx do you know?
6. How can false croup be treated?

Problem

A patient complains of hoarseness which persists for 2 years. Laryngoscopy reveals angioma at the free edge of the vocal fold. What treatment should be prescribed?

DISEASES OF THE EAR

CLINICAL ANATOMY

The external ear (auris externa) includes the auricle (pinna) and the external acoustic (auditory) meatus. The auricle is located between the temporomandibular joint anteriorly and the mastoid process posteriorly. The external concave and internal convex surfaces are distinguished in the auricle. The framework of the auricle is elastic 0.5-1-mm thick cartilage, which is covered on both sides with perichondrium and the skin. The auricle consists of a helix which runs by its external margin, and the anthelix located inside the helix. A cartilaginous projection, found anteriorly to the external auditory meatus, is known as tragus. Another projection, located posteriorly to the tragus, is known as antitragus. A notch (incisura intertragica) separates the tragus from the antitragus. The auricle ends inferiorly with a lobule, which has no cartilage and is actually connective tissue covered with skin. The auricle is a funnel-shaped structure that is continuous with the external acoustic meatus.

The external acoustic meatus includes two parts, namely the external one, which is cartilage and membranous tissue, and the internal, the bony structure. In order to inspect the bony structure and the tympanic membrane, the auricle should be pulled up and back: the auditory meatus is thus made straight. The ear of the child can be examined by pulling the auricle back and down (Figs 53, 54).

The external acoustic meatus in an infant under six months of age has the form of a slit, because the superior wall almost contacts the inferior one. The narrowest part of the external acoustic meatus is located in the middle of the bony part and is called the isthmus.

The external acoustic meatus is covered with skin which is continuous with the skin of the auricle. In the membranous-cartilaginous part of the acoustic meatus the skin is 1-2 mm thick and is covered with hairs, sebaceous and ceruminous glands. The ceruminous glands are modified sebaceous glands; they secrete a brown

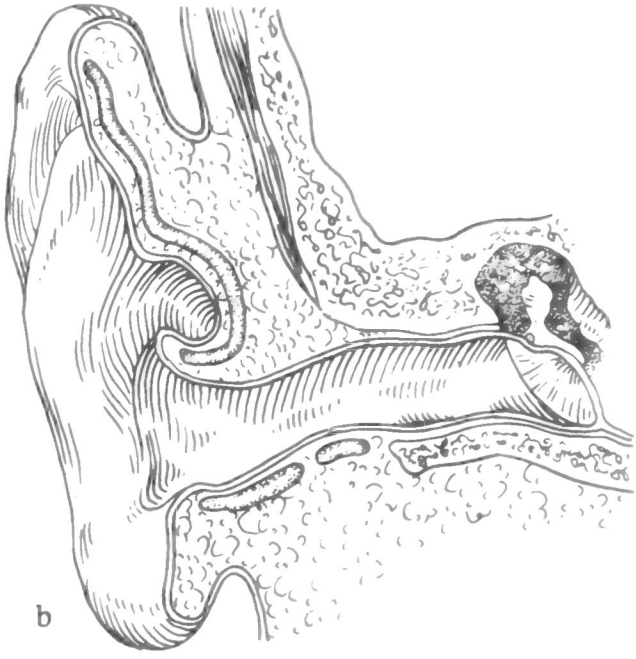

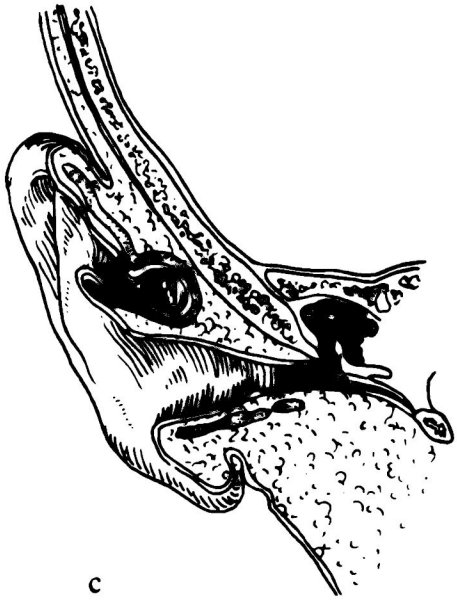

Figure 53
External ear:

a – pinna;
b – external ear of an adult;
c – external ear of a baby

substance, cerumen, which mixes with the secretion of the sebaceous glands and desquamated epithelium to form earwax.

The blood is supplied to the external ear through a system of the external carotid artery. The venous blood outflows in two directions: anteriorly into the posterior facial vein, and posteriorly to the posterior auricular vein.

Lymph outflow is directed toward the nodes found anteriorly to the tragus, on the mastoid process, and under the inferior wall of the external acoustic meatus, from where the lymph is drained to the deep cervical nodes.

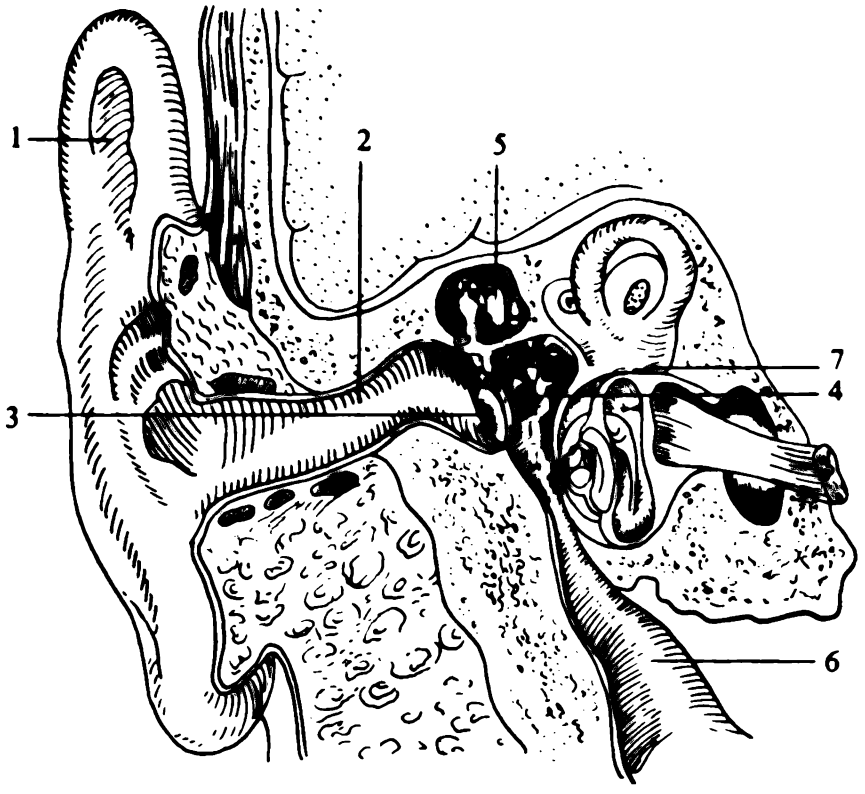

Figure 54
The organ of hearing

1–pinna;
2–external acoustic meatus;
3–tympanic membrane (ear-drum);
4–tympanic cavity (middle ear);
5–auditory ossicles;
6–auditory tube;
7–internal ear

The external ear is innervated by the third branch of the trigeminal nerve, the branch of the cervical plexus, and also by the vagus nerve branch.

The tympanic membrane is the external wall of the tympanic cavity and separates the external ear from the middle ear. It is an anatomical formation of an irregular shape (10 mm high, 9 mm wide and 0.1 mm thick); it is highly resilient but its elasticity is low. The membrane includes three layers: the external (the skin without glands or papillae) which is continuous with the skin of the external acoustic meatus, the internal layer (mucous) which is continuous with the mucosa of the tympanic cavity, and the middle layer (connective tissue) consisting of radial (external) and circular (internal) fibrous bundles.

The tympanic membrane is pearl-grey when viewed in artificial light. It should be remembered that the appearance of the membrane strongly depends on illumination.

For the sake of convenience, the tympanic membrane is divided conventionally into four quadrants by two lines, one of which runs from the manubrium (handle) of the malleus (hammer) to the inferior edge of the membrane, while the other line is perpendicular to the first one and passes through the umbo of the tympanic membrane. Anterosuperior, posterosuperior, inferoanterior and inferoposterior quadrants are thus distinguished.

The middle ear (auris media) includes several intercommunicated air-filled cavities: the tympanic cavity, the auditory (Eustachian) tube, the aditus to tympanic antrum, the antrum proper, and the cells of the mastoid process that are connected with it. The auditory tube connects the middle ear with the nasopharynx. Normally this is the only communication between the cavities of the middle ear and the external environment.

The *tympanic cavity* is a cuboidal chamber with a capacity of about 1 cm^3. Six walls are distinguished in it: the upper, lower, anterior, posterior, internal and external.

The tympanic cavity is divided conventionally into three parts: the epitympanum, the mesotympanum (which is the largest part of the tympanic cavity, located medially to the tense portion, pars tensa, of the tympanic membrane), and the hypotympanum, which is located below the lower edge of the tympanic groove.

The mucosa of the tympanic cavity is continuous with the nasopharyngeal mucosa.

The *auditory ossicles* include the malleus, the incus, and the stapes. These small bones are joined in a system which extends from the tympanic membrane to the oval window (fenestra ovalis).

The muscular apparatus of the middle ear includes two muscles: the tensor tympany muscle and the stapedius muscle. Both muscles are involved in tensioning the auditory ossicles which is necessary for sound transmission and for protection of the internal ear from excessively strong sound stimuli (via reflex contraction).

The *auditory (Eustachian) tube* communicates the middle ear with the nasopharynx. It includes two parts, the shorter bony part (one-third of the tube length) and the longer cartilaginous part (two-thirds of the tube length). The overall length of the auditory tube of an adult is 3.5 cm and of a neonate 2 cm; the bony part of the auditory tube in a neonate is 2 mm shorter than the cartilaginous part. The nasopharyngeal orifice of the tube opens on the lateral wall of the nasopharynx at the level of the inferior nasal concha.

During the first years of life, the auditory tube is shorter and

wider, and its course is more horizontal. This should be remembered when feeding a baby: food, saliva, or mucus can penetrate into the tympanic cavity if the child is fed in the horizontal position; an inflammatory process in the middle ear can thus be provoked. The mucosa of the auditory tube is lined with columnar ciliated epithelium. The cilia beat in the direction of the pharynx. When at rest, the cartilaginous part of the auditory tube is practically closed, because the walls tightly contact one another. During swallowing, the muscles contract and elevate the soft palate; the auditory tube opens and air passes into the tympanic cavity (ventilation of the middle ear). Normally, air is partly absorbed in the tympanic mucosa and partly exchanged with the environment through the auditory tube.

If the auditory tube is obstructed, pathology develops in the middle ear to impair the hearing function.

The tympanic cavity is supplied with blood from the tympanic and the stylomastoid arteries. The venous blood is withdrawn through the veins of the same name. The lymph is drained from the tympanic cavity along the extension of mucosa of the auditory tube to the retropharyngeal lymph nodes.

Sensory nerves of the middle ear are derived from the tympanic plexus comprising the branches of the trigeminal and the glossopharyngeal nerves. This plexus includes also the vegetative fibres of the carotid plexus and the greater superficial petrosal nerve.

The mastoid part of the middle ear of the newborn is a small promontory posterior to the posterosuperior edge of the tympanic ring having only one cavity, the antrum.

The mastoid process of an adult is a cone-shaped projection directed downward. The following structural types of the mastoid process are distinguished according to the degree of pneumatization: (1) pneumatized (containing great amount of air-filled cells); (2) diploetic (spongy); and (3) sclerosed (solid).

The mucosa, lining the antrum and the air-filled cells, is an analogue to and the extension of the mucosa of the tympanic cavity.

The internal ear (auris interna) includes the bony (osseous) labyrinth and the membranous labyrinth inside it.

The *osseous labyrinth* is lodged in the pyramid of the temporal bone. Laterally it borders on the tympanic cavity (the cochlear and oval windows are directed toward the tympanic cavity); medially it borders the posterior cranial fossa with which it communicates through the internal acoustic meatus, the aqueduct of the cochlea and the aqueduct of the vestibule. The labyrinth is divided into three

parts: the vestibule in the centre, a system of semicircular canals (posteriorly to it), and the cochlea (anteriorly to the vestibule). The external wall of the vestibule has the oval window which is closed on the side of the tympanic cavity with the base of the stapes. The anterior part of the vestibule communicates with the cochlea through the scala vestibuli, while its posterior part communicates with the semicircular canals.

Semicircular canals. There are lateral, anterior and posterior semicircular canals, each having an ampoule. The anterior and posterior canals form one common stem.

The cochlea is a spiral bony tube (two-and-a-half turns around the modiolus). A spiral bony lamina extends from the modiolus into the tube. Together with the basilar membrane, the lamina divides the cochlear tube into the scala vestibuli and the scala tympani which communicate through the helicotrema at the tip of the cochlea. The scala vestibuli communicates with the vestibule, while the scala tympani borders on the tympanic cavity at the round window (fenestra cochleae). The first turn of the cochlea is its base; it projects into the tympanic cavity forming a prominence known as the promontorium.

The bony labyrinth is filled with perilymph, while the membranous labyrinth inside it contains endolymph.

The *membranous labyrinth* is a system of canals and cavities, whose course coincides with the curvature of the bony labyrinth.

Two apparatuses are distinguished in the membranous labyrinth from the point of view of anatomy and physiology: (1) the auditory (inside the membranous cochlea), and (2) the vestibular (communicates the vestibular saccules and the three semicircular canals).

The *membranous cochlea* is a spiral canal, the cochlear duct, with the sensory receptors (the spiral organ, or the organ of Corti) inside it.

Resting on the spiral organ is the tectorial membrane (membrana tectoria ductus cochlearis), which is a gelatinous mass.

The *semicircular (membranous) ducts* are lodged inside the semicircular canals. They are smaller in diameter and follow their curvature. They also have ampoules and are attached to the periosteum of the bony walls by the connective-tissue bands in which the vessels pass. The inner surface of the ducts is lined with endothelium (except in the ampoules, where the receptor cells are found). Supporting and sensory cells are located on the inner surfaces of the ampoules (on the ampullary crest); these cells are the peripheral receptors of the vestibular nerve.

There are two membranous sacs within the vestibule of the labyrinth: the saccule and the utricle with the otolytic apparatus embedded in their walls. The epithelium contains supporting and sensory cells. The hairs of the sensory cells form an entangled network which is immersed in a jelly-like membrane containing numerous crystalline bodies, the otoliths (or statoconia, calcium phosphate and calcium carbonate particles).

The hair-like processes of sensory cells and the otoliths form the membrane of otoliths (membrana statoconiorum).

Blood is supplied through the internal and external carotid arteries. The venous blood flows by three routes: the veins of the aqueduct of the cochlea, of the aqueduct of the vestibule, and the veins of the internal acoustic meatus.

The internal ear is innervated by the eighth pair of the cranial nerves (vestibulocochlear nerve), which originate from the medulla oblongata, at the cerebellopontine angle, and enter the internal acoustic meatus.

The vestibular zone is connected with (1) the spinal cord, (2) cerebellum, (3) nuclei of the oculomotor nerves, (4) nuclei of the vegetative centres, and (5) the cerebral cortex.

CLINICAL PHYSIOLOGY

Physiology of the auditory apparatus (the organ of hearing). The auditory apparatus is a system originating at the external ear and ending in the cerebral cortex. Each part of this system has its own function and its impairment causes partial or complete loss of hearing.

A natural stimulant of the auditory apparatus is sound. Perception of sounds begins in the spiral organ of the internal ear from which the stimuli are transmitted to the temporal lobe of the cerebral cortex. These processes are preceded by transmission of the sound wave through the structures of the external and the middle ear and the fluid systems of the labyrinth.

The organ of hearing helps man perceive the changes in the environment and to respond appropriately to them. Moreover, the power of hearing is the requisite factor for the development of speech and oral communication.

From the point of view of physiology, sound is understood as mechanical vibrations of gaseous, solid or liquid medium, which act on the auditory apparatus (sound receptor) thus causing a corre-

sponding physiological process, which is perceived subjectively as sound. The velocity at which sound vibrations propagate in air is 332 m/s, and in water 1450 m/s. It is quite obvious that sound is absent in vacuum.

The physical characteristics of sound are the frequency and amplitude of vibrations. The unit of frequency is hertz (the number of cycles of vibrations per second).

According to the character of vibrations, sounds are classified as pure, mixed sounds, and noise. Harmonic sinusoid (rhythmic) vibrations produce pure and simple sounds as that produced by a tuning fork. Non-harmonic sounds differ from simple tonal sounds by their complex structure and are known as noise. Perception of noise is often associated with the unpleasant subjective sensation.

Among the main properties of the organ of hearing is its ability to distinguish the pitch (frequency), intensity and timbre of sound. Frequencies that can be perceived by the human ear range from 16 (12-24) to 20 000 (18 000-24 000) hertz. Frequencies beyond the range of human hearing (below 16 and above 20 000 hertz) are called infra- and ultrasound, respectively; they can however be perceived by man under special experimental conditions.

The minimum intensity of vibrations that can produce a sensation of sound is called the absolute threshold of audibility and is measured in decibels.

The adjustment of the organ of hearing to a sound stimulus is called adaptation, which tunes the ear to perception of sound of a given intensity and frequency. Adaptation is also important as a means of protection against very loud and long sounds. Adaptation should be differentiated from fatigue of the auditory apparatus due to its overload. As distinct from adaptation, fatigue develops during longer periods of time and always decreases the working capacity of the organ of hearing.

An important property of the auditory apparatus is the ability to discriminate the sound direction (ototopia). The auditory spacial orientation is only possible with the adequate hearing function of both ears (binaural hearing).

The peripheral part of the auditory apparatus performs two main functions: (1) sound conduction, i.e. transmission of the sound energy to the receptor; this is mostly the mechanical (physical) function; (2) perception of sound, i.e. conversion (transformation) of physical energy of sound vibrations into nerve impulses (electric potential) of the peripheral receptor (the spiral organ), which are then transmitted to the cerebral cortex.

Sound conduction and sound perception apparatuses are distinguished accordingly.

Physiology of the vestibular apparatus. The organ of equilibrium (the vestibular apparatus) controls the tone of muscles, maintains the body in a given position and relays information concerning the position and movement of the body in space to the cerebral cortex. As the receptors of the vestibular apparatus are stimulated by impulses, the muscles react by reflex to preserve the body balance.

The functions of the semicircular canals and of the vestibular saccules are differentiated. The reflex can be stimulated by the otolithic apparatus; the force of gravity and rectilinear acceleration are natural stimuli in such cases. The reflex can also be initiated by the ampullar apparatus when the angular acceleration is perceived.

When the semicircular canals are stimulated, the striated muscles contract by reflex. This concerns the muscles of the eyes, the limbs, the trunk, and the neck. The eye reflexes are manifested as nystagmus (rhythmic movement of the eyeballs, which can be slow and rapid).

The most valuable information on the functional condition of the labyrinth is obtained by analyzing nystagmus following experimental stimulation of the receptors of the semicircular canals.

The methods of examination of the vestibular function include the rotation test, the caloric test, and the pneumatic (fistula) test.

METHODS OF EXAMINATION

Examination of the ear includes collecting anamnestic data, inspection, palpation, otoscopy, and functional tests.

When listening to the patient's complaints, it is necessary to pay special attention to diseases of the nose and throat that might possibly precede a given disease of the ear. Influenza or other infectious disease are also important for the aetiology of the diseases of the ear.

Inspection and palpation of the ear. (1) The intact ear should first be examined. The inspection begins with the pinna (auricle), external acoustic meatus, retroauricular region, and the region anterior to the acoustic meatus.

(2) To inspect the external acoustic meatus of the right ear, the auricle should be pulled up and back by taking hold of the helix of the auricle with the thumb and the forefinger of the left hand.

The orifice of the left acoustic meatus is inspected in a similar manner, using the right hand.

(3) To inspect the retroauricular region, the right auricle should be pulled anteriorly. The skin fold at the place of attachment of the auricle to the mastoid process is inspected. The mastoid process is then palpated by the thumb of the left hand at three points: the projections of the mastoid antrum, sigmoid sinus, and the apex of the mastoid.

When palpating the left mastoid process, the auricle is pulled by the left hand, and the thumb of the right hand is used for palpation.

4. The regional lymph nodes of the right ear are palpated by the forefinger of the left hand, anteriorly and posteriorly to the external acoustic meatus. The forefinger of the right hand should be used to palpate the lymph nodes of the left ear. Normally the lymph nodes are impalpable.

5. The tragus is pressed by the right thumb. Palpation is normally painless. Tenderness of the tragus in adults is associated with otitis externa, and in children with otitis media.

Otoscopy. 1. The right auricle is pulled by the left hand: posteriorly and superiorly in adults and posteriorly and inferiorly in children. The aural speculum should be introduced into the membranous part of the external acoustic meatus, using the thumb and the forefinger of the right hand. When inspecting the left ear, the auricle should be pulled by the right hand and the speculum inserted by the fingers of the left hand (Figs 55, 56).

2. The diameter of the aural speculum should correspond to the diameter of the external acoustic meatus.

3. Passing the speculum to the bony part of the acoustic meatus causes pain. The longer axis of the speculum should align with the axis of the bony part of the acoustic meatus.

4. All portions of the tympanum should be inspected by changing the position of the proximal end of the speculum.

5. Among side effects of otoscopy (especially if the speculum touches the posteroinferior wall) may be cough due to irritation of the vagus nerves endings.

Otoscopic picture. The external acoustic meatus is 2.5 cm long. It is covered with skin which has hairs in its membranous-cartilaginous part. Secretion of the ceruminous glands (earwax) can be present in the meatus. The tympanic membrane is grey with a pearly hue. There are several landmarks on the tympanic membrane: the short process and the manubrium of the malleus, the anterior

Figure 55
Otoscopy

and posterior folds, the cone of light (light reflex), and the umbo of the tympanic membrane. The membrane comprises two parts: the greater portion known as the pars tensa, and the triangular portion, the pars flaccida. Four quadrants are also distinguished on the eardrum.

Determining the patency of the auditory tubes. *Valsalva's maneuver.* The patient is asked to take a deep breath and then to exhale forcibly against occluded nostrils and a closed mouth. As the pressure increases, the auditory tubes open and the air enters the tympanic cavity to move the membrane outward. The patient feels crisping sounds in the ears.

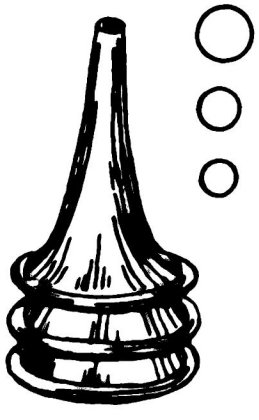

Figure 56
Aural specula

Figure 57
Using the Politzer bag

Valsalva's maneuver fails if the mucous membrane of the auditory tube is affected.

Politzer's treatment. The olive of the Politzer bag is introduced into the right nostril of the patient and held in place with the thumb of the left hand while the forefinger closes the left patient's nostril as shown in Fig. 57. An olive of an otoscope is passed into the external acoustic meatus of the patient and the other olive into the ear of the physician. The patient is asked to utter "one, two, three" or any other word rich in vowels. As the patient pronounces a vowel, air is forced into the patient's nose by compressing the Politzer bag. When the patient utters a vowel, the soft palate is raised and the nasopharynx is thus separated from the other airways, the air pressure increasing inside it. Part of the air passes forcibly into the auditory tubes which is detected by the examiner due to a specific sound in the otoscope. The procedure is then repeated in a similar way with the other nostril.

Catheter perflation of the auditory tubes. 1. The nasal mucosa is anaesthetized with a 5 per cent cocaine solution. The olives of the otoscope are put into the ears of the patient and the examiner (Fig. 58).

2. The catheter is held in the right hand like a pen. In anterior rhinoscopy, the catheter is passed (with its beak down) by the inferior nasal passage down to the nasopharynx.

3. The catheter is then pulled 2-3 mm back, the beak is turned 90° medially, and pulled back again till the examiner feels the catheter beak touch the vomer.

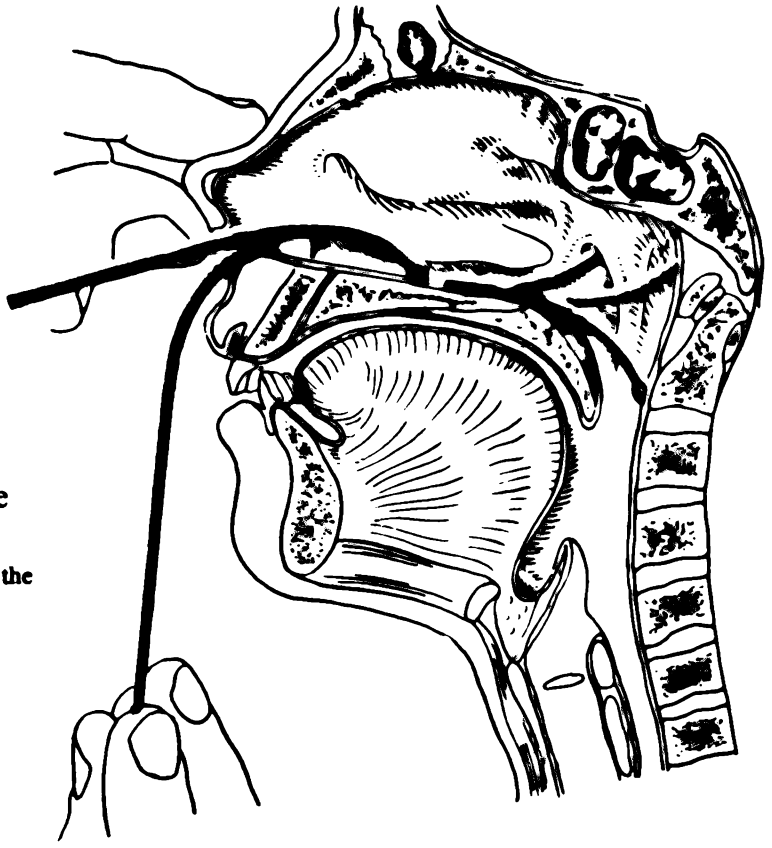

a

Figure 58
Catheterization of the auditory tube:

a – passing the catheter into the auditory tube;
b – blowing technique

b

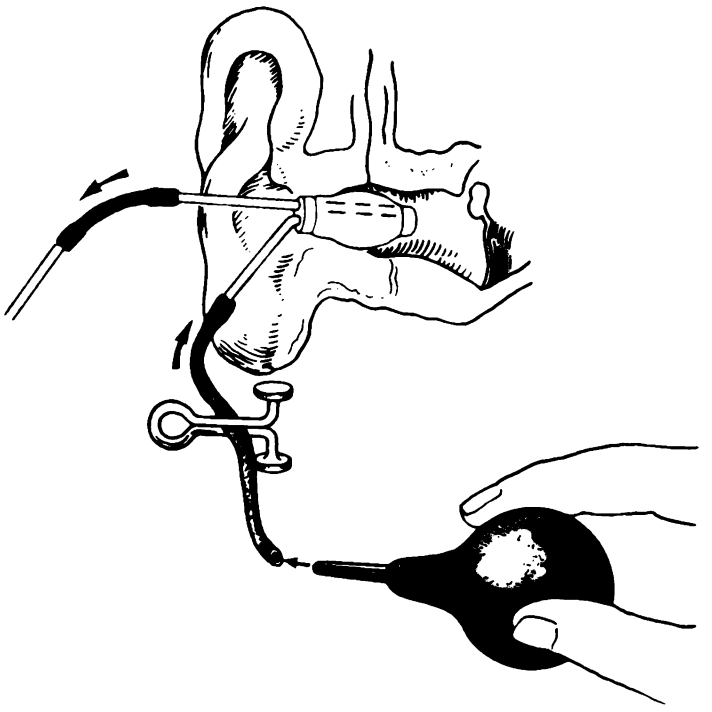

Figure 59
Otomanometry

4. The beak is now turned down and further through 180° toward the examined ear so that the ring of the catheter is directed approximately to the external canthus of the eye on the side of examination. The beak enters the pharyngeal opening of the auditory tube. The examiner usually feels this moment with his fingers.

5. A rubber bulb is now pressed slightly with a short movement of the fingers to pass air into the auditory tube (Fig. 59). The examiner hears noise through his otoscope.

Functional tests. *Hearing test (whispered and spoken voice tests).*

1. The patient is at a distance of 6 metres from the examiner, with the examined ear toward the physician, while the assistant closes the other ear by pressing the tragus tightly with the forefinger. In order to produce a slight masking noise, the assistant should rub the forefinger against the thumb.

2. The patient is asked to repeat loudly the words uttered by the physician. In order to prevent visual hearing (lipreading), the patient should not look at the physician.

3. The physician exhales normally, and then whispers words with low vowels, e. g. "hawl, raw", etc., and then with high vowels, such as "feet, cheese", etc.

4. If the patient cannot hear at a distance of 6 metres, the physician should approach the patient to a distance of 5 metres, and examine the patient again. The distance should thus be shortened by 1 metre each time until the patient repeats correctly all the words pronounced by the physician.

5. The results of the test are expressed in metres at which the examinee hears the whispered words.

6. The patient can be tested for hearing spoken voice using the same technique as in the whispered voice testing.

Tuning-fork tests. *Test for air conduction.* A set of tuning forks (C_{128}, C_{512}, C_{2048}) is used for the purpose. The test begins with the lower frequency (C_{128}). The tuning fork is tapped on the palm. The C_{512} and higher pitch tuning forks are stroked between the thumb and the forefinger, or by giving a flick with the finger nail.

A vibrating tuning fork should be held by its stem with two fingers and brought to the external acoustic meatus of the examinee to a distance of 0.5 cm. The time during which the examinee hears the tuning fork is measured by a stopwatch. After the patient does not perceive the sound of the fork, it should be moved away from the patient's ear and then brought close to it again (without reactivation). As a rule, the patient can now hear the tuning fork again for a short time. The stopwatch is read finally by the last answer of the patient.

Test for bone conduction. This is performed with a C_{128} tuning fork, because higher frequencies can be perceived by the ear through air conduction, while lower frequencies are perceived by the skin.

The vibrating tuning fork is placed perpendicularly to the mastoid. The time during which the patient perceives the vibrations is measured by a stopwatch (from the moment the fork is stroked on the palm).

Rinne's test (comparison of air and bone conduction).

A vibrating tuning fork (C_{128}) is placed with its stem on the mastoid. After the patient reports discontinuation of sound perception, the fork (without reactivation) is put to the external acoustic meatus. If the patient hears the fork sound through air, the Rinne test is considered positive (+). If the patient does not hear the fork through the external acoustic meatus, the result is negative (−).

Weber's test. A vibrating fork (C_{128}) is placed on the vertex of the patient's head so that the stem of the fork is in the midline of the head. The prongs should vibrate in the frontal plane, i. e. from one patient's ear to the other.

Normally the patient hears the tuning fork in the middle of the head, i.e. by both ears (→ N ←). If the sound is heard better by the affected ear, the conduction system is probably damaged. If the sound is better heard by the normal ear, this is probably due to disease of the auditory apparatus.

Schwabach's test (determining hearing length with bone conduction).

A vibrating tuning fork is placed on the vertex of the patient's head and held there until the patient hears it no longer. The examiner, whose hearing power is normal, puts the vibrating fork (without reactivation) on his own head. If he can hear the ringing fork, the result is expressed as "Schwabach shortened or diminished".

Gelle's test. A vibrating tuning fork is placed on the head vertex; the pressure in the external acoustic meatus is increased using a rubber bulb. If hearing is normal, the sound perception decreases with increasing pressure, which is due to impaired articulation in the ossicular chain (the stapes is impressed into the fenestra ovalis). If the stapes is fixed, as in otosclerosis, the increasing pressure in the external acoustic meatus will not reduce the sound perception. If the auditory apparatus is affected, increased air pressure inside the external acoustic meatus will cause the same reduction of the sound perception as in normal persons.

Bing's test. This test is used to determine relative and absolute bone conduction. A C_{128} tuning fork is used for the purpose. A vibrating tuning fork is applied to the mastoid process and the external acoustic meatus is then alternately closed (by pressing the tragus against the auricle) and left open. If the auditory apparatus is normal and if the ossicular chain is flexible, exclusion of the air conduction (by closing the acoustic meatus) prolongs bone conduction. In the presence of otosclerosis bone conduction remains the same with the external acoustic meatus open and closed.

Federici's test. C_{128} and C_{512} tuning forks are used. A vibrating fork is applied to the mastoid process. As the patient hears it no longer, the fork is placed on the tragus. Persons with normal hearing function perceive the vibrations of the fork longer if it is held to the tragus rather than to the mastoid process. The picture is reverse in the presence of otosclerosis.

Testing the hearing function with electro-acoustic apparatus (audiometry). The main object of these tests is to assess hearing acuity and to determine the character and degree of hearing loss in various diseases (Fig. 60).

Testing the hearing function with electro-acoustic apparatus has many advantages over the other methods. The sound intensity can be varied within wide range. The hearing function can thus be tested in patients with severe hearing loss. Both ears of the patient can be tested simultaneously. Various diagnostic tests can be carried out using above-threshold audiometry. Electric instruments can pro-

Figure 60
Audiometry

duce sounds whose intensity remains unchanged for the required lengths of time.

Depending on the stimulus used to study the hearing function, all audiometric methods are divided into tonal, speech and noise tests. Ultra- and infra-sound can also be used for hearing tests.

Pure tone audiometry uses frequencies from 128 to 8192 Hz. Speech audiometry uses special tape-recorders or record players by which the speech perception and discrimination thresholds are determined. Noise audiometry uses the so-called 'white noise', which is produced by a special generator, in combination with pure tones.

Depending on the strength of the stimulus, all audiometric methods are divided into two groups: threshold and above-threshold tests. Threshold audiometry deals with threshold intensities, i.e. with hardly audible sounds, while above-threshold sounds are quite loud.

From the point of view of psychophysiology, the existing methods can be objective and subjective. Subjective audiometry is based on subjective sensations of the patient and on his voluntary response. Objective (reflex) audiometry depends on the conditioned and unconditioned reflex response of the patient to the sound stimuli.

The variety of methods is explained by the numerous problems

of audiology and requirements of clinical otology, in particular functional otosurgery, for which it is very important to know the character and the degree of affection of the auditory apparatus.

Methods of examination of the vestibular apparatus. The patient is asked about his complaints: the feeling as if the surrounding objects or the patient himself move about (systemic vertigo), uncertain gait, falling to one or other side; it is important to know if the patient has fits of nausea and vomiting, if vertigo intensifies as the patient changes the position of his head. The anamnesis of the disease should be collected.

Romberg's test. The patient stands upright with his feet close together and the arms stretched at the level of the chest and the fingers set apart. The patient's eyes are closed. (The assistant physician must see to it that the patient does not fall.) In labyrinthine dysfunction, the patient falls on the side opposite to the nystagmus. The patient's head is turned 90° to the left: if the labyrinth is affected, the patient falls to the other side. The situation is the same if the patient turns the head to the right.

Example. The patient develops nystagmus to the right. His head is turned 90° to the left. The direction of nystagmus remains the same but the orientation relative to the trunk changes: the slow component is directed backward, and the patient falls to the side of the slow component, i.e. backward in this particular case.

If the cerebellum is affected, the change in the position of the head does not change the direction of the fall. The patient falls only in the direction of the affected side.

Straight and sideways walking. 1. Straight walking. The patient closes his eyes and makes five steps forward, then five paces back without turning. If the vestibular apparatus is affected, the patient deviates from rectilinear movement to the side opposite to nystagmus. If the cerebellum is involved, the deviation is in the direction of the affected side.

2. Sideways walking. The patient moves his right leg one step aside, and then brings the left leg to the right one. Thus he makes five steps to the right and then back to the left.

If the vestibular apparatus is affected, the patient performs this test adequately in either direction. In case of cerebellar affection, the patient cannot perform this test and falls.

Pointing test. The physician sits facing the patient and stretches his arms toward him at the level of his chest. The forefingers are straightened, while the other fingers are closed in fists. The patient's arms rest on his laps, with the fingers in the same position.

The patient must raise his arms and touch the forefingers of the physician.

First the patient performs this manipulation three times with his eyes open, and then with closed eyes. If the labyrinth is normal, the patient is successful in accomplishing this test. If the labyrinth is affected, the patient misses the physician's fingers, the movement of his both arms deviating in the direction opposite to nystagmus. If the cerebellum is affected, the patient cannot touch the physician's finger with one arm on the involved side (deviation in the direction of the involved side).

Adiadochokinesia (specific symptom of cerebellar affection). The patient assumes the Romberg station and performs supination and pronation with both hands. If the cerebellar function is disturbed, the movement of the hand on the involved side is markedly delayed.

Spontaneous nystagmus. The physician sits facing the patient, and sets his index finger vertically at the level of the patient's eyes, at a distance of 60-70 cm and to the right, and asks the patient to look at his finger. It is necessary that the patient had not moved his eyes to the right to a great extent, since the ocular muscles will be overstrained and the eyeballs will jerk. The presence or absence of nystagmus is determined in this position. If there is spontaneous nystagmus, its characteristics are determined (with respect to plane, direction, degree, amplitude, and speed). The test is repeated with the finger set in front of the patient and to the left of him. For example, spontaneous horizontal nystagmus to the right, second degree, small amplitude, fast. It is necessary to remember that congenital spontaneous nystagmus occurs in rare cases. It is characterized by uniformity of oscillations, the absence of the slow and fast components, and independence of the direction of the sight.

Caloric test. The physician must inquire the patient if he had diseases of the middle ear and then carry out otoscopy. If the tympanic membrane is not perforated, a caloric test can be carried out. The patient sits with his head tilted back at an angle of 60°. A Janet's syringe is used for the test. The temperature of water is 19 °C.

1. Right ear. The right external acoustic meatus is douched with 100 ml of water at 19°C within ten seconds, directing the jet from the syringe on the posterosuperior wall of the meatus. The time from the end of douching to the onset of nystagmus is determined (the latent period). Normally this is 25-30 seconds.

The patient fixes his eyes at the index finger of the physician which is first set at a distance of 60-70 cm and to the left of the patient's eyes; then the eyes are set straight and to the right.

The nystagmus with respect to the plane, direction, degree, amplitude, and speed is first determined for each eye position; then the sight of the patient is transferred in the direction of the fast component and the duration of nystagmus is determined. The duration of nystagmus is determined after assessing its degree, when the eyes are directed to the side of the fast component; normal length of experimental nystagmus after the described calorization is 30–70 seconds.

2. Left ear. The caloric test for nystagmus in the left ear is carried out in the same way, except that the sight to the right (i.e. in the direction of the expected nystagmus fast component) is first analysed.

3. Caloric test with hot (45 °C) water is carried out in the same way as with cold water. In irrigation with cold water, the nystagmus (its fast component) is directed to the side opposite to the tested ear. When hot water is used, nystagmus develops toward the side of the irrigated ear.

Rotation test. The patient sits in a revolving (Bárány's) chair with his back tightly pressed against the back of the chair, feet placed on the foot support, and arms on the elbow-rests. His head should be tilted 30° forward and downward and his eyes should be closed. The chair should then be turned at a uniform speed, 10 turns clockwise over 20 seconds, and then stopped abruptly.

After the chair is stopped, the endolymph will continue moving in the lateral semicircular canals. The slow component of nystagmus will be directed to the right as well, while the direction of nystagmus (fast component) will occur to the right. The patient must raise his head immediately after rotation is discontinued and fix his eyes on physician's finger which should be held at a distance of 60-70 cm to the left of the patient's eyes. The physician determines the direction of nystagmus (right, left, upward, downward), its plane (horizontal, rotary, vertical), degree (I-II-III), amplitude (low, moderate, and high), speed (brisk, slow) and duration (normal, 20-30 seconds). To determine the degree of nystagmus, the physician's index finger, at which the patient fixes his eyes, should be held at the side of the expected nystagmus component. As nystagmus develops, the patient's sight changes from lateral to straight; disappearance of nystagmus indicates degree I. If nystagmus persists with a straight look, the nystagmus is degree II, but only

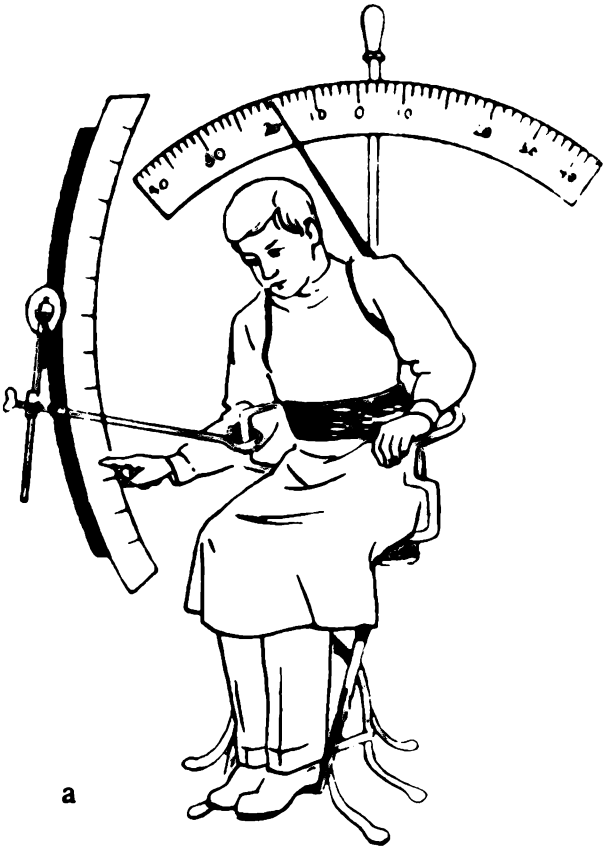

a

Figure 61

Examining the function of the otolithic apparatus

a – on Bárány's chair;
b – swinging test

b

on the condition that nystagmus disappears as the sight is moved toward the slow component side. In the latter case, if nystagmus persists when the patient moves his eyes in the direction of the slow component, the nystagmus is degree III.

Pneumatic test. The physician sits facing the patient, who fixes his sight at the left ear of the physician. The entrance to the external acoustic meatus should be smeared slightly with peach kernel or vegetable oil. The physician creates excessive pressure inside the meatus by pressing the tragus with the left index finger (or using a rubber bulb). If the labyrinth is intact, no nystagmus appears. If there is a fistula in the lateral semicircular canal, nystagmus occurs in the direction of the affected side (to the right). On decompression a nystagmus to the opposite side (to the left) develops.

The left ear is tested in a similar way. The body inclines in the direction opposite to nystagmus.

Testing the function of the otolithic apparatus. The patient sits in a revolving chair (Bárány's chair), closes his eyes, and tilts his head and trunk 90° forward. The physician turns the chair (5 turns within the course of 10 seconds) and then stops the rotation suddenly. Possible motor reactions are recorded. In 5 seconds the patient is allowed to open his eyes and to straighten.

The deviation of the head and trunk from the median line in the direction of rotation and the vegetative reactions are evaluated; the function of the otolithic apparatus is thus assessed (Fig. 61).

The somatic reactions to the otolithic test (inclination of the head and the trunk) are as follows: degree I, weak, deviation through 0 to 5°; degree II, moderate, deviation through 5 to 30°; and degree III, strong, the patient's sense of balance is lost and he falls.

The vegetative reactions are also classified as degree I (weak), characterized by pallor and fall of pulse; degree II (moderate), attended with cold sweat and nausea; and degree III (strong), characterized by vomiting, a neurogenic shock and syncope.

GENERAL THERAPY AND NURSING

The general methods of treating diseases of the ear are the same as those for treating diseases of the nose, the pharynx, and the larynx. They include all means of anti-inflammatory and

desensitizing therapy. Local treatment includes cleaning of the external ear, instillation of medicines into the ear, and external application of ointments with and without turunda. The nurse must be able to use a head mirror and to perform various manipulations in the external ear.

The external acoustic meatus is *cleaned* using cotton wool which is wound round a serrated probe so that the probe end looks like a brush. Cotton should be oiled with liquid petrolatum, introduced into the external acoustic meatus with the aid of otoscope and then earwax is removed.

Irrigation of the ear is done with a Janet's syringe. The temperature of water should be the same as that of the patient's body (to prevent irritation of the vestibular apparatus). A bean-shaped basin should be held under the patient's ear. The tip of the syringe is introduced into the proximal end of the acoustic meatus after pulling the auricle up and back. The jet from the syringe is directed on the posterosuperior wall of the meatus.

Excess water should then be removed from the ear. To that end, cotton wool wound round a probe should be used.

If dry perforation is suspected, irrigation is contraindicated for the danger of otitis media.

Foreign bodies should be removed from the ear by irrigation and using a hook. As a rule, forceps are not used because the danger exists that a foreign body can be pushed further into the ear.

A hook is introduced into the acoustic meatus under otoscopic control and an attempt is made to pass it between the foreign body and the wall of the meatus. This done, the hook should then be turned so as to catch the foreign body and pull it out.

Foreign bodies can also be removed by irrigation. The procedure has been described above.

Special care should be given to patients operated on in order to preserve the hearing function or improve it (tympanoplasty, stapedoplasty).

The operated patient must remain in bed till the first dressing; he must not turn his head during the first five postoperative days. To that end, the patient's head should be fixed to the bed before the night sleep (using broad bandage). During the first days after the operation by which the hearing function was restored, complete silence must be ensured to prevent irritation of the operated ear.

DISEASES OF THE EXTERNAL EAR

INJURIES AND FOREIGN BODIES

Injuries can be superficial when soft tissues of the ear are only affected without involvement of the bones (for example, deep parts of the skin of the external acoustic meatus or the tympanic membrane). The injury may also be deep, with fractures and infractions in the temporal bone. Infractions can be diagnosed by X-ray examination or by some clinical symptoms.

Mechanical injuries. Surface injuries to the auricle can be due to blows, contusion, bite, etc. The auricle can be partly or completely torn off. The extent of damage and its character depend on the injury and type of infection. Modern treatment of the wound promotes rapid healing and prevents formation of disfiguring scars.

Infection of the wounded auricle during its injury, or due to delayed medical aid, can cause perichondritis (inflammation of the perichondrium) or chondritis with subsequent degeneration of the cartilage and deformation of the auricle.

Surface wounds (without involvement of the perichondrium) are treated with a 5 per cent iodine tincture; powdered penicillin or sulphanilamide can be insufflated. Deep wounds should be treated following the rules of general surgery. It should be noted that sutures should be preferably placed during the first hours or day following the injury; the primary suture can be placed on the second day as well. Antitetanus serum should be administered according to the generally accepted scheme. The wound should be dressed every day. Physiotherapy (UV, UHF, etc.) and antibiotics (penicillin, 300 000 U intramuscularly, 3 times a day during 5-6 days) are helpful.

If the wound purulates at late terms following the primary surgical treatment, the sutures should be removed and additional incisions made to remove pus, if necessary. The wound in this case heals by second intention.

Haematoma of the perichondrium of the ear (haematoma auris) can be caused by prolonged compression or contusion of the ear auricle. Blood is accumulated in the space between the cartilage and the perichondrium. Inspection reveals a round fluctuating swelling, which is usually located on the anterior surface of the upper part of the ear. Its colour is red with a bluish hue. Palpation is usually painless. The swelling is filled with blood and lymph. Sometimes

the haematoma purulates due to the ingress of infection under the perichondrium.

Small haematomas often resolve spontaneously or after placing a compression bandage on it. Large haematomas should be punctured and their contents withdrawn by suction. Compression bandage should be applied for several days. Purulent haematoma should be incised and the wound irrigated with penicillin solution with subsequent placing a compression bandage. If haematoma concurs with fracture of the cartilage, the fragments should be repositioned and a compression bandage applied.

Injury to the external acoustic meatus. The osseocartilaginous or the bony parts of the meatus can be injured. Both parts are affected less frequently. The injuries can be direct and indirect. In the latter case the external acoustic meatus can be injured by blows to the jaw: the anterior and the inferior walls of the acoustic meatus are thus injured.

First aid includes primary treatment of the wound and arrest of haemorrhage, irrigation of the wound with penicillin solution and administration of the antitetanus serum. In order to prevent possible cicatricial constriction or atresia of the meatus, and also in order to eliminate inflammation, turundas soaked in sterile vaseline oil, sulphanilamide or synthomycin emulsions should be used for tamponade of the external acoustic meatus. As inflammation subsides, a tubular dilatator, made of rubber or plastic, should be used if necessary. Antibiotics should obligatory be administered. Physiotherapy (UV, UHF) is also useful.

Patients with fractured anteroinferior wall of the external acoustic meatus should be given liquid food only. To prevent dislocation of the bone fragments, the lower jaw should be immobilized by bandage. Such patients should be treated in hospital.

Direct and indirect **injuries to the tympanic membrane** are distinguished. Direct injury implies puncture of the membrane by extraneous objects such as matches or pins that are inappropriately used for cleaning the ear. An awkward attempt to extract a foreign body from the ear can also injure the tympanic membrane. Indirect injuries occur during fractures of the skull base if the line of fracture passes through the tympanic ring.

The tympanic membrane can be injured by a suddenly increased or lowered air pressure in the external acoustic meatus, for example, if a person falls landing on his ear, or suffers a blow to the ear; diving can also cause rupture of the membrane.

The patient and the physician must be very careful as not to infect

the middle ear. Unnecessary manipulations (removal of blood clots or liquid from the ear) should be avoided. Irrigation of the ear is prohibited.

First aid should be limited to introduction of a dry sterile turunda or a cotton ball into the external acoustic meatus. If there is no discharge from the ear, medicinal preparations should not be administered into the ear on the very first day of the injury.

Injury to the internal ear (labyrinth). The internal ear is injured in rare cases in peace time. It can be caused mainly by penetration of sharp objects (e.g. pins) through the tympanic membrane and the windows of the labyrinth. The internal ear can sometimes be injured directly during surgical interventions. But indirect injuries are more frequent. They concur with fractures of the base of the skull attended with fractures of the pyramid of the temporal bone and injuries to the large blood vessels of the skull.

Fractures of the pyramid of the temporal bone usually concur with fractures of the bones of the skull base. They usually occur when a blow is inflicted on the forehead or the back of the head; sometimes they occur when a person falls landing on his chin. These fractures are characterized by the absence of displacement of bone fragments.

The lines of fractures on the pyramid of the temporal bone are classified as longitudinal and transverse. In the former case the roof of the tympanic cavity and superior wall of the acoustic meatus are broken. In transverse fractures the line traverses the entire pyramid.

The tympanic membrane ruptures mostly in longitudinal fracture of the temporal bone. Blood and sometimes the cerebrospinal fluid flow out through the broken tympanic membrane. The auditory and vestibular functions are disturbed to a smaller extent. Complete impairment of functions of the internal ear and paralysis of the facial nerve occur in transverse fractures of the temporal bone.

Treatment includes therapeutic and other measures. When the patient is transported from the site of accident to a hospital (after primary bandaging), all precautions should be taken as not to jolt the patient, or turn him from one side to the other, or tilt his head. In the hospital bleeding (if any) should be arrested by closing the external meatus with a sterile turunda or a dry cotton ball. If intracranial pressure increases, lumbar puncture is necessary. If bleeding from the ear is profuse, or signs of intracranial complications (e.g. meningitis) develop, a vast surgical inter-

vention is required. Further medical measures depend on the patient's condition, the neurological condition included.

Thermal and chemical injuries are caused by high or low temperature, corrosive acids, alkalies, and the like substances. Thermal affections of the ear almost always concur with burns of the face and neck. Burns and frostbites are classified by their degree. The first-degree burn is characterized by erythema; the second-degree, by oedema and formation of bullae; the third-degree, by superficial necrosis; and the fourth-degree burn is characterized by deep necrosis and charring. The first degree of frostbite is marked by swelling and cyanosis of the skin; the second, by formation of bullae; the third, by necrosis of the skin and subcutaneous connective tissue; and the fourth degree, by necrosis of the cartilage.

Treatment. The first aid in cases with *thermal burns* of the skin of the ear auricle and the external acoustic meatus should be given in accordance with the rules of general surgery. Analgesics (morphine or pantopon) are injected. The affected skin is treated with a 2 per cent potassium permanganate solution or a 5 per cent aqueous solution of tannin. After the bullae are opened, a 10-40 per cent silver nitrate solution is used for cauterization. In cases with necrosis, the necrotized tissue should be removed and antiseptic ointments and corticosteroid preparations (hydrocortisone suspension, etc.) applied. To prevent possible stenosis or atresia of the external acoustic meatus, gauze tampons soaked in a 1 per cent synthomycin emulsion should be inserted. Later a rubber tube should be passed into the external acoustic meatus to assist formation of the lumen.

First aid in frostbites of the ear auricle includes warming it in warm (37° C) water and careful treatment with alcohol. If bullae are formed, astringent solutions or ointments are used to promote drying. The bullae can be opened with strict observation of rules of asepsis. After releasing the bullae contents, antibiotics should be applied and the ear bandaged.

Patients with thermal burns of the 3rd and 4th degree should be treated in hospital.

In cases with chemical burns, neutralizing substances should first of all be used (alkali is used to neutralize acid, etc.). Further treatment is the same as in thermal burns.

Acoustic trauma arises on prolonged exposure to very loud sounds (150-160 dB). Acute and chronic acoustic traumas are distinguished. Acute injury is the result of a short effect of superstrong and high-pitch sounds. Perception of such sounds is associated with pain.

Chronic acoustic injury is based on the so-called fatigue factor (debilitating effect of sounds on the organ of hearing). Hearing disorders caused by short-lasting noise are, as a rule, reversible. But durable and repeated strong sound stimuli can cause atrophy of the spiral organ.

Acoustic injury can be *prevented* by medical and technical measures. It is very important to examine thoroughly persons before their employment in industry and other occupation associated with noise; regular medical examinations of such workers are necessary.

Individual means of protection include special attachments and devices that reduce noise (inserts, tampons, helmets, etc.).

Diagnosis is based on the findings of the general examination of the patient and testing his hearing function. Treble deafness and shortening of bone conduction are usually associated with acoustic injury.

Treatment. At the initial stage of developing occupational hearing loss, the patient should be advised to change his occupation. Persons working in noisy conditions must take measures of individual protection. Work should be alternated with rest. Medication includes envigorating therapy and sedatives (bromides). Pine and hydrogen sulphide baths, vitamins (C; B_1, B_6, B_{12} complex; A and E, which have a positive effect on blood circulation and oxidation processes), and ATP courses act sedatively on the central nervous system.

Vibration injury. This type of trauma is caused by vibration generated by various mechanisms (tools, traffic).

Prevention and treatment are the same as in acoustic injury. Measures should also be taken to dampen or absorb vibration.

Barotrauma is caused by changes in atmospheric pressure. The internal and middle ears are most vulnerable to changes in atmospheric pressure.

Two types of barotrauma are distinguished: it can be caused by the change in air pressure only in the acoustic meatus, or it can arise due to the pressure difference in the environment and the tympanic cavity (e. g. in divers). Combination of barotrauma and acoustic trauma occurs in explosions or gunshots at a close distance. These traumas are based on the instantaneous increase in atmospheric pressure and a sudden effect of a high-frequency sound.

The otoscopic picture of barotrauma is characterized by a hyperaemic tympanic membrane associated with haemorrhage into its tissues; the membrane can have ruptures or be destroyed at all.

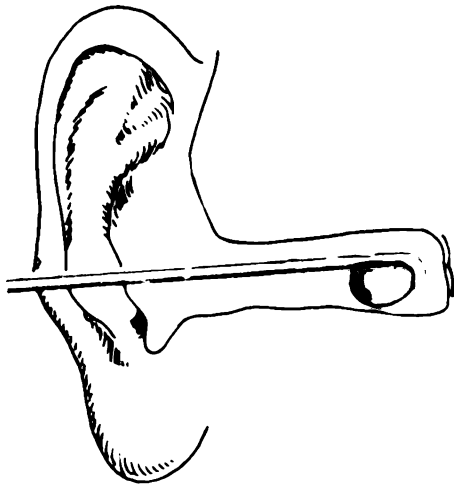

Figure 62
Removing a foreign body from the ear

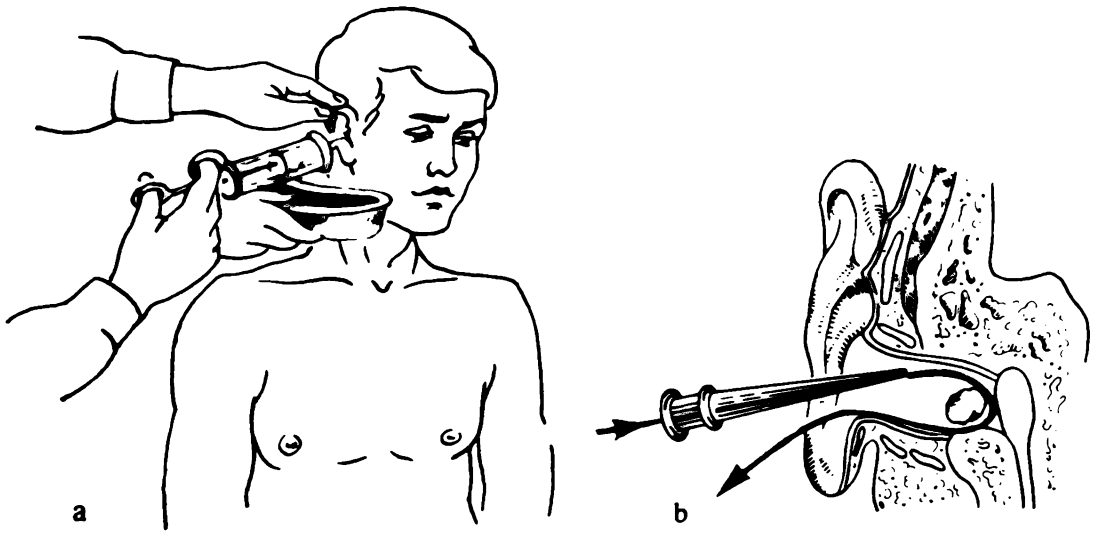

Figure 63
Irrigation of the ear:

a – general view; *b* – correct direction of the liquid jet

The patient has tinnitus, nausea and vertigo, his hearing function is impaired. Consciousness can be lost.

First aid in barotrauma associated with ruptures of the tympanic membrane, haemorrhage from the ear or into the eardrum, includes a thorough and very careful cleansing of the acoustic meatus from blood clots and possible extraneous matter (that may get into the ear in explosion) using sterile cotton wound round an applicator. Irrigation of the ear is strictly prohibited, because the damaged tympanic membrane can thus be infected. Dry sterile turundas should be inserted into the external acoustic meatus to prevent

possible infection and to arrest bleeding. Dressing should be renewed every day. If the function of the internal ear is upset, the patient must remain in bed during the first five days. Envigorating and anti-inflammatory therapy is prescribed. Beginning with the sixth day the therapy must comply with the character and foci of affection.

Patients with barotrauma can be treated in hospital and out-patient conditions, depending on the symptoms of the affection.

Foreign bodies in the external acoustic meatus usually occur in children. These can be buttons, balls, stones, peas, and other small objects that children can push into their ears during game. But foreign bodies in the external acoustic meatus of adults are not infrequent either. These can be fragments of matches, cotton and other objects that are commonly used for cleaning the ear from wax or water. In rare cases, insects can get into the ear during night sleep. The skin around a foreign body can get inflamed, or even wounded and ulcerated. Foreign bodies can absorb moisture, be covered with earwax and swell to clog the external acoustic meatus.

Diagnosis can only be established by otoscopy.

The simplest and safe method of removing foreign bodies from the ear in uncomplicated cases is by irrigation with warm water using a Janet's syringe of 100-150 ml capacity. The procedure is the same as in removing earwax (Figs 62, 63).

If a foreign body is swollen (a pea or a bean), it should first be dehydrated by instilling a 70 per cent alcohol into the meatus for 2-3 days. The swollen object shrinks and can easily be removed. Insects are killed by a few drops of pure alcohol or warm liquid oil and then removed by irrigation.

ABNORMALITY OF THE EXTERNAL EAR

Abnormalities of the ear auricle occur comparatively rarely. They can be divided into two groups: congenital and acquired (in trauma).

Congenital defects include abnormal enlargement of the pinna (macrotia), abnormally small pinna (microtia), or outstanding auricle (flop ear). Developmental defects also include congenital atresia of the external acoustic meatus. These defects can be corrected surgically.

INFLAMMATORY DISEASES

Erysipelas. This can be either primary or secondary. In the latter case the inflammation extends from the skin of the face or the head. The causative factor is the haemolytic streptococcus (less frequently, staphylococcus or other microbes).

Symptoms. Marked hyperaemia and swelling of the skin of the entire auricle, including the lobule. The ear is very tender to palpation. The bullous form is characterized by formation of vesicles (bullae) with serous fluid. If the affection is circumscribed, the affected site is separated from intact skin by a ridge of swollen tissue of a different colour. The body temperature is high (to 39-40 °C); the patient feels chill and burning sensation in the zone of the ear. The erythema and swelling extend outside the ear and the mastoid process (characteristic signs of erysipelas).

Treatment. Sulphanilamide, sulphaethidole or sulphadimidine (per os) are effective. The preparation should be given in a dose of 3-4 g a day, in equal portions at 4-hour intervals. Chloramphenicol (0.5 g) should be given four times a day. Tetracycline (100 000-200 000 U, 5-6 times a day), oletetrin (100 000-150 000 U, 4-6 times a day) and erythromycin (100 000-250 000 U, 4-5 times a day) are useful. Penicillin (300 000-500 000 U, 4-5 times a day) can also be injected intramuscularly. Light treatment (UV) is applied to the affected skin (erythema dose) and neutral or anti-inflammatory ointments should be applied.

Perichondritis is a diffuse inflammation of perichondrium. The skin of the external ear is also involved as a rule. Serous and suppurative perichondritis are distinguished. The latter occurs more frequently. Perichondritis is caused by infection, mostly by blue pus bacillus, which affects the perichondrium of an injured auricle.

The first and the main *symptom* is pain in the external ear or the acoustic meatus. Pain can precede reactive infiltration of the skin of the external ear. Soon swelling develops and extends onto the entire pinna except the lobule. Fluctuation can be felt in the swelling because purulent exudate is collected between the perichondrium and the cartilage. Palpation of the pinna is very painful.

Diagnosis is simple. At the early stage, perichondritis should be differentiated from erysipelas, phlegmona, and haematoma of the external ear.

Treatment. Local and general anti-inflammatory treatment is given during the initial stage of the disease. Erythromycin (100 000-250 000 U 4-6 times a day per os), tetracycline, oletetrin or oxytetracycline (100 000-150 000 U 4-6 times a day per os) are

effective antibiotics. The blue pus bacillus is more sensitive to them.

Burow's solution and alcohol fomentations are effective; the affected part of the pinna is treated with a 5 per cent iodine tincture and a 10 per cent silver nitrate solution. In the absence of contraindications, physiotherapy (UV and UHF) is obligatory.

In the presence of fluctuation, the tissue should be incised parallel to the pinna contours and the necrotized matter removed from the abscess cavity. A tampon soaked in antibiotic solution should then be placed into the empty cavity. The pinna deformation is possible.

Eczema is a frequent disease which develops due to irritation of the skin of the pinna and the external acoustic meatus with the discharge in acute and chronic otitis media, with iodine preparations, and in prolonged exposure to coal or cement dust. Eczema can result from sensitivity to various substances (allergic form) or due to other systemic diseases, such as diabetes mellitus or some forms of metabolic disorders.

Exudative diathesis, rickets, and often tuberculosis can cause eczema in children. Eczema of the external ear develops after injuries with infection and impairment of the local resistance.

Acute and chronic forms of the disease are differentiated. Only superficial layers of the skin are involved in acute eczema, while in the chronic disease the deep underlying layers are also involved.

Symptoms. The initial stage of acute eczema is characterized by hyperaemic and thickened skin of the pinna and external acoustic meatus due to infiltration. The acoustic meatus is markedly stenosed. The patient complains of constant and severe itching in the ears. The skin is scratched. Small blisters containing serous fluid appear. They open spontaneously releasing the fluid. Weeping develops.

Diagnosis is based on the anamnestic data and clinical findings (erythema, thickened skin, weeping, crusting or desquamation).

Treatment is directed at eliminating the main cause of eczema. The affected areas should be cleaned with ether or alcohol every day. To lessen itching, talcum or zinc oxide powders are used.

Daily use of locally applied corticosteroids is effective for weeping and desquamation.

Crusts should first be softened with vegetable or vaseline oil and then removed and oxytetracycline or prednisolone ointment should be applied.

Medication should be combined with physiotherapy: UV light (suberythema doses, 5-10-minute exposures) and UHF-therapy. Spe-

cial attention should be paid to the general condition of the patient, a child in particular.

Furuncle of the external acoustic meatus is an acute purulent inflammation of a hair follicle with circumscribed inflammation of the dermis and subcutaneous tissue of the cartilaginous part of the acoustic meatus. The general predisposing factors are metabolic disorders, for example, upset carbohydrate metabolism, malnutrition, avitaminosis, etc.

The leading *symptom* is severe pain. The pain radiates into the eye, teeth, neck, and sometimes becomes diffused in the entire head. Pain intensifies during talking and chewing because the head of the mandible is periodically displaced to press the walls of the external acoustic meatus and hence the inflamed skin.

Severe pain arises when the tragus or the inferior wall of the acoustic meatus is pressed, or when the pinna is pulled. Otoscopy reveals a rounded prominence of hyperaemic and inflamed skin, which narrows the lumen of the meatus. The regional parotid lymph nodes are enlarged, dense, and tender to palpation.

If the furuncle is located on the anterior or inferior wall of the incisura intertragica, the infection can extend onto the parotid gland and cause its inflammation. Furuncles often burst spontaneously on ripening and the patient feels alleviation of pain and his condition gradually improves. The length of the disease depends on relapses. On an average, the disease lasts 7-10 days.

The general examination of the patient includes urine and blood tests for sugar (recurrent furuncle is closely associated with diabetes mellitus).

Treatment. Antibacterial preparations (sulphanilamide 1 g 4 times a day per os, erythromycin or tetracycline, 100 000 U 4 times a day per os; penicillin injections, 500 000 U 4 times a day or sigmamycin 100 000 U 4 times a day for severe cases) should be administered during the first days of the disease. A turunda soaked in boric alcohol or a penicillin solution in novocain should be inserted into the external acoustic meatus. This is an effective local anti-inflammatory means. Sometimes, especially when the process gradually alleviates, penicillin, sulphanilamide or a 1 per cent chloramphenicol emulsions and a warming compress are used. Antipyretics and analgesics are recommended: acetylsalicylic acid, amydopyrine and similar preparations. Autohaemotherapy is sometimes used: 2-3 intramuscular injections of blood taken from the patient's

vein (7-10 ml at a 48-hour interval). Physiotherapy (UHF and UV) is effective as well.

In cases when the furuncle has ripened and the pain syndrome intensified, the danger of lymph nodes suppuration arises, and the furuncle should be opened surgically.

Diffuse inflammation of the external acoustic meatus. If infection penetrates through minor injuries in the skin (that can be inflicted during manipulations in the ear) diffuse inflammation can develop. Maceration of the skin in chemical and thermal burns also facilitates infection with pyogenic and other microbes. This form of otitis externa becomes diffuse and the tympanic membrane is involved. Inflammation spreads into deeper layers of the skin and subcutaneous cellular tissue. This process usually develops in the presence of allergy or metabolic disorders.

Symptoms. The clinical picture of the disease includes the symptoms of weeping eczema and the furuncle of the ear (skin itching, putrefactive discharge, the tragus painful to palpation, etc.).

The symptoms are less marked in the chronic form of the disease. The leading symptom is thickened skin in the external acoustic meatus and the tympanic membrane due to inflammatory infiltration.

Treatment. Balanced diet rich in vitamins should be prescribed. Anti-inflammatory therapy should be conducted. A warming compress is useful. In the presence of discharge a warm 2 per cent boric acid solution or furacin (1:5000) should be used for irrigation. After the procedure, the external acoustic meatus should be dried thoroughly and powdered with boric acid (Fig. 64). Drops of a 1 per cent menthol in peach kernel (persic) oil, a 2 per cent sulphathiazole ointment or a 1-2 per cent yellow mercuric oxide ointment are effective for itching. Application of a 2-3 per cent silver nitrate solution or a 1-2 per cent alcohol solution of brilliant green, prednisolone ointment, hydrocortisone emulsion and some other medicines are effective. UHF- and UV-therapy produce a favourable effect too.

Desensitizing therapy (diphenhydramine hydrochloride, 0.05 g 2-3 times a day, promethazine hydrochloride, 0.025 g twice a day)

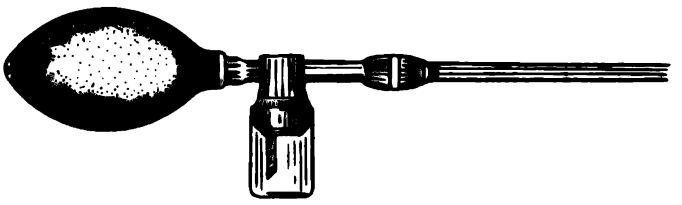

Figure 64
Powder insufflator

is indicated for allergic process. The patient should undergo an allergological examination. As a rule, the patient soon recovers.

Otomycosis is a fungal disease characterized by the growth of moulds of the genus *Aspergillus, Penicillium, Rhizopus*, and also yeast-like fungi *Candida* on the walls of the external acoustic meatus. The promoting factors are general and local allergy, metabolic and neurohormonal disorders, and dysfunction of the ceruminous glands. Fungi grow to form a dense network of mycelium, which causes inflammation of the skin.

Fungal infection of the external ear usually begins unnoticed by the patient. The main *symptoms* are constant and severe itching (pruritis), increased sensitivity of the acoustic meatus and the pinna, stuffiness and noise in the ears; in the absence of exacerbation, pain in the ear is mild. Some patients complain of headache on the involved side.

Mould-caused otomycosis is characterized by pathological exudation in the external acoustic meatus, which looks like wet blotting paper. The colour of the discharge varies and depends on the colour of the mycelium. It can be dark-brown if the ear is affected by *Aspergillus niger*, yellow or greenish in infection with *Aspergillus flavus* and *Aspergillus glaucus*, and greyish-black in affections with *Aspergillus fumigatus*.

Otomycosis caused by the fungi of the genus *Candida* is characterized by liquid serous discharge in the external acoustic meatus with soft yellowish-white easily detachable crusts throughout its entire length.

The clinical picture of otomycosis caused by yeast-like fungi resembles that of weeping eczema of the external ear. In candidomycosis the process propagates onto the pinna and the retroauricular zone. A person can get infected when using a telephone receiver.

Prophylaxis includes treatment of the pathological processes that can promote the onset of the disease, prevention of inflammation of the external ear, and increasing the protective forces of man. Careful cleaning of the external acoustic meatus in the presence of acute and chronic otitis media without damaging the ear is important. Rational general and local antibiotic therapy (after testing the microbial flora for sensitivity to a particular antibiotic) is an effective prophylactic measure against otomycosis.

Diagnosis should be confirmed by microscopic examination of the discharge from the external acoustic meatus.

Treatment. The specific local antifungal therapy should be prescribed separately for each particular patient after thorough examination of his condition and the clinical picture of the disease, and depending on the particular causative agent.

Flavofungin is effective against *Aspergillus niger* and *Aspergillus glaucus*, grisein and nystatin are effective against *Candida*; and lutenurin is effective against *Aspergillus glaucus* and *Candida albicans*.

Good curative effect is attained with local use of antifungal preparations: 1 per cent grisein emulsion, 0.5 per cent lutenurin emulsion, nystatin emulsion (standard ointment containing 100 000 U of nystatin in 1 g, diluted with peach kernel oil 1:1) and a 2 per cent alcohol solution of flavofungin. The external acoustic meatus should first be thoroughly cleaned with hydrogen peroxide, and then a turunda, soaked in one of the mentioned antifungal preparations, is inserted into the ear and kept there for 20 minutes. The procedure should be repeated two or three times a day for 2-3 weeks.

Desensitizing treatment is indicated for marked general or local allergy.

Relapses of otomycosis are possible with all types of treatment. In order to prevent them, the external acoustic meatus should be treated once a day with an antifungal preparation during one month following complete clinical recovery.

Earwax (cerumen) plug is produced as a result of upset function of the glands in the cartilaginous part of the external acoustic meatus. Earwax is the dried up secretion of the ceruminous glands mixed with desquamated epithelium. If the glands function normally, the cerumen dries into small crusts which are then easily removed from the meatus due to movement of its anterior wall during movement of the jaw (in talking and chewing).

If the secretion remains in the ear for a long time, the epidermal plug dries into a dense clot that is firmly fixed in the meatus of the ear. The leading *symptom* of the earwax impaction is impairment of the hearing function, often noise in the ear, and autophonia (conduction of own voice into the ear). In this case the acoustic meatus is obturated with ceruminous mass completely. Vertigo, headache, nausea, and cardiac dysfunction develop sometimes as well.

Treatment. Irrigation of the external acoustic meatus is an effective means. The following rules should be observed when carrying out this manipulation. First, it is necessary to establish

if the patient had diseases of the ear in the past, since the tympanic membrane might have been perforated during this disease. Irrigation of the ear with a perforated tympanic membrane is dangerous because water can penetrate into the middle ear, exacerbate the process, and cause pus discharge. Earwax should in such cases be removed using a hooked probe. Earwax plug can be removed by irrigation only on the condition that obturation of the acoustic meatus is incomplete.

Warm (37° C) water should be used for irrigation of the ear. Cold water can irritate the labyrinth with subsequent unpleasant sensations for the patient (vertigo, nausea, vomiting, etc.). After irrigation, it is necessary to examine the eardrum. Remaining water should be removed from the ear with sterile turunda or dry cotton wound around an applicator. The entrance to the meatus should be closed with cotton for a short time.

A Janet's syringe (capacity 100-150 ml) should be used for irrigation of the ear. A jet of water should be directed on the posterosuperior wall of the acoustic meatus, which should be straightened by pulling the pinna up and back. Earwax plug can sometimes be removed by parts. Soft earwax can be removed by irrigation only, while a solidified mass should first be softened by instilling warm (37° C) drops of sodium bicarbonate in glycerol 3 times a day for 10-15 minutes, during 2-3 days.

Rp.: Natrii hydrocarbonatis, 0.5
Glycerini
Aq. destill. āā 5.0
DS: 10 drops into the ear, 3 times a day. Warm before use.

Before instilling drops, the patient should be warned that his hearing can temporarily be impaired as a result of swelling of the earwax plug in his ear.

Epidermal plugs should be removed from the ear in the same way. The plug should also be softened by instilling drops. Using a hook to remove the plug requires certain skill on the part of the operator.

DISEASES OF THE MIDDLE EAR

Pathological changes occurring in various parts of the middle ear are quite varied. The polymorphic character of these changes depends on some factors and in the first instance on the anatomical and physiological connections with the upper airways. The

virulence of the infectious agent and the immunological condition of the macroorganism are no less important in the development of otitis media.

Depending on the length of the disease, acute and chronic processes are distinguished; as related to the stages of the inflammatory process, they can be catarrhal, serous, and purulent otitis media.

CATARRHAL OTITIS

Acute catarrhal otitis media occurs during transition of inflammation from the nose and nasopharynx onto the mucosa of the auditory tube and the middle ear. Various microorganisms, e. g. streptococci or staphylococci (pneumococci prevail in children) can be the causative agents. Inflammation of the mucosa of the auditory tube causes its stenosis or closure to account for hearing loss.

Acute inflammation of the middle ear is so closely connected with the pathology of the auditory tube that these two pathologies would be usually considered as mutually dependent. It should be remembered that a normal lumen of the auditory tube is not open because its walls contact each other in the cartilaginous part. The auditory tube opens only during swallowing and chewing to ensure ventilation and drainage of the tube.

The diseases of the auditory tube, and hence impairment of its patency, are often associated with difficult nasal respiration due to polyps, hypertrophied conchae, adenoids (mostly in children), rhinopharyngitis, vasomotor processes, diseases of the paranasal sinuses, and tumours. Purely mechanical closure of the auditory tube (its nasopharyngeal orifice) with adenoids, tubal tonsils, or a tumour should be differentiated from the obstruction caused by its swollen inflamed mucosa. In the former case the obstruction is more persistent while in the latter it is only transient.

The air (mainly oxygen) in the tympanic cavity is absorbed by the capillaries and the pressure thus decreases. The tympanic membrane is then retracted to partly compensate for the pressure change in the tympanic cavity. A prolonged and considerable rarefaction of air in the middle ear causes venous stasis in the mucosa of the tube and the middle ear and evokes transudation; the early stage of aseptic inflammation thus begins.

Symptoms. The main complaint of the patient is stuffiness in one or both ears, hearing loss, discomfort in the head, noise in

the ear, and autophonia (resonance of own voice in the diseased ear). As a rule, pain in the ear is absent. The general condition of the patient is not substantially deranged. The body temperature is usually normal.

Some patients complain of 'liquid in the depth of the ear' as they incline or turn their head. But they also report improvement of hearing in such cases which is associated with transudate movement in the middle ear during movement of the head.

The degree of hearing loss depends on the amount and consistency of the transudate and its pressure on the tympanic membrane, the osseous chain, and the labyrinthine windows.

The tympanic membrane can be pale-grey, yellowish, less frequently brown, blue, or lilac-blue. The latter three colour shades depend on the presence of decomposing erythrocytes in the transudate.

Treatment includes treatment of the nose, nasopharynx, and restoration of patency of the auditory tube.

If adenoids, hypertrophic rhinitis, polyps, or deviated nasal septum are the main causes of the disease, surgical treatment is necessary (after catarrh abatement). In order to lessen the swelling in the orifice of the auditory tube, vasoconstrictors should be given: drops of ephedrine, adrenaline and similar solutions should be instilled into the nose. Thermotherapy is used to accelerate resolution of the transudate. These are warming compresses, UV rays, etc. The ventilating and draining functions of the auditory tube are restored by the *Politzer treatment* and by pneumatic massage of the tympanic membrane. Two or three blowing sessions will be sufficient in some cases to arrest the disease. If the disease is long-standing, the treatment should be repeated 3-4 times a week (for 2-3 weeks). These procedures, together with pneumatic massage of the tympanic membrane prevent chronic process in the middle ear, but they must not be conducted in the presence of acute inflammation in the nose, because infection can be carried from the nose into the middle ear. Anti-allergic preparations, such as diphenhydramine hydrochloride or promethazine hydrochloride are recommended for peroral administration. If the allergen is known, the patient can be given specific treatment.

Catheterization of the auditory tube with administration of a hydrocortisone suspension (10-15 drops for each procedure) into the middle ear is effective. If necessary, this procedure is repeated 2-3 times, every other day. The patient sometimes recovers after the very first procedure.

If tenacious secretion is present in the middle ear and it is

difficult to remove it, hydrocortisone should be alternated with administration of proteolytic enzymes which thin the secretion. Paracentesis or myringotomy are sometimes necessary to evacuate the transudate from the tympanic cavity.

Chronic catarrhal otitis media (adhesive otitis) is usually secondary to acute otitis media but sometimes the process is chronic in its character from the very onset. The impairment of the tubal function in such cases is not immediate but develops gradually (especially in chronic diseases of the upper airways).

The leading *symptoms* are partial hearing loss and noise in the ears. Otoscopy is quite characteristic. The tympanic membrane is opaque and strongly retracted. The shorter process of the malleus is more sharply outlined and the manubrium of the malleus looks longer; the cone of light disappears or its margins become indistinct. Excessive growth of cicatricial tissue in the middle ear and the tympanic membrane can cause deformation of the membrane. On increasing and decreasing air pressure in the external ear with a Siegle's otoscope a limited mobility or immobility of the tympanic membrane can be seen. The absence of effect with ear inflation (Politzer's) does not always indicate conduction disturbances. Catheterization under otoscopic control should be used. This manipulation requires certain skill and carefulness on the part of the operator. Chronic otitis media is usually associated with upset sound conduction but perceptive disorders can later develop.

Treatment. This includes abatement of possible diseases in the upper airways. Adenotomy should be performed in children if necessary. Politzer's treatment or catheterization with simultaneous pneumatic massage of the tympanic membrane (using a Siegle's speculum or otoscope) are effective. The course of treatment includes 15 sessions (every other day). The course should be repeated in 3 months. In order to increase the elasticity of the cicatrices and to restore mobility of the ossicles, hyaluronidase (0.1 g of solution in 1 ml of a 0.5 per cent novocain solution) should be administered into the middle ear through a catheter (or by injection through the tympanic membrane). The course includes 4-5 procedures, which should be repeated at 4-day intervals. Electrophoresis of hyaluronidase (endaural) and diathermia on the ear zone are sometimes used. If scars are severe and the conservative treatment fails, tympanotomy is used to incise the scars. The operation is effective to restore patency of the auditory tube. Auditory prosthetics is indicated for the aged and also in the presence of bilateral commissures with severe bilateral hearing loss.

AERO-OTITIS (BAROTITIS)

Aero-otitis (barotitis) is associated with changes in the middle ear caused by barotrauma, for example, in flights.

The factors that are decisive for the damage of the middle ear are the air pressure difference, the speed at which this difference is attained, and the degree of patency of the auditory tube (Plate IX).

The tympanic membrane and the other structures of the middle ear can stand a significant increase in atmospheric pressure but on the condition that the pressure rise is slow and the pressure in the middle ear increases correspondingly. If this condition is not fulfilled, barotitis develops (mostly during a rapid ascent or descent in an airplane). In cases when the difference between the air pressure in the external and middle ears can be very great, barotitis develops with impairment of the tubal patency. The patient complains of stuffiness in the ears and pain of varying intensity, tinnitus and sometimes vertigo. In mild cases, otoscopy reveals retraction of the tympanic membrane and vascular injection in the malleus manubrium. In severe cases, diffuse hyperaemia of the tympanic membrane, submucous haemorrhage into the eardrum, and serous-sanguinous exudate can be seen. The tympanic membrane can rupture in severe cases. Changes in the hearing function correspond to the degree of affection of the conductive system.

Treatment should be directed at restoring the ventilating and draining functions of the auditory tube. Vasoconstrictive preparations should be instilled into the nose. A turunda soaked in boric alcohol should be inserted into the external acoustic meatus.

ACUTE OTITIS

Acute inflammation of the middle ear is quite common. In some patients the disease runs a mild course, while in others it is severe and long-standing, with subsequent transition into the chronic form.

Acute otitis media involves not only the tympanic cavity but also the other parts of the middle ear, such as the auditory tube, the antrum, and the cells of the mastoid process.

The direct cause of acute otitis media is infection of the middle ear with streptococci, staphylococci, pneumococci, and less frequently other microbes; mixed flora is sometimes responsible for the onset of the disease. Acute otitis media is often secondary. It can be a complication or a manifestation of a systemic infection,

for example, infection of the upper airways and influenza; scarlet fever, measles, diphtheria and some other diseases provoke acute otitis media in children. It can be due to acute and chronic inflammation of the pharynx and the nose. Hypertrophic processes in the nose and nasopharynx can be important in the aetiology of the disease. The main pathological factor is mechanical compression of the pharyngeal orifice of the auditory tube and impairment of its ventilating and draining functions. Among such diseases are hypertrophic rhinitis, adenoids, choanal polyp, hypertrophic pharyngitis, polyps of the nose, tumours of the pharynx. Less frequently otitis is secondary to injuries to the ear.

In addition to the mentioned pathological factors, the leading role in the aetiology of this disease belongs to the decreased local and general reaction of the body often associated with general viral and microbial infections. Chilling and cooling of the entire body or its separate parts are often the provoking factors too.

Infection usually enters the middle ear through the auditory tube. Under normal conditions, there is no microbial flora in the cavities of the middle ear. Less frequently infection gets into the middle ear through an injured tympanic membrane or through the damaged mastoid process. In rare cases infection penetrates into the middle ear by haematogenic routes (in infectious diseases, such as scarlet fever, measles, typhus, tuberculosis, etc.).

Three periods are distinguished in a typical course of acute suppurative otitis media. The first period is characterized by the onset and development of inflammation in the middle ear, infiltration and exudation, and development of minor symptoms, such as earache, hyperaemia of the tympanic membrane, protrusion of the membrane due to the thrust of the exudate, hearing loss, and some general symptoms such as elevation of body temperature to 38-39 °C, deranged appetite and sleep, indisposition, moderately high leucocyte count, and insignificant acceleration of the erythrocyte sedimentation rate.

The second period is perforation of the tympanic membrane and discharge of pus (Plate X). All reactions subside. Otopyorrhoea lasts 47 days. Perforation of the tympanic membrane and otopyorrhoea occur in connection with increased exudation from the tympanic cavity and its increasing pressure. As a result, the tympanic membrane thins and ruptures usually in its anteroinferior quadrant. Perforation of the tympanic membrane sharply changes the course of acute otitis: earache subsides and disappears, temperature normalizes quickly, palpation of the mastoid process be-

comes less painful, and the general condition of the patient improves.

Inflammation subsides in the third period. Purulent discharge discontinues, perforation closes, and the anatomical and functional condition of the middle ear is restored.

The typical course of acute otitis media can change in either direction: it can run a milder, abortive course, or the inflammation can become more severe. These deviations can occur during any of the three periods of the disease.

The first period of acute otitis media can sometimes be very grave and attended with hyperpyrexia, severe headache, vomiting, vertigo, and drastic impairment of the general condition. The fulminant reaction usually occurs in the absence of perforation and accumulation of a large amount of exudate in the middle ear. Sometimes, before the tympanic membrane ruptures, the disease can turn on a fulminating course with extension of inflammation from the middle ear into the skull cavity and cause severe intracranial complications and even death of the patient.

Deviations from the normal course of the disease in its second period are persistent pyrexia despite perforation of the tympanic membrane, and no improvement in the general condition. This is usually associated with propagation of inflammation onto the mastoid process.

During the second period of the disease, after the local and general symptoms subside and body temperature normalizes, the patient's condition can worsen again and the body temperature rises; pain in the ear develops. This can be due to inadequate drainage of pus and its retention in the middle ear cavities. The discharge of pus can be difficult if the perforation is small or if the mucosa is granulated or papilla-like formations grow in the tympanic cavity to interfere with the escape of the exudate. Painful palpation of the mastoid process during the second and especially the third period indicates atypical course of the disease and a possible complication, mastoiditis. Profuse otopyorrhoea, and especially pulsation of the pus indicate the presence of an extradural abscess. The inflammation of the middle ear can be considered chronic if it persists for more than 6 weeks. Sometimes acute otitis media can run a chronic course from the very onset, for example, tuberculous otitis media.

Changes in the blood of patients with mild otitis during the first days of the disease are characterized by moderately high leucocyte count without marked shift of the neutrophilic series to

the left and slight acceleration of the erythrocyte sedimentation rate. In severe acute otitis, the leucocyte counts are high (sometimes to $20 \times 10^9/1$ and over) with a considerable shift to the left. After perforation of the tympanic membrane and discharge of pus, the blood picture gradually normalizes.

If the disease runs a typical benign course, the patient usually recovers with resolution of the inflammation and complete restoration of the hearing function. The small perforations in the tympanic membrane close leaving no trace. Dense scars can be formed with deposition of lime salts (petrificates) which appear as white spots. If the disease runs an atypical course, the outcomes can be different, with adhesions and commissures between the tympanic membrane and the medial wall of the middle ear, or between the ossicles which limits their mobility and impairs hearing (adhesive otitis media); persistent dry perforation (dry perforating otitis media); conversion of acute disease into its chronic form with persistent perforation and periodic otopyorrhoea; complications, such as mastoiditis, petrositis, labyrinthitis, paresis of the facial nerve, intracranial complications, etc.

Treatment includes sparing conditions at home; if the body temperature is high and the general condition is poor, the patient must stay in bed. If mastoiditis, and especially intracranial complications are suspected, the patient must be immediately taken to hospital. The diet should be easily assimilable and rich in vitamins to ensure the normal function of the gastro-intestinal tract.

Vasoconstrictors or astringents should be instilled into the nose for restoration or improvement of ventilation and drainage of the auditory tube.

Rp.: Sol. Adrenalini (1:1000), gtt. X;
Rp.: Sol. Ephedrini hydrochl., 3%, 10.0;
Rp.: Sol. Protargoli, 2%, 10.0

The drops should be instilled three times a day, five drops into each nostril (in the supine position).

The patient should be asked not to blow strongly his nose with both nostrils closed simultaneously. The patient must not draw the nasal secretions into the mouth because this can increase pressure in the middle ear and the infected secretions can penetrate into the tympanic cavity from the nose and the nasopharynx.

Sulpha drugs and antibiotics should be prescribed. Sulpha drugs (sulphadimidine, sulphanilamide, etc.) and antibiotics (tetracycline, penicillin, oxytetracycline, oletetrin, erythromycin, etc.) arrest the pathological process and promote its rapid resolution. High con-

centration of antibiotics and sulpha drugs in the blood is necessary for successful treatment. Sulpha drugs should be given to adults in a dose of 1 g 4-6 times a day; the antibiotic (the tetracycline series) should be given 1 tablet (100 000 U) 6 times a day.

This treatment must be continued for 4-6 days even if the condition of the patient improves markedly and the local symptoms subside. Untimely suspended medication only masks the true course of the inflammation in the ear; this provides conditions for its relapse and formation of adhesions and commissures in the tympanic cavity thus promoting the onset of persistent hearing loss.

If acute otitis media runs a severe course with marked general and local symptoms, penicillin is injected intramuscularly 500 000 U four times a day for at least 5-6 days. If the microbial flora is not sensitive to penicillin, another antibiotic should be tried. It is necessary to remember that streptomycin, kanamycin and monomycin are contraindicated for local and general use because of their toxic effect on the cochlear and vestibular apparatus. The antibiotic therapy should be combined with nystatin and vitamins.

Analgesics (amidopyrin) and antipyretics (acetylsalicylic acid) should be given for severe headache and pyrexia. Warming compresses should be placed on the mastoid process. Compresses should be prepared as follows: gauze should be folded four or five times and soaked in alcohol diluted with water or Burow's solution (1:1); excess fluid should be squeezed out and the gauze placed on the ear. In order to prevent displacement of the compress, a hole should be cut out in the gause to pass the pinna. An oil cloth or any other water-proof material and cotton wool or soft textile fabric should then be placed. The compress is fixed in place by a kerchief or bandaging. The compress should be changed at 4-5-hour intervals. A UV-lamp is recommended for warming up the ear.

Some patients do not tolerate compresses and they produce no desirable therapeutic effect on them. Cold (ice bag) should then be applied for 10-15 minutes. In order to prevent the adverse effect of cold on the ear, cotton wool or a towel should be placed between the ear and the ice bag. An ice bag to children should be applied for 3-5 minutes.

Catheter perflation of the tympanic cavity facilitates drainage of the middle ear and removes air rarefaction which always attends acute otitis media; blowing is also used to insufflate medicinal preparations. Moreover, this procedure normalizes the function of the auditory tube and has a favourable effect on the

course of inflammation. The danger of carrying infection from the pharynx into the middle ear is absent, because the pharyngeal microflora is already present in the middle ear while the protective function of the auditory tube is almost completely lost. The ear should be catheterized during the catarrhal stage of otitis because this often aborts the disease. Blowing through a catheter is also effective during the second and third stages of acute otitis media. The procedure should be performed once a day, during 3 or 4 days. A suspension of hydrocortisone mixed with penicillin (sigmamycin, tetraolean, etc.) in an isotonic sodium chloride solution (50 mg of hydrocortisone, 300 000 U of penicillin in 2 ml of isotonic sodium chloride solution) should be administered into the middle ear through a catheter (10-15 drops). Ototoxic antibiotics (e. g. streptomycin or monomycin) must not be administered into the ear. The patient should be tested for sensitivity to each particular antibiotic.

If the tympanic membrane is perforated, the medicinal preparations can be administered into the middle ear through the external acoustic meatus (transtympanic administration). To that end, the mentioned mixture (1 ml) should be instilled into the acoustic meatus and forced into the tympanic cavity by gently pressing the tragus into the external orifice of the acoustic meatus 5 or 6 times. In order to ensure a reliable seal, the entrance to the meatus should be wetted with the same mixture. The medicinal solution can pass the middle ear, the auditory tube, and enter the mouth and nose in the form of foam. Catheterization and transtympanic administration of medicinal solutions are effective means of treatment.

In rare cases, when this treatment fails and severe pain in the ear persists, the body temperature remains high and the tympanic membrane bulges outside, it is necessary to incise the tympanic membrane. Paracentesis is positively indicated for irritation of the middle ear or meningeal irritation which are manifested by vomiting, vertigo, severe headache, and other signs. Paracentesis is more frequently indicated for children because their tympanic membrane is thicker (especially in nursing infants) and it resists rupture stronger than in adults, while the local and general symptoms (pain, pyrexia) are more pronounced.

Paracentesis. The tympanic membrane is incised using a special needle (Figs 65, 66) and observing the rules of asepsis. The manipulation should be performed under visual control. The operation is very painful and should therefore be done under

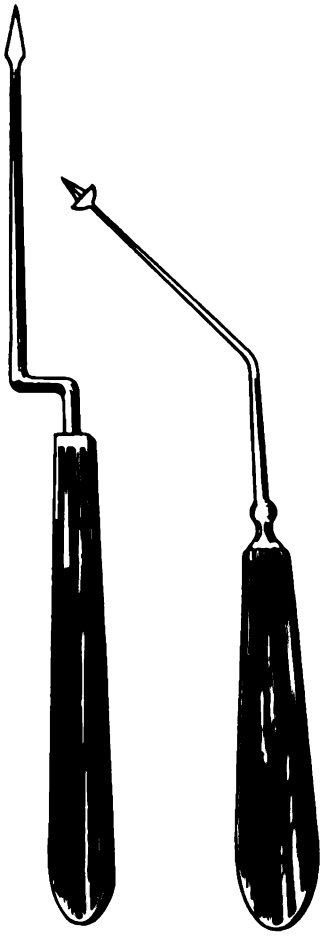

Figure 65
Paracentesis blades

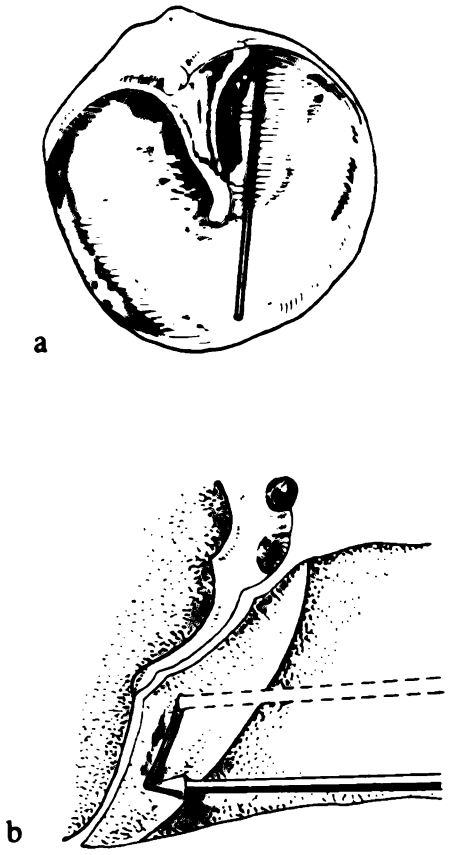

Figure 66
Paracentesis of the ear-drum (myringotomy):

a – line of incision;
b – the arrow shows the direction of the cutting blade

local anaesthesia. Light ether narcosis (ether-rausch) is sometimes given to very restless children.

The patient should sit upright or partially inclined. His head should be held firmly. When performing paracentesis in children, not only the head but the whole body must be immobilized.

Special conditions must be provided for unobstructed drainage of pus from the ear after paracentesis. This can be attained by inserting a special turunda which absorbs pus. Turundas should be changed at short intervals. The external acoustic meatus must be cleaned thoroughly using sterile hygroscopic cotton which is wound around a serrated end of an applicator. The ear should be cleaned under visual control using a head mirror.

If the patient himself cleans his ear and instills drops, he

must be instructed how to do it properly. The patient can use an applicator around which cotton should be wound. The tuft at the end of the cotton ball must be left loose. The pinna of adults should be pulled up and back and in children down and back. The applicator must be moved slowly and carefully until it reaches the tympanic membrane. In 5-7 seconds the cotton should be pulled back. Cotton should be changed and the manipulation repeated. The medicinal solution should then be warmed to 37 °C and instilled into the external acoustic meatus. The patient must incline his head in the opposite direction. The medicine should be kept in the ear for 10-15 minutes and then withdrawn by tilting the head in the reverse direction. The acoustic meatus should be dried up and closed with a cotton ball or a sterile turunda. These simple procedures should be repeated 2 or 3 times a day (depending on the amount of pus that is to be drained).

The external acoustic meatus should be smeared every other or third day with prednisolone ointment or other medicinal preparations in order to prevent irritation and maceration of the skin. It should be remembered that accumulation and retention of pus in the external acoustic meatus irritates the skin and causes its inflammation which interferes with drainage of pus and promotes its accumulation in the middle ear.

Prevention includes a combination of measures such as control of infectious diseases, timely treatment of acute and chronic diseases of the nose, paranasal sinuses, and the nasopharynx. In the presence of deviated nasal septum, hypertrophied conchae or polyps, surgical intervention is necessary. Surgery is performed to restore the respiratory function of the airways and the auditory tube. Treatment (conservative and surgical) of suppurative sinusites is very important, especially in children in whom acute otitis media is often secondary to adenoids which close the openings of the auditory tubes and thus interfere with normal ventilation of the middle ear.

Hardening of the body is a very important general preventive measure.

Allergic otitis media. Allergic otitis is an independent nosological entity. It is characterized by specific symptoms of allergic inflammation and often occurs in the presence of a general allergic reaction of the body.

The onset of acute allergic otitis is associated with allergic oedema of the mucosa in the auditory tube and the middle ear and liberation of serous secretion. As distinct from the other

forms of otitis, the body temperature is normal in this form, the tympanic membrane is not hyperaemic and remains pale, thickened and slightly bulging; a fluid level can sometimes be seen through the membrane. On paracentesis a viscous and tenacious mucus containing many eosinophils is discharged.

Anamnestic data (sensitivity to various substances, foods, etc.), concurrent allergic diseases (bronchial asthma, nettle rash, etc.), positive intracutaneous tests with bacterial and non-bacterial allergens, eosinophilia in the blood and in the discharge from the ear are important to confirm the allergic nature of otitis. A sample of the material contained in the middle ear is taken by puncturing the inferior quadrant of the eardrum with subsequent suction of the material into the syringe. Anaesthesia is necessary like in paracentesis.

Treatment. In addition to common methods of treatment, desensitizing therapy is also carried out. If the allergen is identified, specific treatment is necessary. Non-specific desensitization should be carried out in other cases.

Acute otitis media in children. Acute otitis media in neonates and infants occurs much more frequently than in adults. Its course is specific. The special character of the symptoms is determined by the absence of general and local immunity, the morphology of the mucosa in the middle ear and the structure of the temporal bone (residues of myxoid tissue, the nutrient medium for infection growth, are present in the tympanic cavity). Inflammation of the middle ear in neonates often develops due to penetration of amniotic fluid into the middle ear through the auditory tube during birth. The infection mechanism in nursing infants is the same, but in addition to infection penetrating from the nose and nasopharynx, food can also pass into the middle ear during regurgitation.

It is more difficult to establish the *diagnosis* of acute otitis media in a nursing infant. But the behaviour of a baby with a diseased ear differs substantially from that of a healthy baby. The baby has bouts of inconsolable crying, refuses the breast because of pain during swallowing, rubs his diseased ear against the mother's hand. The main symptoms of the disease are painful palpation of the tragus (because of the absence of the bony part of the acoustic meatus) and high body temperature (39.5-40°C). A baby with otitis media is almost always depressed and sleeps a lot; his gastrointestinal function is upset; vomiting develops and wasting ensues. Meningeal symptoms with dimmed consciousness

are possible. As distinct from meningitis, this condition is called meningism and is caused by toxaemia (without inflammation of the meninges). Meningism subsides immediately after perforation of the tympanic membrane and evacuation of pus from the middle ear.

The stages of acute otitis media in a child are the same as in adults, except that the child can more frequently recover without perforation of the tympanic membrane because of its higher resistance, high absorbing power of the mucosa in the tympanic cavity and easier drainage of the middle ear through the wider auditory tube.

Treatment of otitis media in a child is the same as in adults, but paracentesis at earlier terms is indicated. An antibiotic solution and hydrocortisone suspension can be administered into the middle ear through the tympanic membrane immediately after its incision. The medicines can sometimes be injected through the tympanic membrane before the indications for its paracentesis are vivid.

Prophylaxis includes a complex of general and individual measures. Adequate nutrition and control of acute respiratory diseases and influenzal infection are the general preventive measures. These measures are the basis for prevention of otitis in nurslings, since they are directed at increasing the resistance of the child.

The envigorating measures include hardening of the body, keeping the patient in a light, dry, and well ventilated room, baths, adequate nutrition and diet rich in vitamins in accordance with the age of the patient. Exposure of children to UV rays in kindergartens (especially of children with rickets and influenzal infection) is useful. Control of rickets, hypotrophy, and diatheses is important for prevention of otitis.

Prevention of diseases of the nose and the nasopharynx is especially important because otitis media (especially in children) is often secondary to these diseases.

One of the most important preventive measures is proper hygiene of nursing and care of infants.

Acute otitis media concurrent with infectious diseases runs an especially severe course in septicotoxic forms of scarlet fever, especially in the presence of necrotic affections of the fauces and (though less pronounced) changes associated with measles and influenza.

The course of such otitis is especially severe because the patient's immunity is weakened by the pathogenic agent of the infectious

disease, which penetrates the ear mostly through the auditory tube and, less frequently, by the haematogenic routes.

Two forms of acute otitis concurrent with infectious diseases are distinguished: (1) late (secondary) otitis arising during the late period of infection, and (2) early otitis developing during the initial stage of the infectious disease and having the same signs as the main disease.

Influenzal otitis occurs usually during viral influenza epidemics. The virus penetrates directly into the ear by the haematogenic route or from the upper airways through the auditory tube. Specific influenzal otitis is characterized by haemorrhagic inflammation which is manifested by a pronounced dilatation of the vessels in the external acoustic meatus and the middle ear with extravasation (haemorrhage) under the epidermis in the bony part of the external acoustic meatus and the tympanic membrane. Extravasation appears as haemorrhagic blisters (bullae) in the mucous membrane of the middle ear.

Influenzal otitis is localized mainly in the supratympanic space. Its course is often very severe, because inflammation develops in the presence of general toxaemia, sometimes with involvement of the internal ear.

Otitis concurrent with scarlet fever and measles usually does not differ substantially from otitis associated with other infections. The necrotic form of otitis deserves mentioning.

Necrotic otitis in scarlet fever and measles usually develops during the initial stage of the disease, more frequently in the presence of necrotic affections of the pharynx and the nose; in measles, otitis develops simultaneously with rash (or before it). The causative agent of this form of otitis is haemolytic streptococcus. Pathology in the ear develops unnoticed in the septicotoxic forms of scarlet fever and measles. Pain is often absent which can be explained by the necrotic affections of the tympanic membrane; the only manifestation of the disease is profuse purulent discharge from the ear (with pungent putrefactive odour if the bone is involved).

Perforation of the tympanic membrane is vast, to complete destruction. Perforation often occurs during the first days of the disease and persists for a long time. Carious process tends to exacerbations.

Necrotic otitis is characterized by a permanent hearing loss (mixed type). Symptoms of labyrinthine affections sometimes join.

Treatment includes measures directed at eradication of the main

disease and its local manifestations. Timely and correct use of antibiotics for scarlet fever and measles has reduced significantly the incidence of purulent otitis associated with these diseases. Severe forms of otitis are very rare now.

MASTOIDITIS

Acute mastoiditis is a complication of acute otitis media. This is inflammation of the bony tissue of the mastoid process which occurs in malignant course of acute suppurative otitis media. The inflammation easily extends from the tympanic cavity onto the cells of the mastoid process through the entrance to the antrum due to the high virulence of the microbes. Local inflammation interferes with free communication between the bony system of the mastoid process and the middle ear (Fig. 67).

Primary mastoiditis begins without previous acute otitis. It occurs in rare cases associated with injury to the mastoid process, tuberculosis, syphilis, actinomycosis and metastasis in general septicaemia. Primary mastoiditis should be differentiated from mastoiditis which is secondary to acute otitis media. Incorrect use of antibiotics (underdosage) and untimely suspension of the antibiotic therapy for acute otitis, and also unreasoned abstention from paracentesis can cause mastoiditis.

Changes in the mastoid process associated with typical mastoiditis vary depending on the stage of the disease. Exudative (I) and

Figure 67
Mastoiditis (subperiosteal abscess)

proliferative-alternative (II) stages of mastoiditis are distinguished.

Symptoms. The clinical signs of mastoiditis can be local and general. The general symptoms are impairment of the patient's general condition, fever, changes in the blood, etc. They do not differ substantially from those of acute suppurative otitis media.

The subjective symptoms are pain, noise in the ears, and hearing loss. Examination of a typical mastoiditis patient reveals hyperaemia and infiltration in the skin overlying the mastoid process (due to periostitis). The pinna is displaced either anteriorly or inferiorly.

The mastoid process, especially the apex, and sometimes its posterior margin, are very tender to palpation. Inflammation in the mastoid process can be activized causing subperiosteal abscess due to passage of pus from the mastoid cells to the periosteum. The onset of mastoiditis is often characterized by high body temperature, which is especially vivid after its normalization following perforation of the tympanic membrane. The differential blood count shifts to the left; the leucocyte count is moderately high; the ESR gradually increases. The general condition of the patient and his appetite are impaired.

The specific otoscopic symptom of mastoiditis is sagging soft tissue of the posterosuperior wall of the bony part of the external acoustic meatus at the tympanic membrane (the anterior wall of the antrum). Otopyorrhoea is often pulsating and profuse. The consistency of pus is often creamy. Pus can fill the acoustic meatus immediately after its cleaning. Ordinary otopyorrhoea through the perforated tympanic membrane is sometimes accompanied by the escape of ample pus through the posterior wall of the external acoustic meatus. In order to assess correctly the intensified discharge of pus, it is necessary to clean thoroughly the acoustic meatus and to locate the fistula.

Diagnosis is not difficult. It can be established by a series of objective signs. The presence of subperiosteal abscess (with the passage of pus through the cortical layer) always indicates mastoiditis. Moreover, mastoiditis is attended with profuse otopyorrhoea, pasty consistency of soft tissues surrounding the mastoid process, sagging of the posterosuperior wall of the bony part of the external acoustic meatus, elevated body temperature, and impaired general condition of the patient.

Roentgenography of the temporal bone is very important for diagnosis. An X-ray picture shows diffuse reduction of pneumatization and shaded antrum and the cells. During later stages of the disease the bony septa can be destroyed with formation of clear sites

on X-ray pictures (due to destruction of bone and accumulation of pus).

Treatment. Depending on the stage of acute otitis media and mastoiditis, therapeutic measures include some conservative and surgical means. Conservative treatment includes administration of antibiotics and sulpha preparations (locally and intramuscularly). The patient should first be tested for sensitivity to these preparations; their effect on the microflora in the ear should also be tested. Desensitizing preparations and physiotherapy (UHF, SHF, warming compresses on the ear and the mastoid process) are used. The condition of the nose, the paranasal sinuses and the nasopharynx should be thoroughly examined in each particular case, especially in children.

If conservative treatment fails, objective symptoms intensify, and complications develop in the areas adjacent to the middle ear, surgical intervention is necessary.

Prognosis is favourable provided the patient applies to the doctor in due time and is given effective treatment.

Prophylaxis consists in early and rational treatment of acute otitis media.

Mastoiditis (antritis) in children. The mastoid process is underdeveloped in neonates and nursing infants; only a prominence can be found at the place of its future location. There is an antrum in this prominence, into which the purulent process extends from the middle ear. A subperiosteal abscess is likely to develop if the petrosquamous and tympanomastoid fissures are not closed.

The local *symptoms* are few. The otoscopic picture is characterized by indistinct topography of the tympanic membrane; its colour can be pink or slightly yellowish. X-ray pictures of temporal bones (through the orbits) reveal decreased transparency of the antrum in some cases.

Antritis is always associated with a vigorous general reaction of the child's gastrointestinal tract, the respiratory and nervous systems. The child's conduct varies from flaccidness to excitation; he cries, does not sleep; the symptoms of meningitis are not infrequent. Appetite is very poor, stools are frequent and liquid, and the baby loses his weight. The skin is pale-grey and moist; the heart sounds are dull, the pulse is frequent; tachypnoea develops. The temperature reaction does not always agree with severity of the condition. Body temperature can be normal, subfebrile or be as high as 38-39°C. The blood picture is characterized by neutrophilic leucocytosis; the ESR is accelerated.

The child should be examined and conclusion on his condition can be drawn only in cooperation with a paediatrist.

Treatment includes intramuscular injections of antibiotics and peroral administration of sulpha drugs. General envigorating therapy includes vitamin-rich diet, blood transfusion, etc. UV-therapy is helpful.

Surgical treatment includes antral puncture, antrotomy, and mastoidotomy. If treatment is correct, the patient recovers in 20-24 days after operation.

Prophylaxis includes timely treatment of the upper airways, especially of the nasopharynx if the adenoids interfere with the normal function of the auditory tube.

TRAUMAS

Traumatic diseases of the middle ear are associated aetiologically with contusion, gun-shot wounds, and explosions. Fractures and infractions of the skull with injuries to the bony walls of the acoustic meatus, the mastoid process, the pyramid of the temporal bone, etc. are possible in such cases.

Traumatic affections promote propagation of infection and development of inflammation.

In addition to direct infection during injury, secondary infection can penetrate the middle ear through a ruptured tympanic membrane. Blood that has escaped into the tympanic cavity is a medium conducive to microbial growth. If the tympanic membrane remains intact, inflammation can develop due to penetration of infection through the auditory tube.

Contusive otitis media and mastoiditis. Contusive otitis develops due to a sudden and significant increase in the air pressure inside the external acoustic meatus (due to a blast and the like). The condensed air ruptures the tympanic membrane and otitis develops.

The patient with contusive otitis does not complain of pain in the ear because the exudate escapes freely into the external acoustic meatus through the perforated eardrum.

The degree of hearing loss varies. Deafness is caused mainly by contusion of the acoustic structures in the middle ear. The disease often converts into a chronic form.

Indications for operation should be based on the combination of all symptoms and the clinical course of the affection.

The postoperative period is usually long and is characterized by profuse mucous discharge from the operated cavity.

Otitis and mastoiditis associated with injury to the temporal bone. The aetiology of otitis and mastoiditis associated with wounds of the temporal bone depends substantially on the infection that penetrates together with the injuring object, and also on secondary infection. Favourable conditions for microbial growth in the cavities of the middle ear due to injury (haemorrhage, tissue destruction, decreased local reaction) are very important for the pathogenesis of inflammation.

Mastoiditis caused by gun-shot wound runs a long course. The discharge from the ear is meagre. The general symptoms can only be observed during the first days following the injury which concur with the commotio syndrome attending the injury. The hearing function is sharply impaired; the vestibular function is often inhibited or completely absent.

X-ray examination (to reveal the extent of the injury, possible infractions, fragments, etc.) is very important for the *diagnosis.*

Treatment is only surgical. It is aimed only at sanation of the injured temporal bone.

CHRONIC SUPPURATIVE DISEASES

Chronic suppurative otitis media is a common disease. In view of its high incidence and the danger to the hearing function and even to life, it deserves great attention on the part of practicing physicians and nurses.

Chronic suppurative otitis media is characterized by persistent perforation of the tympanic membrane, periodic or permanent otopyorrhoea, and hearing loss of various degrees (Plate XI).

Aetiology and pathogenesis. The disease is usually secondary to acute suppurative otitis which can persist during several months for various reasons. Among frequent causes of conversion of acute otitis media into the chronic form is a severe acute pathological process in the middle ear, which depends on virulence and the character of infection, decreased resistance of the body associated with chronic specific or non-specific infection, diseases of the blood, rickets, diabetes mellitus and some other diseases. Pathology of the upper airways is also important for the onset of the disease. Inefficient therapy of acute otitis media is among the provoking factors.

According to the clinical course and gravity, chronic suppurative otitis media is classified as mesotympanitis and epitympanitis.

Mesotympanitis occurs in 55 per cent of cases with chronic

suppurative otitis media. The mucosa of the middle and lower portions of the tympanic membrane, and also of the auditory tube are involved in this form of chronic inflammation of the middle ear. Inflammation of the tubal mucosa associated with pathology of the nasal cavity and the nasopharynx, upsets the function of the auditory tube which, in turn, becomes the permanent source of infection that affects the mucosa of the middle ear. The degree of pathological changes depends mainly on the activity of chronic inflammation, frequency of exacerbations, the specific properties of the patient's body, and some other reasons.

Otoscopy in mesotympanitis reveals intact flaccid part of the tympanic membrane and the presence of a perforation in the tense part. Perforation varies in location, shape and size. The presence of a permanent central perforation, not reaching the tympanic ring (anulus tympanicus) is characteristic. The perforation can be round, oblong, bean-shaped; it can vary in size from punctate to an opening occupying almost the whole area of the tense part, a narrow band remaining by the circumference.

Subjective *symptoms* are indistinct. Patients complain of periodical or constant otopyorrhoea and impaired hearing function. In rare cases the patients complain of tinnitus and vertigo. Pain in the ear arises only during exacerbation or due to development of secondary diseases of the ear, such as diffuse otitis externa or circumscribed otitis externa.

Discharge from the ear is mucopurulent; it can be sanguinopurulent in the presence of granulation and polyps. The discharge is usually odourless. It can be meagre or profuse (in exacerbation). The hearing function is impaired as in affection of the conduction system.

The course of mesotympanitis is usually uneventful. The discharge from the ear can persist for years without causing any serious complications. Otopyorrhoea can stop spontaneously and recur only during exacerbation caused by common cold, water in the ear, respiratory diseases, diseases of the nose, nasopharynx, paranasal sinuses, etc.

Despite the benign course of mesotympanitis, severe intracranial complications can sometimes occur. They can be caused by caries of the promontorial wall, polyps, and granulation.

Diagnosis is based on the anamnestic, clinical, and otoscopic findings (persistent central perforation). Mesotympanitis should be differentiated from epitympanitis. The distinguishing signs of mesotympanitis are persistent central perforation of the tense part

of the eardrum, mucous, mucopurulent, or (less frequently) purulent odourless discharge. The odour indicates involvement of the bone (malignization of the disease).

Prognosis is usually favourable, provided a systematic and rational general and local treatment is given. But it is difficult to improve the hearing function, and in this respect the physician should be careful in his prognosis. Hearing improves in most cases after cessation of otopyorrhoea.

Treatment includes prevention of pus retention in the middle and external ear and action on the microflora and the inflamed mucosa with disinfectants and astringent preparations. Local treatment includes daily irrigation of the ear with the following warm solutions: 3 per cent hydrogen peroxide, 3 per cent boric acid, furacin (1:5000) and antibiotics, after preliminary testing the microflora for sensitivity to them. In the presence of local signs of allergy (oedema of the mucosa of the tympanic cavity, watery discharge, etc.), a hydrocortisone suspension should be added to the antibiotic solution.

In the presence of perforation in the tympanic membrane, endaural administration of medicinal preparations is effective: 1.5-2 ml of medicinal solution is instilled in the external acoustic meatus and the tragus is then pressed rhythmically by the finger for 10-15 seconds to pump the liquid into the middle ear. If the patient feels the taste of the medicine in the mouth, it indicates that the solution has passed the middle ear and entered the auditory tube. A Siegle's speculum or a Politzer's bag can be used for the purpose. The medicine can be administered through a catheter and through the auditory tube.

Local treatment includes also direct instillation of the following solutions: 3 per cent boric alcohol, an alcohol solution of furacin (1:5000), antibiotic solutions, a 1 per cent zinc sulphate solution, a 1 per cent formaldehyde solution, a 2-3 per cent protein silver solution, a 0.5 per cent colloid silver, and other solutions. Antibiotics should be injected intramuscularly only during exacerbation.

Minor surgical operations are sometimes necessary: treatment of small granulations or polyps with trichloroacetic acid, a 40 per cent silver nitrate solution; cryosurgery; removal of large granulations using a conchotome, or a curet; and removal of polyps using an aural snare.

Physiotherapy is also necessary. It includes UV-therapy (through a cone) and UHF on the ear in the absence of polyps or gra-

nulation (with adequate withdrawal of pus). General envigorating measures are recommended: rational nutrition, hardening of the body, climatotherapy, and the like.

Epitympanitis (atticitis). The inflammation is mainly localized in the epitympanum, the attic of the tympanum. A perforation is usually present in the lateral wall of the epitympanum. Atticitis is characterized by affection of the mucosa and the bony tissue of the middle ear walls and the mastoid process. Caries or cholesteatoma can destroy the wall of the middle ear thus causing a severe intracranial or general complication.

The main otoscopic sign of the pathology is persistent marginal perforation in the upper (flaccid) portion of the tympanic membrane. Perforation is called marginal if bone is a part of the perforation margin.

Inward propagation of caries involves large portions of the temporal bone, the labyrinth capsule included. If the process is destructive, pus has a putrid odour specific for epitympanitis.

A curved end of the probe is passed into the attic through the perforation and the surface of the bony wall is examined. Rough surface indicates caries. A sample of cholesteatoma or pus can be extracted from the attic on the tip of the probe. Probing detects the presence of granulation (and determines its location) and can also reveal the presence of labyrinthine fistula.

Cholesteatomatous epitympanitis. Cholesteatoma causes vast destruction in the temporal bone. Cholesteatomatous masses can sometimes be seen during otoscopy through a perforation in the tympanic membrane. These appear like a white tumour (with a pearly lustre) consisting of stratified keratinized epithelium filled with pus, debris, and bacteria. A common cholesteatoma of the ear (secondary cholesteatoma) arises due to extension of the epidermis from the acoustic meatus through the perforation into the middle ear. This epidermis is tightly attached to the bone and is an envelope (matrix) for the cholesteatoma. This should not be mistaken for a true cholesteatoma which occurs in rare cases, when it develops from the embryonal precursors. Cholesteatoma increases in size gradually and constantly due to desquamation of the epidermis, fills in the attic and the antrum and then destroys the bone. As a result the cholesteatoma can reach the meninges, destroy the bony capsule of the labyrinth, the wall of the canal for the facial nerve, almost the entire mastoid process, and thus expose the cerebellar meninges and the wall of the sigmoid

sinus. Purulation of cholesteatomatous mass can extend to the intracranial tissues to cause intracranial pathology.

The hearing function often decreases only slightly. If the neurotic component joins, hearing can be impaired significantly at later stages of the process.

X-ray examination of the temporal bone (Schüller, Mayer, Chassè position) is a valuable *diagnostic* method. The X-ray picture of the attico-antral region reveals a distinct defect of the bone in the form of structureless clear cavity surrounded by a thin opacity (the wall of the cavity). The X-ray picture of a caries-affected bone reveals indistinct margins of the defect.

Treatment of chronic suppurative epitympanitis is more difficult than of chronic suppurative mesotympanitis. Conservative treatment is effective in cases with anterior epitympanitis. Conservative treatment is usually ineffective in cases with the medial and posterior location of the marginal perforation in the superior parts of the tympanic membrane. A surgical intervention is necessary in such cases. If chronic inflammation is confined to the attic, atticotomy is performed. Attico-antrotomy is necessary if the process extends to the antrum. Both operations are sparing; the hearing function is preserved. If caries extends to the cavities of the middle ear, and the diagnosis is confirmed otoscopically, roentgenographically, and by other instrumental examinations, a radical surgery is necessary. After eliminating the focus of inflammation, all cavities of the middle ear are united into one cavity. This is the radical operation on the ear (Fig. 68).

Cholesteatoma in the attico-antral region is an obligatory indication for the radical operation. The presence of signs of intracranial complications (sinus thrombosis, meningitis, cerebral abscess and abscess of the cerebellum) is the absolute (vital) indication for a radical operation on the ear in suppurative otitis media. The operation should be performed immediately. Surgical intervention is also required in the presence of sings of mastoiditis, paresis of the facial nerve, and labyrinthitis.

In the other cases the extent of operative intervention should be determined with consideration of the auditory and vestibular functions of the ear.

Chronic suppurative otitis media in children differs in some respects from this disease in adults. The differences are associated with the anatomy of the temporal bone in children and the specific reaction of a child's body to various stimuli. Special attention

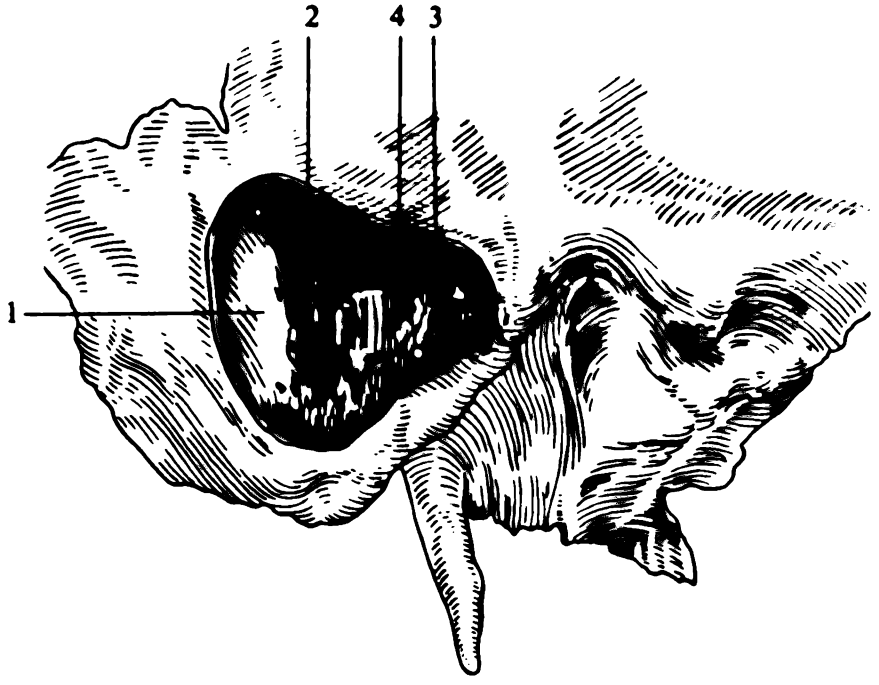

Figure 68
Radical operation with opening of all middle ear cavities:

1-sigmoid sinus; *3*-facial nerve canal;
2-antrum; *4*-lateral semicircular canal

should be paid to children under 3 years of age, in whom the conversion of acute inflammation into the chronic form is associated with malnutrition (hypotrophy) and exudative diathesis due to hypersensitivity to various stimuli. Immunity is weak at this age.

Chronic suppurative otitis media in children has two forms: mesotympanitis and the necrotic form. The latter is usually secondary to exudative diathesis. If a cholesteatoma develops in the middle ear, it progresses rapidly to destroy the mastoid process and penetrate into its soft tissues through the cortical layer.

Treatment. In addition to anti-inflammatory treatment of otitis media, correct nutrition is also important. Vitamins A, B, C, D and PP should be given in sufficient quantity. Surgical procedures on the temporal bone of a child must be very sparing and preserving the hearing function.

TYMPANOPLASTY

Tympanoplasty is the surgical reconstruction and building of new sound conduction apparatus. This operation is aimed at improving the impaired hearing function by the following methods: (1) improvement of transformation of sound conduction; (2) protection (shielding) of the labyrinthine windows, usually the round window, from sound pressure; (3) combination of these methods.

Transformation should be improved in (a) dry perforation of the tympanic membrane; (b) disruption of the ossicular chain; (c) dry adhesive process in the tympanic cavity.

Tympanoplasty, aimed at restoring hearing, is only indicated for patients in whom the operation can be expected to result in considerable improvement of the hearing function. This effect can only be attained on the condition that there is a functional reserve in the cochlea (determined by the difference between the air and bone conduction curves on the audiogram). The difference is almost completely eliminated by a successful operation.

Contraindications for tympanoplasty are the following: (a) exacerbation of chronic otitis and especially the presence of labyrinthine, intracranial or septicopyemic complications; (b) considerable affection of the sound perception apparatus; (c) obstruction of the auditory tube.

DISEASES OF THE INTERNAL EAR

LABYRINTHITIS

Labyrinthitis is an acute or chronic inflammation of the internal ear, which can be either circumscribed or diffuse, and attended by affections of the vestibular and auditory apparatus of various degrees.

Due to the specific anatomy and topography of the internal ear, its inflammation is always secondary to another inflammatory process. The following forms of labyrinthitis are therefore differentiated according to their aetiology: tympanogenic, meningogenic, haematogenic, and traumatic.

The clinical picture of labyrinthitis is characterized by upset function of the vestibular and auditory receptors of the internal ear.

Treatment is usually complex. Acute diffuse labyrinthitis (serous or suppurative), which develops without previous chronic

carious otitis media, should be treated conservatively by antibacterial and dehydration means, by normalizing local trophic disorders in the labyrinth, reducing pathological pulsation from the ear, and improving the general condition of the patient. Broad-spectrum antibiotics (except ototoxic) should be used.

Acute diffuse labyrinthitis concurrent with chronic carious otitis media should be treated conservatively for 6-8 days during which a granulation ridge is formed in the region of the fistula from the middle ear to the labyrinth, and the delivery of toxins into the internal ear is thus discontinued. As an acute attack is abated, a radical sanative operation should be performed on the middle ear. The conservative treatment should be continued during the postoperative period.

Sometimes the sanative operation on the middle ear can be performed immediately, with simultaneous anti-inflammatory or other conservative treatment. If the attack is not arrested during the first 4-5 days, the operation should not be postponed any longer.

In circumscribed labyrinthitis, the pathological process in the labyrinthine or mastoid wall of the tympanic cavity should be eliminated surgically. All pathologically changed tissues should be removed from the middle ear during operation; the walls of the lateral semicircular canal, the facial nerve, and, if necessary, the entire medial wall of the middle ear should be examined under the operational microscope.

In the presence of intracranial complications associated with labyrinthitis, surgical operation should be performed immediately to sanate the focus.

VESTIBULOCOCHLEAR (COCHLEAR) NEURITIS

Neuritis of the vestibulocochlear (auditory) nerve is a collective term implying affection of any part of the auditory apparatus, beginning with the neuroepithelial cells of the spiral organ (the organ of Corti) to the transverse temporal (Heschl's) gyri.

The aetiology of affection of the auditory apparatus is quite varied. But the most common causes of the disease are infectious diseases such as influenza, measles, scarlet fever, typhus or malaria, medicamentous or industrial poisoning, and injuries (mechanical, acoustic, vibrational, barotrauma). Less frequently inflammation of the vestibulocochlear nerve arises in cardiovascular pathology, in some metabolic disorders and systemic diseases. Degenerative changes in the cells of the organ of hearing prevail in toxic

neuritis caused by medicamentous poisoning (streptomycin, monomycin, kanamycin).

Symptoms. Vestibulocochlear neuritis is characterized by two main symptoms: permanent noise of varied pitch in the ears due to inflammatory and degenerative process and vascular disorders, and impaired hearing which is characterized by inadequate perception of high-pitch sounds and shortened bone conduction. Less frequently the patients complain of permanent or transient buzzing (ringing) noise in the ears (tinnitus). If neuritis further progresses, impaired hearing can turn into complete deafness.

Complete deafness is a total loss of auditory sensitivity. A rapidly progressing hearing loss is often attended by symptoms of irritation of the vestibular apparatus; these are, first of all, vomiting, vertigo, and absence of the sense of balance. A spontaneous nystagmus can develop.

Diagnosis. A thoroughly collected anamnesis and also clinical findings are important for diagnosis of vestibulocochlear neuritis. Tuning-fork and audiometric tests are of leading importance in topical diagnosis.

Hearing disorders associated with neuritis should be differentiated from perceptive disorders due to brain tumour, haemorrhage into the internal ear, and some other affections. The main differentiating sign of vestibulocochlear neuritis is bilateral deafness or amblyacousia.

Treatment of infectious neuritis should be aimed at elimination and neutralization of causes of the disease. Therapeutic measures should therefore be immediately taken.

The therapy of infectious neuritis includes mainly measures aimed at elimination of inflammation and eradication of the routes of infection ingress. The following antibiotics should be administered: penicillin, 300 000 U 4 times a day or 500 000 U 3 times a day; oletetrin in tablets, 250 000 U 3 times a day; nystatin, 250 000 U 3 times a day. Indicated also is stimulation therapy: aloe, 1 ml a day, 25-30 injections and subcutaneous injections of a corpus vitreum preparation, 2 ml, 20 injections for a course. Vitamins C and B are necessary to treat vestibulocochlear neuritis of any aetiology. Intravenous injections of a 40 per cent glucose solution (20 ml, for 15-20 days) are also effective. Infectious neuritis should also be treated by physical methods. Most effective of them are electrophoresis of a 5 per cent potassium iodide solution on the mastoid process (15 sessions) and d'Arsonvale current.

Ringing and buzzing noise (tinnitus) in the ear can be decreased by intracutaneous novocain block (1 per cent novocain solution is injected intracutaneously into the external acoustic meatus in a dose of 0.5 ml, 1–1.5 cm from the entrance to the meatus). The course includes 12 injections.

Treatment of toxic neuritis first of all includes prevention of further ingress of toxins into the body and their immediate withdrawal from the body. Diuretics and sudorifics should be given. In cases with acute streptomycin intoxication unithiol should immediately be administered in combination with vitamins B_1, B_6 and B_{12}. Unithiol should be injected intramuscularly or subcutaneously, 1 ml of a 5 per cent solution per 10 kg body weight of the patient. During the first day unithiol is administered 3-4 times; during the second day, 2-3 times; and during the next seven days, 1-2 times a day.

Rp.: Sol. Unithioli 5%, 5.0
D. t. d. N. 10 in amp.
S. Subcutaneous injections of 5 ml 3-4 times a day

Good effect is attained with cocarboxylase, 50 mg daily, during 30 days, in combination with apilac (a tablet for sublingual intake contains 0.01 g of the preparation; the tablets should be taken 3 times a day after meals, for 30 days). The metabolic processes in the nerve tissue can be improved by intramuscular injections of ATP (adenosinetriphosphoric acid) in a dose of 1-2 ml of a 1 per cent solution for a month. In affections of the peripheral and central nervous system metabolism can be stimulated by pyrogenal.

In some patients acupuncture is an effective means to reduce (or remove) noise in the ear.

MÉNIÈRE'S DISEASE

This is a non-suppurative disease of the inner ear characterized by the classical triad: (1) attacks of systemic labyrinthine vertigo attended with nausea and vomiting; (2) unilateral hearing loss; (3) noise in the involved ear. The disease was first described by Prosper Ménière, a French physician, in 1861.

Attacks of vertigo occur amid complete health and are attended by nausea and sometimes vomiting. As a rule, noise in the affected ear intensifies during an attack. The patient feels as if his ear is stuffed or he is deafened. The objective sign

of an attack is spontaneous nystagmus which disappears soon after the attack is abated. The patient loses his sense of balance during attacks and tries to assume a horizontal position, often with his eyes closed. Any attempt to change the position impairs the patient's condition and intensifies nausea and vomiting. Attacks can occur at any time of the day, but mostly at night time or in the morning. A physical or psychic overstrain can be the provoking factors. Some patients feel the approaching attack a few hours or even days before the actual onset of the disease. Noise in the ear or slight loss of balance are precursors of the forthcoming attack.

Fluctuation of hearing is a leading diagnostic sign of the auditory disorder: the hearing can improve considerably between attacks against the background of a gradually progressing deafness. During the initial stage of the disease, the hearing function can be restored completely thus indicating the absence of organic changes in the vestibulocochlear nerve during this period.

Ménière's disease occurs mostly in the young. Its onset is characterized by the noise in the ear which is followed (in a few hours or years) by attacks of systemic vertigo and vegetative disorders. An important point is that the auditory, rather than vestibular, disorders are typical for the onset of the disease. When establishing a diagnosis, it is necessary to take into account the periodicity of attacks, their short duration, good subjective condition of the patient during remission, etc.

The disease should first of all be differentiated from the vascular and vestibular syndrome, arachnoiditis, and tumour of the cerebellopontine angle.

Treatment. The polyaetiological origin of the disease accounts for the multitude of methods of treating it.

Methods causing reconstruction of the vegetative nervous system are widely used. These are as follows:

(1) reflex action of novocain block (intranasal block, the block of the stellate ganglion and the cervical sympathetic trunk);

(2) vitamin B, PP, A, and E therapy;

(3) oxygen therapy and habituation (training with controlled increasing strength of rotation);

(4) exposure of the diencephalon (the centre of the vegetative nervous system) and the sympathetic cervical ganglia to X-rays.

Surgical methods of treatment have been widely used in the recent decade.

An acute attack of vertigo is eliminated by subcutaneous injection of 1 ml of a 0.1 per cent atropine sulphate solution, intravenous administration of 10 ml of novocain solution and 10 ml of a 40 per cent glucose solution. If this measure is not sufficient, 1-2 ml of a 2.5 per cent aminazine solution should be injected intramuscularly. If the attack fails to be removed completely, administration of atropine, aminazine and novocain should be repeated in 3-4 hours. If vertigo is severe and the mentioned means prove insufficiently effective, 1 ml of a 1 per cent pantopon solution can be administered subcutaneously.

The presence of arterial hypotension rules out the use of aminazine. The following should be administered instead:

Rp.: Atropini sulfas 0.00025
Coffeini puri 0.02
Luminali 0.2
Natrii hydrocarbonas 0.25
M. f. pulv. D. t. d. N. 30
S. to be taken three times a day

Antihistaminics (promethazine hydrochloride), chloropyramine, and diphenhydramine hydrochloride are effective both during and after the attack. One of these preparations is administered in a common dose subcutaneously.

The following mixture should be given during 10 days following the attack:

Rp.: Atropini sulfas 0.003
Papaverini hydrochloridum 0.2
Aq. destill. 20.0
S. 15 drops two times a day after meals

It is recommended to carry out a course of intravenous injections of a 5 per cent sodium bicarbonate solution, 50 ml a day, for 15-30 days. Positive effect is attained with dehydration: salt intake should be restricted to 0.5 g a day; ammonium chloride should be taken in 3-day courses (3 g, 3 times a day), 2 or 3 courses at 3-4-day intervals.

Patients with Ménière's disease should abstain from work with moving mechanisms or in conditions of vibration and noise exceeding 70 dB. Work at high altitudes is also prohibited.

OTOSCLEROSIS

Otosclerosis is a frequent cause of deafness (it occurs in more than 0.5 per cent of cases). The morphological substrate of otosclerosis is a circumscribed osteodystrophic process manifested

by small single foci of newgrowths in the bony walls of the right and left labyrinths. These foci are relatively symmetric in the bony capsules of the internal ear. They grow to replace gradually the wall of the labyrinthine capsule by a spongioid or dense bone with a different structure. In most cases the otosclerotic focus is localized anteriorly to the oval window; as it grows, the focus extends to the stapedovestibular junction, the anterior limb of the stapes, which impairs mobility of the stapes thus affecting the hearing function and causing noise in the ear. Hearing is first impaired in one ear; then, following months or years, the other ear is involved. This form of otosclerosis is called clinical. If otosclerotic foci are localized outside the windows of the labyrinth, the form is called histological; it can only be detected during histological examination of pathological material. Otosclerosis is usually associated with dystrophic changes in all tissues of the temporal bones.

Otosclerosis occurs mostly in women (in 80-85 per cent of cases). In 70 per cent of cases the disease begins at the age from 20 to 40. Otosclerosis is a hereditary disorder. Various intrinsic and environmental factors can also be important for the onset and the course of the disease.

The main audiological sign of otosclerosis is considerably increasing thresholds of air conduction in both ears. Bone conduction thresholds usually increase to a considerably smaller extent.

The Willis paracousis symptom is pathognomonic for otosclerosis: the patient hears much better in noisy surroundings (e.g. in traffic, or airplane). This phenomenon can presumably be explained by mobilization of the stapes with strong low-frequency vibrations and jolting, on the condition that the stapes is only moderately fixed in the oval window. Ultrasound testing (98 000 Hz) of the hearing function is important for differential diagnosis of otosclerosis and cochlear neuritis. In otosclerosis ultrasound is perceived at the same intensity as in health, or the intensity can be increased only slightly, while in cochlear neuritis the sound intensity should be increased two or three times compared with the norm.

Treatment of otosclerosis is surgical. It is actually symptomatic because it does not eliminate the pathogenic factors of the disease and only removes to a lesser or greater extent the symptom – deafness and tinnitus. The operation is aimed at reconstruction of the sound transmission system, from the ossicles

Figure 69
Stapedoplasty:

1 – edge of the oval window after complete removal of the stapes;
2 – venous transplant placed around the prosthesis to imitate the annular ligament of the stapes;
3 – distal end of the prosthesis is at the level of the oval window

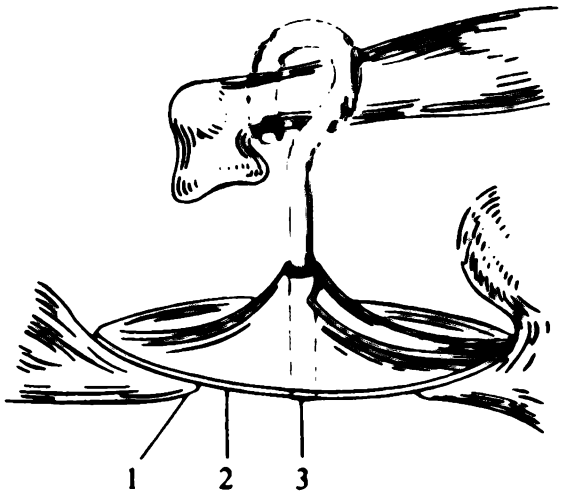

to the perilymph. The mobility of the base of the stapes in the oval window is impaired due to the growth of the otosclerotic focus into the annular ligament and the base of the stapes (usually at its anterior pole).

The following operations aimed at improving the hearing function are now widely used: stapedoplasty with partial or complete stapedectomy, and stapedoplasty by a piston method (Fig. 69).

At a late-term postoperative period 80 per cent of the operated patients preserve socially adequate hearing, which is an evidence of the high efficacy of surgical treatment of otosclerosis. But operations on the oval window are fraught with great danger to the function of the internal ear, both in the early and late postoperative periods. The operation is therefore performed usually on one ear only. If the hearing function of the operated ear is completely lost, the non-operated ear can be assisted by a hearing aid.

OTOGENIC INTRACRANIAL COMPLICATIONS

Otogenic intracranial complications arise due to extension of the pathological process from the external ear, middle and internal ear into the cranium. The complications include epidural (extradural) and subdural abscesses, sinus thrombosis, intracranial abscesses (temporoparietal and cerebellar), meningitis, and arachnoiditis.

Streptococcus and staphylococcus are the main causative agents in the aetiology of otogenic intracranial complications. Sometimes

inflammatory intracranial processes occur in acute influenzal otitis media.

Infection spreads from the middle and internal ear into the cranial cavity by (1) contact extension (the most common route); (2) by the vascular route; and (3) by preformed routes. The specific character of these routes explains the possibility of concomitant intracranial complications and inflammation foci on the side opposite to that of primary inflammation.

The infection most frequently spreads from the middle ear to the cranial cavity by the contact route, through the upper walls of the tympanic cavity and the antrum of the mastoid process, which form the floor of the median cranial fossa. The upper wall of the middle ear of neonates has a fissure which closes with age. Infection can also spread through the anterior wall of the middle ear and the medial wall of the auditory tube and extend onto the carotid artery which passes in the vicinity.

The inflammation usually extends from the middle ear onto the meninges, the venous sinuses and the medulla not through healthy bone tissues, but through carious bones. The major part of the labyrinth is adjacent to the tympanic cavity and the inflammation can thus spread from the middle ear to the labyrinth and the canal of the facial nerve, and further, through the internal acoustic meatus, to the posterior cranial fossa.

The bloodborne infection is important for the onset of intracranial complications in acute otitis media. The suppuration focus is as a rule located far away from the primary focus.

Spreading of infection by preformed routes stands the third in the list of incidence. Infection spreads by the bone canals for blood and lymphatic vessels, perivascular space of the internal acoustic meatus, the aqueduct of the cochlea and the aqueduct of the vestibule.

Otogenic meningitis is the most frequent complication of acute and chronic otitis media. All cases of otogenic meningitis can be classified as primary (due to infection spreading from the middle ear by various routes) and secondary (due to other intracranial complications, sinus thrombosis, subdural or cerebral abscesses). All otogenic meningites should be considered as suppurative and should be differentiated from irritation of the meninges in other intracranial complications, such as thrombosis of the cerebral sinuses and brain abscess.

Symptoms. General symptoms of infectious disease, meningeal

signs and sometimes focal symptoms can be differentiated in the clinical picture. The general symptoms are elevated body temperature, changes in the internal organs (cardiovascular, respiratory, and alimentary systems) and impairment of the general condition.

The onset of the disease is usually characterized by elevation of body temperature to 38-40 C. Since meningitis develops during exacerbation of chronic or acute suppurative otitis, pyrexia is usually observed against the background of subfebrile temperature or appears as a repeated elevation of temperature.

The body temperature can be subfebrile or even normal during the early stage of meningitis. This atypical picture occurs in patients with altered immunological activity: in the aged and cachectic patients, in patients with diabetes mellitus, and in pregnant women.

It should be remembered that the gravity of the patient's condition does not always agree with the changes in the cerebrospinal fluid. The condition can be grave with relatively low cytosis (250-800).

Among the meningeal symptoms are headache, vomiting, and disordered consciousness.

Headache is attended with nausea in 90 per cent of cases and vomiting occurs in not less than 30 per cent of cases. The meningeal symptoms such as rigidity of the occipital muscles, Kernig's sign, Brudzinski's sign (upper and lower), Bekhterev's sign (pain inside the head or blepharospasm associated with striking on the zygomatic arch with a hammer), hypertension, and photophobia can be vivid on the very first days of the disease, and become even more pronounced in 2 or 3 days. All these symptoms can vary in strength and combination. For example, rigidity of the neck can occur in the absence of Kernig's sign, one symptom can be present in the absence of other signs. It should be noted that the vividness of the meningeal signs does not always correspond to the severity of meningitis and to the changes in the cerebrospinal fluid. In this connection, even a slightest suspicion of meningitis in the presence of even insignificant meningeal signs is an indication for a lumbar puncture. Confusional condition is characteristic for the very onset of the disease: flaccidity and inhibited mental function (with preserved orientation in time, place, and other realities). Consciousness then becomes dimmed. Psychomotor excitation can arise which then changes to mental distress and sleepiness.

The blood changes are in all cases characterized by neutrophilic leucocytosis. Leucocyte counts are as high as 33-34 $\times 10^9$ (usually 10-15 $\times 10^9$) per litre with shifts to the left. Single juvenile forms (myelocytes, 1-2 per cent) sometimes appear. Rod (nucleated) cells are from 5 to 30 per cent and the segmented cells are 70-73 per cent. ESR increases from 30-40 to 60 mm per hour. High leucocyte counts sometimes disagree with only a slight acceleration of ESR.

In some cases of otogenic meningitis the fundus oculi is not changed.

The cerebrospinal fluid pressure is always high: from 300 to 600 mm of the fluid (normal 150-200 mm). The colour of the cerebrospinal fluid changes from slight opalescence to milky or cloudy greenish-yellow purulent. Cell count varies from 250 to 30 000. Neutrophils prevail in all cases (80-90 per cent). The amount of protein increases from 0.66 to 6.6 g/l and in some cases to 9.6 g/l, but the increase does not always agree with pleocytosis.

Acute, fulminant, relapsing, abortive and atypical forms are distinguished in the course of otogenic meningitis. Acute meningitis usually develops in the presence of acute or exacerbated chronic otitis media. If treatment is begun in due time, the patient's condition improves in 2-3 days; consciousness is regained, and the cerebral symptoms either disappear or lessen.

Treatment. Use of sulpha drugs and later of antibiotics has considerably reduced mortality from this disease except in cases of its fulminant course.

Treatment of otogenic meningitis includes (1) aetiological; (2) pathogenetic; and (3) symptomatic measures.

Aetiological treatment implies antimicrobial therapy and sanation of the focus. Elimination of the infectious focus is an obligatory first measure, irrespective of the gravity of the patient's condition or the extent of changes in the ear. A severe condition is not a contraindication for operation because the purulent focus remains a constant supplier of pathogenic microbes to the subarachnoid space and is thus a source of toxaemia.

Antibacterial therapy begins simultaneously with sanative operation. There are many schemes for treatment of otogenic meningitis with antibiotics (with respect to their combinations, doses, and routes of administration). Permeability of the blood-brain barrier increases 5-6 times in acute meningitis.

Bacteriostatic concentration of penicillin is 0.2 U/ml and the

daily dose is 12 000 000 U. Practically, to 30 000 000 U a day are administered to patients.

Penicillin should be administered at 4-hour intervals (by equal portions). The route of administration depends on the patient's condition. Penicillin is more often injected intramuscularly. Intracarotid or intravenous administration of penicillin is used in especially severe cases. The optimum dose for intracarotid administration is from 600 to 1000 U/kg. The daily dose should be administered in 2-3 injections. The penicillin sodium salt can be administered into the subdural space, but frequent endolumbar punctures can cause productive and proliferative changes in it, and are therefore used only in severe and neglected cases or in the fulminant course of the disease. From 10 000 to 30 000 U of penicillin sodium salt are diluted in the cerebrospinal fluid or isotonic sodium chloride solution for endolumbar injections. The potassium salt of penicillin must not be used for endolumbar injections. In massive penicillin therapy it is necessary to administer nystatin (2-3 mln U/day) to decrease the danger of possible mycosis and dysbacteriosis; vitamin therapy is also necessary.

Aetiological treatment should concur with pathogenetic therapy (dehydration, detoxication, decreasing the permeability of the blood-brain barrier). The intensity and continuation of this therapy depend on the condition of the patient. Mannitol (30-60 g/day in 300 ml of isotonic sodium chloride solution) should be injected as a dehydrating measure. Frusemide (2-4 ml/day) should be injected intravenously, 10 ml of a 25 per cent of magnesium sulphate solution intramuscularly, and 7 ml of glycerol per os are prescribed for the same purpose.

Depending on the general condition and the state of the cardiovascular system, the patient can be given symptomatic treatment (cardiac glycosides, tonics, analeptics).

Timely treatment of patients with microbial forms of otogenic meningitis leads to recovery in most cases.

Extradural (epidural) abscess is accumulation of pus between the dura and the cranial bone. It occurs due to extension of inflammation from the mastoid process and the middle ear to the cranial cavity and is localized either in the posterior cranial fossa (the sigmoid groove, Trautmann's triangle) or in the middle cranial fossa. Extradural abscess is a complication of acute otitis media and of exacerbated chronic suppurative otitis. It often concurs with cholesteatoma, pus in the tympanic cavity, destruction

of the roof of the tympanic cavity, and suppurative labyrinthitis (if the process is localized in the posterior cranial fossa).

Circumscribed pachymeningitis resembles extradural abscess with respect to its physiological, topographic, morphological and clinical characteristics. Pachymeningitis is actually the initial phase of the abscess.

Symptoms are only few and the diagnosis is often established only during operation. The general symptoms are not pronounced.

The main symptom of all intracranial complications is headache. Headache is usually constant in extradural abscess but it is not severe. In perisinuous abscess, pain occurs in the frontal and occipital parts of the head. If the abscess is localized in the middle cranial fossa, pain is felt in the squamous part of the temporal bone, behind the ears, and in the region of the tragus. Headache is sometimes attended with nausea, vomiting, and sleepiness. The general condition can be satisfactory or severe. The meningeal symptoms are sometimes observed.

Treatment is only surgical. Local headache, impairment of the general condition, focal symptoms, and the presence of a purulent process in the ear are indications for the operation.

Subdural abscess is a rare intracranial complication. It occurs as a complication of chronic suppurative otitis media, especially cholesteatoma, and less frequently, of acute otitis media. The abscess is localized in the middle or posterior cranial fossa. Abscess in the posterior cranial fossa usually develops in suppurative labyrinthitis or thrombosis of the sigmoid sinus.

Cerebral abscess. The clinical picture of otogenic cerebral abscess includes three groups of symptoms: general signs of infection, general cerebral symptoms, and signs of local affection of the brain depending on the site of abscess. The course of brain abscess is divided into four stages: initial, latent, apparent, and terminal.

Symptoms differ depending on the stage of the disease. It is very important to assess correctly the general cerebral symptoms such as impairment of the general condition, high temperature, bradycardia, and blood changes.

The initial stage, which lasts 1-2 weeks, is marked by a slight headache, elevated temperature (to 37.5°C), nausea, vomiting, and indisposition. This condition often coincides with that of the postoperative period (after a sanative operation on the temporal bone) and is therefore often overlooked. The symptoms of the latent period are few. Flaccidity, paleness, absence of appetite, and regular

headaches are possible. The body temperature can be normal and there may be no changes in the blood. Then the apparent stage comes, which sometimes is quite unexpected because of the seemingly satisfactory general condition. The process tends to deteriorate, although the course can be undulant with periods of improvement and impairment. The general condition of the patient during this stage is usually grave. The patient is flaccid, sleepy and indifferent, the skin is pallid (sometimes with grey or yellow hue), the face expresses suffering. Appetite is usually poor, the tongue is dry and coated with a brown fur; constipation is characteristic.

The body temperature depends on the concurrent suppurative otitis and the presence of other intracranial complications. It is believed that a non-complicated brain abscess is characterized by normal or subfebrile temperature. Bradycardia is frequent.

The erythrocyte count and haemoglobin content do not usually change in brain abscess. But moderate hypochromic anaemia with haemoglobin reduced to 600 g/l and erythrocyte count decreased to 3-3.5 $\times 10^{12}$/l, with signs of hypochromia and poikilocytosis can be seen in patients with non-complicated brain abscess. Various quantitative and less frequently qualitative changes are possible in the differential blood count. Neutrophilic leucocytosis (from 10×10^9 to 18×10^9/l occurs most frequently.

General cerebral symptoms. Headache is a frequent symptom. It can be attended by nausea and vomiting. Vomiting is usually associated with diffuse headache and is an evidence of intracranial hypertension.

Meningeal symptoms depend on the localization of the abscess, its closeness to the meninges and the ventricles of the brain, and the presence of perifocal oedema of the brain medulla and the meninges. The meningeal symptoms are indications for a lumbar puncture.

The pressure of the cerebrospinal fluid in brain abscess is usually high, but it does not usually exceed 300-350 mm of the fluid.

The cerebrospinal fluid in a non-complicated brain abscess is clear and sometimes opalescing; in complicated abscess it is turbid, and if the abscess opens into the subarachnoid space, the fluid contains pus. The cerebrospinal fluid is almost always sterile, even in cases with significant pleocytosis. This is explained by the antecedent use of antibiotics.

The main local symptom of the abscess of the left temporal lobe in right-handed persons is aphasia. In the presence of

amnestic aphasia, the patient fails to name an object but can repeat speech. Spontaneous speech is monosyllabic and poor; verbs prevail and nouns are almost completely absent from speech.

Hemianopsia (*hemianopia*) is a very important symptom of the abscess in the temporal lobe. It indicates involvement of the optic tract which passes through the temporal and occipital lobes. Only a quadrant (not the entire half) of the field of vision is lost. Upper and lower hemianopsia thus develop. The epileptiform syndrome is a focal sign in affections of the temporal lobe.

Focal symptoms of cerebellar abscess. Abscesses of the cerebellum occur much less frequently than those of the temporal lobe. Their incidences relate as 1:4 and 1:5. The symptoms of cerebellar abscess are quite pronounced but they are much milder and less persistent compared with those of tumours of the same location. Vertigo, for example, is a very valuable diagnostic sign for tumour of the cerebellum, but its value for the diagnosis of otogenic abscesses is considerably lower because this can also be the sign of labyrinthitis.

The most important focal symptoms are muscular hypotonia on the involved side, upset coordination, and spontaneous nystagmus.

Upset coordination of the limbs is always obvious on the involved side. This can be manifested by failure to perform finger-nose and heel-knee tests, and adiadochokinesia.

Among ophthalmological signs are changes in the visual acuity, optic neuritis, papilloedema, and changes in the field of vision.

Additional methods of examination: echoencephalography, electroencephalography, lumbar puncture, angiography, pneumo- and ventriculography, and scanning are used in cases where the necessity arises, as indicated by the clinical picture.

Treatment is surgical. It includes vast radical operation on the ear, finding the abscess and its opening. In addition to a common surgical intervention, a vast radical operation includes exposure of the dura and the middle and posterior cranial fossae. Depending on the findings of examination, the temporal lobe of the brain, the sigmoid sinus or the cerebellum are punctured.

In cases when the abscess of the brain or cerebellum has been revealed and drained, the prognosis markedly improves. The overwhelming majority of patients recover, but if encephalitis develops around the purulent focus, prognosis is worsened. In addition to the surgical treatment, active antibacterial and anti-inflammatory therapy is also required.

Arachnoiditis of the posterior cranial fossa often complicates chronic suppurative otitis. Arachnoiditis of this location is explained by the special anatomical features which promote infection spreading from the internal ear to the posterior cranial fossa. Otogenic arachnoiditis can be cystic (with a course like that of a tumour or abscess) and fibroplastic.

The onset of arachnoiditis coincides with exacerbation of otitis; the patient's condition is later worsened by intercurrent infections or exacerbated otitis if no sanative operation is performed.

The *clinical picture* is characterized by headache, vertigo (often systemic), forced position of the head, vomiting, and focal symptoms of affection of the cerebellopontine angle. The main symptoms are nystagmus (which develops during the attack), vertigo, and Romberg's sign (uncertain standing and walking). Coordinated movements of the limbs are almost never upset. Slight dysfunction of the trigeminal nerve manifests itself by hypoaesthesia on the face and a weak corneal reflex. Elevated cerebrospinal fluid pressure causes changes in the fundus oculi. The optic papillae are swollen to a various degree during various stages of the disease and in some cases cause secondary atrophy of the optic nerves. The visual acuity is almost always normal. The composition of the cerebrospinal fluid is often characterized by a slight protein-cell dissociation (0.66 g/l); less frequently the composition is hydrocephalic, with decreased protein content (to 0.26-0.099 g/l).

The diagnosis is established according to the patient's complaints (headache, vertigo, weakness) and objective findings.

Treatment is surgical and antibacterial. A vast radical operation on the ear is required; courses of antibiotic therapy are periodically repeated depending on the degree to which the symptoms are pronounced. In the presence of a vast cystic process in the posterior cranial fossa, a neurosurgical intervention is required.

Sinus thrombosis and sepsis. As a rule, sinus thrombosis is caused by otitis media, with extension of inflammation to the mastoid process. Caries of the petrous part of the temporal bone, cholesteatoma, and other inflammatory diseases of the bones of the skull can cause sinus thrombosis.

Injuries to the face or soft tissues of the skull, erysipelas, or furuncle of the same location can sometimes cause thrombosis of the cavernous sinus.

Thrombosis of the bulb of the jugular vein is usually secondary to thrombosis of the sinus, but it can also be a primary affection due to infection spreading from the tympanic cavity.

Local symptoms are especially distinct in infected thrombosis. This condition is marked by hyperaemia and oedema of the soft tissues overlying the mastoid process, pain in this region and tenderness to palpation, dilatation of the superficial veins at the posterior edge of the mastoid process. Changes in the cervical vascular bundle occur in some patients. These changes account for the tenderness of the jugular vein to palpation. At later terms, the vein is palpated as a strained string. The lymph nodes along the course of the vascular bundle become enlarged when the thrombosis extends to the bulb or the jugular vein or the vein itself. Since the time of introduction of sulpha drugs and antibiotics into medical practice, tenderness of the mastoid process occurs only in rare cases and is not therefore an obligatory symptom.

Body temperature is elevated in more than 50 per cent of cases. A feverless course of the disease is explained by the use of antibiotics and the specific properties of the macroorganism, such as a low general reactivity of the body, e.g. in diabetes mellitus. The presence or absence of fever does not therefore characterize the disease severity.

Elevated body temperature can be attended with a chill and tachycardia, which indicate the onset of sepsis. In very rare cases sinus thrombosis is associated with slow pulse, which is a symptom for differential diagnosis to exclude brain abscess. General cerebral symptoms such as headache, nausea, and vomiting are due to high intracranial pressure caused by obstruction of the cerebrospinal fluid outflow. Intracranial hypertension accounts for the congestive changes in the fundus oculi, which are usually not pronounced.

X-ray pictures of the temporal bone show considerable destructive changes in the mastoid process, destruction of the cells, and often cholesteatoma which is present in at least 50 per cent of patients. Neutrophilic leucocytosis is frequent; the ESR is always high.

Lumbar puncture reveals elevated cerebrospinal fluid pressure, while the composition of the fluid remains unchanged.

The longitudinal and cavernous sinuses of the dura mater are thrombosed much less frequently than the sigmoid or transverse sinuses because the former two sinuses are usually affected by extension of pathology from the sigmoid and transverse sinuses. Moreover, thrombosis of cavernous and longitudinal sinuses can be complications of sinusites and furuncles of the face or nose.

The maxillary sinus and the cells of the ethmoid labyrinth are the most important sources of infection.

Thrombosis of the cavernous sinus is characterized by pronounced local symptoms which develop due to difficult venous outflow. The affection is characterized by swelling of the eyelids and the adjacent tissues, dilatation of superficial veins and hyperaemia of the orbital veins, cyanosis of the orbit, and exophthalmos. These symptoms are supplemented by papilloedema, oedema and thrombosis of the retinal veins. Focal symptoms are also characteristic. Since the first branch of the trigeminal nerve and the oculomotor nerves (3rd, 4th and 6th pairs) pass along the sinus wall, the patient suffers from neurological pain in the region of innervation of the first branch of the 5th pair (orbital and infraorbital neuralgia), analgesia of this region, including corneal anaesthesia, and decreased or lost corneal reflex. Affection of the oculomotor nerves causes internal and external ophthalmoplegia with paralysis of the eyeball of various type and gravity. Unilateral thrombosis of the cavernous sinus can extend to the other side. Thrombosis of the cavernous sinus often concurs with meningitis.

Treatment is surgical. Like in other intracranial otogenic complications, the operation should be performed immediately after establishing the diagnosis of chronic or acute inflammation in the ear, and in the presence of the symptoms of sinus thrombosis and sepsis. In very rare cases when the symptoms of sepsis persist after operation, the internal jugular vein should be ligated or the transverse sinus opened. Antibiotics should be administered in maximum permissible doses, obligatory in combination with sulpha drugs, nystatin, vitamins, haemodez, glucose, analgesics, etc. Blood cultures should be incubated repeatedly.

SURDOLOGY AND HEARING AIDS

Surdology is the branch of audiology dealing with prevention and treatment of pathological conditions that can cause, or have already caused persistent amblyacousia (blunted hearing). By amblyacousia is now understood the condition under which perception of normal speech is significantly hindered. Deafness is the condition in which man is unable to perceive loud speech in the close vicinity of his ear.

These two conditions should be differentiated from surdomutism (deaf-mutism) which can be congenital (due to underdevelop-

ment of the auditory apparatus) or acquired in early childhood after infectious or acute inflammatory diseases. A deaf-mute child can neither hear speech, nor speak normally himself.

The most common causes of impaired hearing are (1) diseases of the central nervous system; (2) acute infectious diseases; (3) local suppurative processes and catarrhal otitis media, independent or concurrent with rhinitis, dystrophic processes in the nasal mucosa, adenoids, and other pathological conditions in the upper airways; (4) dystrophic changes in the internal ear. This group includes progressive central (nervous) deafness, otosclerosis, and Ménière's disease, which are substantially different pathologies; (5) mechanical trauma (industrial, sporting, etc.), barotrauma, acoustic, vibrational, chemotoxic, radiation, medicamentous, birth, infectious, or psychic trauma.

Patients with partial or complete hearing loss later develop speech disturbances. Their speech becomes monotonous, inarticulate and arrhythmic because of the inability to control their voice. If a child develops deafness (especially in infancy, when he cannot speak at all or only begins talking) he will grow mute. Training at special schools helps such patients to learn lip-reading and speaking.

Diagnosis of diseases that can impair hearing or cause deafness has been described in appropriate chapters. Topical diagnosis helps determine the function of the auditory apparatus. The main task of topical diagnostics is to differentiate between perceptive and conductive deafness.

Prevention of hearing disorders is the main objective of surdology. It implies not only prevention of acute inflammatory diseases of the nose, paranasal sinuses, middle ear, children's infections, but also a detailed study of occupational and living conditions of the population. Regular out-patient examination of children and adolescents with deranged hearing is especially important in this respect.

All available medicines and physiotherapeutic means should be used to treat patients with hearing disorders. Hearing aids should be given special attention and must be prescribed to deaf patients who cannot be cured by conservative or surgical methods. Hearing aids are most effective in patients with conductive deafness and less effective in patients with perceptive deafness. This is explained by a small difference between the sound and pain perception thresholds. Amplification of sound is limited by the tolerability of the patient, i.e. the threshold beyond which a further amplification of sound causes pain. Hearing aids are indicated for (1) hear-

ing loss that cannot be treated by the existing methods and (2) decreased perception of speech frequencies by more than 40 dB, but not more than 80 dB (speech perception at a distance less than 1 metre).

Using hearing aids does not cure the pathology in the middle ear, but only improves hearing and helps the patient to control his speech. Using hearing aids by children improves their speech and psychic health.

The efficiency of the apparatus should be checked not later than two weeks after its installation. During this period the patient becomes adapted to the unusualy loud sounds. In cases with a unilateral hearing disorder (if it can be treated) using any hearing aids is not obligatory.

If a patient is unable to use hearing aids, he should be taught to understand speech by lip-reading.

Review Questions

1. Pressure applied to the tragus of an adult or child causes pain. A symptom of what pathology is this pain?
2. How can an earwax plug and foreign bodies be removed from the external ear?
3. Name the signs of acute mastoiditis in a child.
4. A haematoma of the pinna develops after an injury to the external ear. How should it be treated?

Problem

A patient attends a doctor for impaired hearing caused by penetration of water in the ear. There were no complaints of earache in the past history. Establish the diagnosis.

TUMOURS

TUMOURS OF THE RESPIRATORY TRACT

Tumours of the upper airways (of the nose, the paranasal sinuses, the pharynx and the larynx) and also of the ear are comparatively common: they make about 4-5 per cent of all human tumours. Benign and malignant tumours of the upper airways are usually located in the larynx; next in incidence come tumours of the nose and the paranasal sinuses and then follow tumours of the pharynx; tumours of the ear are comparatively rare. Malignant tumours, especially of the larynx, occur mostly in males aged from 40 to 70. But they also occur in women and children.

According to the international classification, tumours are classified as benign and malignant by their histological structure and clinical course. They can originate from epithelial, connective, muscular, nervous and pigment tissue.

The histological structure of a tumour characterizes the degree and special character of degeneration of tissue cells, and their proliferation into the surrounding tissues. The clinical course of a tumour characterizes its specific growth, the ability to metastasize and recur after treatment, etc. The histological picture usually agrees with the clinical picture, but sometimes a histologically benign tumour grows like a malignant one, and vice versa, a histologically malignant newgrowth has the clinical signs of a benign tumour.

BENIGN TUMOURS

Tumours of the nose. Benign tumours of the nose are papillomas, fibromas, angiomas, angiofibromas, chondromas, osteomas, neuromas, naevi (pigmented tumours), warts, and bleeding polyps. Mucous polyps are also classified as benign tumours but these formations have no tumour structure and are actually inflammatory and allergic hyperplasia of the mucous membrane.

Typical symptoms of benign tumours of the nose are persistently difficult respiration through the affected side of the nose, hypo-osmia or anosmia, and possibly small bleeding. The face bones are often disfigured at later stages of the disease; this period is also characterized by headache, displacement of the eyeballs, and deranged vision.

Diagnosis is established by endoscopic examination of the nose, probing the tumour, its palpation and X-ray examination. The final diagnosis is established histologically.

Treatment is surgical. Since benign tumour can recur, and tumours like papilloma can convert into cancer, the operation should be radical. It is necessary to foresee a possible profuse bleeding in cases of vascular tumour. The external carotid arteries should be ligated on both sides before removing vascular tumours. Small angiomas should be removed together with the underlying tissue or they can be destroyed by galvanocautery. Cryosurgery is sometimes used. If operation is not radical, the tumour can grow anew.

Tumours of the pharynx. Benign tumours of the pharynx are fibroma, papilloma, haired polyp, angioma, neurinoma, neurofibroma, mixed tumours, lipoma, cysts, and retropharyngeal goitre.

Papillomas and fibromas on a pedicle occur more frequently. Papillomas are usually soft; they grow on the soft palate and the palatine arches; they are small and usually do not disturb the patient. Sometimes papillomas grow from the nasopharynx, the lateral walls of the pharynx, the glossal surface of the epiglottis and its margin. Children (rarely) develop papillomatosis of the soft palate, uvula, palatine arches or lateral walls of the pharynx. Females ageing from 20 to 40 prevail among adult patients.

Diagnosis is established by inspection and histological examination and presents no difficulties.

Treatment includes removal of single papillomas with subsequent galvanocautery; sites of papillomatous degeneration of the mucosa can be treated by extreme cold (cryosurgery). Single papillomas recur rarely after their removal. If vast areas are affected with papillomas, relapses are frequent. Since these tumours can degenerate into cancer, treatment should be timely and radical.

Fibroma is a common nasopharyngeal benign tumour. It usually occurs in persons ageing from 10 to 20. It is therefore called juvenile fibroma. At the age over 25, juvenile fibroma undergoes involution. Depending on the direction of growth, fibromas cause asymmetry of the face, compression and deformation of the surrounding bony and soft tissues. The eyeball can be displaced, the

blood supply to various parts of the brain can be disordered, and nervous formations compressed. Thus a histologically benign tumour can be malignant with respect to its clinical course although it is not characterized by invasive growth and metastasis. Such tumours should be regarded as conventionally benign.

Treatment is only surgical and as radical as possible, since relapses are possible. Removal of these tumours should be performed with intubation anaesthesia. The approaches are endonasal or transmaxillary. Massive blood transfusion is necessary during operation.

Angioma is a relatively common benign newgrowth of the pharynx and can grow from its various regions. As a rule, angioma is small and sometimes has the shape of a polyp.

Treatment is surgical. Electrocoagulation is also used. Sclerotherapy should be applied with great care.

Haired polyp is a congenital tumour occurring usually at the age under 1 year; it usually grows from the posterior surface of the soft palate or the lateral wall of the pharynx. It has a long pedicle and is covered with skin and fleecy hairs. The polyp interferes with respiration and suction because its long pedicle makes it easily movable inside the pharynx and even mouth to impose greater difficulties to respiration.

Treatment is surgical. The polyp's pedicle is ligated at its base and the polyp is cut off. Bleeding is absent; relapses are absent too.

Cysts of the pharynx can have different location but usually occur on the tonsils (follicular or retention). They are filled with turbid or pus-like matter. Intramural cysts can occur in the soft palate or the pharyngeal mucosa. They differ from retention cysts by their internal epithelial lining (true cysts). Cysts are formed due to occlusion of the efferent ducts of the *mucous glands* of the pharyngeal mucosa.

Treatment is surgical. A true cyst should be removed by enucleation because even a minute remnant of the cyst wall will cause a relapse of the disease.

Laryngeal tumours. Common benign tumours of the larynx are fibromas, papillomas, angiomas, and cysts.

Fibroma (fibrous polyp) usually grows from the free edge of the vocal fold at the border between the anterior and middle third. It grows very slowly and usually does not grow large. It is a round formation with a broad or pedunculated base. Histologically fibroma has a fibrous connective-tissue structure. Soft and firm fibromas are distinguished depending on the density of the fibres. The

newgrowth is rich in blood vessels and can therefore be red; such a tumour is called angiofibroma. Fibroma is covered with squamous epithelium.

The main *symptom* of the disease is hoarseness and possibly cough. The voice can change if a fibroma grows on a long pedicle and is thus easily movable.

Treatment is surgical. The fibroma is removed by laryngeal forceps. The operation is bloodless. Relapses are possible if a piece of the tumour is left. The removed fibroma must be examined histologically because in rare cases a cancer tumour can have the appearance of a fibroma.

Papillomas are single or multiple papillary growths which resemble cauliflower. They usually grow on the vocal folds or on the laryngeal mucosa; they can also extend to the mucosa of the trachea. If papillomas grow to a great size they can cause asphyxia. Papillomas are whitish or, less frequently, dark-red, depending on the degree of vascularization.

Papillomas usually occur in children from 18 months to 5 years of age; they often resolve spontaneously by the onset of sexual maturity. Their aetiology is therefore believed to be dependent on the endocrine system.

Biopsy is performed using laryngeal forceps during indirect laryngoscopy in adults; direct laryngoscopy is often necessary for children. Specimens should be taken at the border between the papilloma and healthy tissue.

Treatment is surgical. Papillomas should be removed endolaryngeally, and if the newgrowth is large, laryngofissure is necessary. The entire tumour is excised, the wound is covered with epidermis.

It is recommended to apply extreme cold to the underlying tissue after thorough surgical removal of the papilloma. Cryosurgery destroys possible remnants of the papilloma base and leaves no scars.

Relapses are frequent but the tendency to develop them depends on the individual properties of patients: in some patients papillomas have to be removed several times within the course of the year while in others the operation is necessary only once in several years. Single papillomas usually give no relapses after their surgical removal.

Cysts occur in the larynx in rare cases; they are usually localized on the laryngeal surface of the epiglottis, along its margin, and in the laryngeal ventricle. As a rule, cysts develop due to blockage of the ducts of mucous glands. They grow slowly and are seldom

large. Small cysts produce no symptoms, nor do they require special treatment.

Treatment is surgical if the cyst interferes with the normal function of the larynx. A part of the external cyst is removed, after which no relapses usually occur. Large cysts of the larynx are removed with a laryngofissural approach. A lateral or transverse pharyngotomy is sometimes required.

Angiomas of the larynx originate from dilated blood vessels (haemangiomas) or lymphatic vessels (lymphangiomas). They can develop on the vocal, ventricular, or aryepiglottic folds. They grow slowly and are usually small. In rare cases angiomas are multiple. Sometimes the tumour can grow large to sag into the laryngeal lumen and interfere with respiration. Haemangiomas are cyanotic or red; lymphangiomas are pale-yellow. Small angiomas are annoying only when located on the vocal folds (hoarseness). Medium size and large angiomas interfere with the normal function of the larynx and should therefore be surgically removed. The approach is usually endolaryngeal.

MALIGNANT TUMOURS

Various forms of cancer occur in the airways; sarcoma is rare.

Cancer of the larynx. Cancer of the larynx is a common malignant tumour of the upper airways. It makes more than 4 per cent of other malignancies. In males laryngeal cancer occurs more often than in females (12.5:1). The tumour develops at the age of 50-60, but it can also occur in children and in senile persons.

Many substances, e.g. air pollutants, various industrial dusts (aniline dyes, chromium compounds, radioactive substances), smoke, and carbon black can act as aetiological factors predisposing to cancer. The cancerogenic properties of resins and carbon monoxide, which are contained in tobacco smoke, are well known. The predisposing factors are also excessive irritation with chemicals, prolonged occupational vocal strain, abuse of alcohol, etc.

As a rule, laryngeal cancer is a primary affection, and only in rare cases it is secondary to malignant newgrowths of the mouth or the thyroid gland.

According to location laryngeal cancer is differentiated into cancer of the vestibule of the larynx, cancer of the middle portion of the larynx (affection of the vocal folds), and subglottic cancer. Cancer of the vestibule of the larynx has the earliest and most extensive metastases. Metastasizing is less intense in cancer of the inferior portion of the larynx. Cancer of the vocal folds metasta-

sizes only at late terms of the disease and if large areas are involved.

Unlike cancer of other localization, laryngeal cancer metastasizes into remote organs and tissues only in rare cases and at the late stage of the disease (e.g. into the tracheal lymph nodes and the lung root; very rarely into the liver, vertebral column, kidneys or the stomach).

Classification. In addition to characteristics of cancer of the larynx according to its location (with respect to the level, endo- or exophytic proliferation) and the histological structure, there exists the international TNM staging according to the three main components, viz., primary tumour extension (T), regional lymph nodes metastasis (N), and the extent of metastasis spread (M).

Symptoms. In the overwhelming majority of cases, the early sign of laryngeal cancer is hoarseness due to involvement of the vocal cords. A minutest tumour at the edge of the vocal fold causes incurable hoarseness, for which the patient attends the doctor. But if a tumour is located outside the vocal folds, hoarseness can be absent for a long time (up to the second stage of the disease) and can develop due to the attending inflammation of the surrounding tissues, the vocal folds included. Moreover, the third stage of cancer, whatever its location may be, is usually associated with upset vocal function (Plate XII).

The early symptoms are coughing, tickling and discomfort in the throat during swallowing. At later terms, if the tumour is located in the region of the upper laryngeal ring, swallowing gradually becomes disturbed. The patient feels a "lump in the throat"; he complains of hypersalivation and difficult swallowing. If inflammation joins in, pain may develop (or intensify). The patient sometimes complains of shooting pain in the ears. A tumour can ulcerate, which is manifested by the appearance of blood in the saliva and putrid breath.

Difficult breathing is associated with the growth of cancer in the region of the vocal folds, but large tumours of the vestibule of the larynx (in the region of the vestibular folds, the arytenoid cartilages, and the epiglottis) can also cause stenosis of the larynx. The tumour often upsets the motor innervation thus causing paralysis of the corresponding side of the larynx. If the tumour is located in the laryngeal lumen, paralysis causes stenosis of the larynx. During the third or fourth stage of the disease, many patients develop apathy, their appetite is poor, and they lose weight.

The main laryngoscopic sign of cancer is the presence of tumour on the laryngeal walls. Tumours differ in size and location. Tuberosity of the surface is characteristic, but if the growth is endophytic, the mucous membrane can be smooth and unchanged; vascular injection can sometimes be the only sign of malignancy. At later period, saucer-like depressions can be seen; they can be covered with a whitish coat which is the sign of tumour destruction by ulceration. During phonation, mobility on the involved side of the larynx can be limited or absent altogether (third or fourth stage); the mobility of the vocal fold can also be restricted.

If a tumour or an area suspected for cancer is revealed, biopsy should be performed under local anaesthesia. As large a specimen as possible should be taken at the border of the tumour and healthy tissue. If the clinical picture does not agree with the histological findings, biopsy should be repeated. If repeated biopsy (not more than three) does not resolve the divergence in clinical and histological findings, a laryngofissure should be performed with excision of the entire tumour, and its material must be examined cytologically. Further tactics depends on the results of the histological examination.

Treatment includes surgery, radiotherapy and chemotherapy. The former two methods can be used independently, while chemotherapy is only auxiliary. Selection of the method depends mainly on the stage of the disease, the histological structure of the tumour and its location.

Radiotherapy should be preferred during the first stage; surgery or radiotherapy can be used to treat the patients with the second stage of the disease, while combination of these two methods seems to be more rational in such cases: the tumour is removed surgically (together with a portion of healthy tissue) and radiotherapy is then applied by the course of the lymph flow. A combined method is recommended to treat the third stage: surgical removal of the tumour should be followed by radiotherapy.

If the lymph nodes are enlarged, the larynx should be resected together with connective tissue of deep jugular nodes of the corresponding side of the neck, or the jugular vein must be removed together with the nodes and the connective tissue. After wound healing, radiotherapy is conducted.

Surgeon's tactics changes if ablastic partial resection is impossible. Total extirpation of the larynx with the hyoid bone is indicated for such cases. The present authors have developed a method according to which a permanent tracheostoma (complete open-

ing of the trachea at the level of the 1st and 2nd rings) with suturing it to the skin should be performed; the second stage of the operation is isolation of the larynx and its removal with the hyoid bone.

Plastic operations with reconstruction of natural respiration through the upper airways are sometimes performed during partial resection and sometimes during complete extirpation of the larynx. Suggested by the authors method of reconstruction of the lateral wall of the larynx using a musculocutaneous graft ensures reliable reconstruction of the wall with preservation of an adequate lumen in the larynx.

There exists a method of pre-operational radiotherapy which somewhat diminishes the tumour. It should however be remembered that the reaction of X-rayed tissues can complicate the post-operative period considerably, especially after partial removal of the organ. Moreover, cancer cells can be disseminated during subsequent operation.

Sarcoma of the larynx is a rare disease, occurring mostly in males (of middle age) but it can affect children as well. The tumour usually originates from the submucous layer or from the perichondrium. The following histological variants of sarcoma are distinguished: spindle-cell, polymorphous cell, round-cell, alveolar, lymphosarcoma, fibrosarcoma, and myosarcoma. Lymphosarcoma and alveolar sarcoma are most malignant. Sarcoma is usually located on the vocal folds; its size varies. The surface of the tumour is relatively smooth; the colour depends on vascularization. Metastasizing into the regional lymph nodes occurs during later periods of the disease; remote metastases occur in rare cases.

Symptoms and *diagnosis* are the same as in cancer of the larynx.

Treatment is surgical or by radiotherapy. These methods can be supplemented by chemotherapy. Relapses at late terms are frequent.

Tumours of the pharynx. The incidence of malignant tumours of the pharynx is comparatively high. Cancer, Schmincke tumour (lymphoepithelioma), blastocytoma, sarcoma and mixed tumours are among them. The diseases affect mostly males of middle age.

Early *symptoms* are few and not specific. Discomfort and the sense of a foreign body in the throat, tickling and other sensations of uneasiness can be felt by the patient. At later stages the patient complains of difficult nasal breathing and a feeling of stuffed ears (if the tumour is located in the nasopharynx); a feeling of a foreign body in the throat that interferes with swallowing food and later saliva (if the tumour is present in the oropharynx); difficult pas-

sage of solid and then liquid food and impeded breathing (if the tumour is found in the laryngopharynx). These symptoms are first considered by the patients as unimportant and the physician often attributes them to chronic pharyngitis or neurosis.

The early symptom of a nasopharyngeal tumour is hypersecretion of mucus which can contain sanious admixtures and can be discharged through the nasopharynx and the nose. The tumour rapidly metastasizes into the regional lymph nodes, invades the cavity of the cranium through the lacerated foramen, and is attended by pain in the jaw, teeth, and the ear on the involved side; double vision and strobismus develop. Profuse nasal bleeding occurs on tumour disintegration.

The nasopharyngeal tumour is *diagnosed* by the mentioned symptoms and the findings of endoscopy, palpation, and X-ray examination. Surgical treatment of malignant tumours of the nasopharynx is difficult; efficacy of radio- and chemotherapy depends on tumour sensitivity to these measures.

In the middle portion of the pharynx cancer and sarcoma mostly occur. The severity of symptoms depends on the size of the tumour, its location and the rate of disintegration. Dysphagia, choking, pain, hoarseness and fetid breath indicate the late period of newgrowth in the pharynx.

Treatment is combined for the early period: surgical (diathermocoagulation) and radiotherapy; radio- and chemotherapy are only used for the late stages of the disease.

Compared with the upper parts of the pharynx, the laryngopharynx is more frequently affected with malignant tumours. As a rule, these are epithelial newgrowths. The initial stage of the tumour growth is usually overlooked. Despite some minor complaints (discomfort in the throat), the diagnosis is often difficult at this stage because of inaccessibility of the lower portions of the pharynx to direct laryngoscopy. Slight congestion of the saliva can only be observed in the hypopharynx. Marked signs of dysphagia develop relatively soon, which is an indication for contrast X-ray examination and direct hypopharyngoscopy. Sometimes the tumour compresses the arytenoid cartilage and can partly close the inlet of the larynx; this is manifested by marked symptoms of dysphagia, hoarseness and sometimes disturbed respiration.

Treatment is mainly conservative; surgical treatment is rare. Therapy of laryngopharyngeal tumours should be combined: surgical removal of the tumour and the regional lymph nodes should

be followed by diathermocoagulation and radiotherapy of efferent lymphatic ducts.

Tumours of the nose and the paranasal sinuses are cancer and sarcoma. These tumours are usually primary. They occur comparatively seldom, mostly in middle-aged and elderly males. Primary malignant tumours usually affect the maxillary sinuses; next in the list of incidence come tumours of the ethmoidal, frontal and sphenoidal sinuses. The nasal septum is the source of malignancy in rare cases.

Malignancy of the tumours of the paranasal sinuses is determined by a relatively rapid growth into the neighbouring organs and tissues: into the base of the cranium, the pterygopalatine fossa, the orbit, and the oral cavity. Metastasizing begins at late terms, first into the retropharyngeal lymph nodes, which are hardly accessible to clinical examination, and then into the cervical lymph nodes which can be easily palpated.

Symptoms become apparent at early terms but they are first not severe. The patient complains of progressively increasing difficulty in breathing through one side of the nose. The nasal secretions are mucous and later with traces of blood. If a tumour is suspected, it is not difficult to diagnose it using modern diagnostic means.

In addition to the endoscopic methods of diagnosis, probing of the paranasal sinuses and their puncture with aspiration of the pathological contents and subsequent administration of radiopaque substances, and roentgenography in various projections are also used. If a tumour, or a tissue suspected for tumour, are thus revealed, biopsy should be performed for histological examinations. Operational biopsy is sometimes required.

Treatment at the early stage of the disease is combined: removal of the tumour with diathermocoagulation, followed by radiotherapy along the course of efferent lymphatics. Some surgeons think it expedient to carry out pre-operative radiotherapy to inhibit the active growth of the tumour. Radium preparations should be implanted into the postoperative wound. In the presence of metastases in the regional lymphatics (or if they are suspected) the lymphatics should be excised together with the connective tissue. Growth of the tumour into the base of the cranium, and deep into the pterygopalatine fossa excludes radical excision of the tumour. Radiotherapy and general and regional chemotherapy should be given to such patients.

Neurinoma of the 8th pair of the cranial nerves occurs in 11-13 per cent of all cases with brain tumours; patients at the age from 30 to 40 are commonly affected. This kind of tumour does not occur in children.

The histological structure of the tumour is benign. After timely removal of the tumour the patient is fully capable of working, but in the advanced stage the disease takes a malignant clinical course because the tumour compresses the surrounding parts of the brain thus causing severe cerebral complications.

The disease is characterized by slow and gradual impairment of hearing (to unilateral deafness). The patient often does not notice unilateral amblyacousia for a long time. Patients with unilateral cochlear neuritis remain capable of working for 5-6 years from the onset of the disease. They consult their doctor when the disease is neglected and the tumour compresses the liquor ducts and the patient experiences severe headache and balance disturbances. Unfortunately, years sometimes pass before the diagnosis is established.

Treatment of timely diagnosed cases is surgical. The patient recovers as a rule, or his condition is improved significantly and working capacity regained.

TUMOURS OF THE EAR

Tumours of the ear are quite rare. Benign and malignant newgrowths are distinguished.

Benign tumours of the ear are papillomas, fibromas, angiomas, chondromas, osteomas, etc. Various cysts of the ear (ateromas, dermoids) are tumour-like formations. Benign tumours develop mainly on the external ear (external acoustic meatus, posterior surface of the pinna). Some tumours, however, grow in the middle and internal ears. For example, osteoma can develop in the antrum and other cells of the mastoid process. Fibromas and angiomas are usually diagnosed in the tympanic cavity.

Neurinoma of the 8th pair of the cranial nerves stands first in the list of incidence of benign tumours of the internal ear.

Diagnosis of benign tumours of the external ear is simple. Both visual and histological examinations are important. Benign newgrowths in the external acoustic meatus, such as osteomas (exostoses), papillomas, angiomas, always impair the conductive function of the auditory apparatus as their size increases significantly.

X-ray pictures of the temporal bones of patients with exostosis or osteoma in the bony part of the external acoustic meatus reveal shadows which do not extend to the middle ear.

Diagnosis of benign newgrowths of the middle ear is based mainly on the long course of their development, on the results of the functional tests and X-ray examinations. But the histological studies are decisive in the differential diagnosis and treatment of newgrowths.

Treatment of benign tumours of the external ear is mainly surgical. In the presence of vascular newgrowth, it is recommended first to carry out a course of sclerotherapy (administration of alcohol and formaldehyde into the tumour). Surgical operation is then indicated.

Fibroma or osteoma of the middle ear should be treated only surgically.

Glomous tumours should be specially mentioned. They arise from gloma, small nerve formations in the mucosa of the middle ear cavities or adventitia of the jugular vein bulb.

Glomous tumour grows very slowly, but it involves the adjacent nerves, compresses and destroys the structures of the middle ear, thus causing severe complications in some cases. Radiotherapy with subsequent surgery should be considered as the most rational treatment. Cryosurgery often gives good effect.

Among **malignant newgrowths** of the external ear, cancer is diagnosed mostly in adults, while sarcoma occurs mostly in children. Melanoma also occurs. Tumours of the external ear grow slowly and resemble a granulating bleeding ulcer. The main diagnostic method is histological examination.

Cancer of the middle ear is more common for adults and sarcoma for children. Depending on location and spread, cancer can be primary (primary cancer of the auditory tube) and secondary (tumour spreading from the adjoining areas such as the pharynx, cranium, etc.).

It should be noted that growth of tumour in the temporal bone rapidly causes its sequestration, and if secondary infection joins in, malignant pus is discharged, and pain in the ear and headache develop simultaneously.

During the early stage, when the tumour hasn't grown outside the tympanic cavity, prognosis is relatively favourable. Later, when the neighbouring organs become involved, the prognosis is bad.

Treatment of cancer of the external ear can be both surgical

and by radiotherapy. The choice depends on the morphological structure of the tumour and on its spread.

Melanoma and sarcoma can be treated only by radiotherapy. Small melanomas are now successfully removed by cryosurgery.

Treatment of cancer of the middle ear at its early stage should be combined (surgery and radiotherapy); at later stages radiotherapy and chemotherapy are used. Radiation therapy alone is used to treat sarcoma.

SPECIFIC DISEASES

TUBERCULOSIS

Tuberculous otitis arises when infection is spread by the bloodstream from any distant primary focus, usually from the lung. This is confirmed by frequent affection of the mastoid process (mostly in infants) without antecedent inflammation of the middle ear (Plate XIII).

The morphological changes are characterized by formation of specific tubercles which later undergo caseous degeneration. Soft tissues undergo purulent disintegration and the tuberculous granulations rapidly proliferate.

If the tympanic membrane is affected, isolated tubercular foci develop in it which decompose and cause multiple perforations. Extension of the process to the bone dissolves the osseous tissue under the action of invading granulations. Tuberculous otitis usually runs a chronic course.

Treatment should begin with active general anti-tuberculosis therapy which includes streptomycin, para-aminosalicylic acid (PASA), phthivazid and other preparations; sparing conditions should be provided for the patient along with adequate nutrition, etc. Radical operation on the ear is indicated for carious-granulation process in the middle ear together with the general anti-tuberculosis therapy.

Tuberculosis of the nose. Mycobacteria enter the nose from the tuberculosis focus in the lung, the joints, or the larynx. The pathomorphological substrate is the infiltration which is accumulation of tubercles in the submucous layer. Destruction or curd-like degeneration of these tubercles causes ulcers. Crusts are formed in the involved side of the nose. When the crusts are removed, accumulations of translucent tubercles can be seen in the mucous membrane.

Treatment is general and local. PASA, phthivazid, streptomycin and other preparations are used. The local treatment includes cautery of the infiltrations and ulcers with various acids (trichloroacetic

acid or 80 per cent lactic acid, etc.). A 10-20 per cent ointment of pyrogallic acid is applied externally; 2-3 g/day of potassium iodide are taken per os for 4-8 weeks. The affected part of the nasal septum or of the choanae are sometimes excised with subsequent galvanocautery of the defect margins. A positive effect is attained with irradiation of the nasal mucosa with the light of a quartz lamp (through a cone), and also with radiation therapy.

Tuberculosis of the pharynx occurs comparatively rarely. It is usually associated with decreased general and local resistance of the body and is only secondary to pulmonary tuberculosis or tuberculosis of the larynx.

The clinical *symptoms* are characterized mainly by severe pain during swallowing of both solid food and liquids. As a rule, joining secondary infection accounts for the fetid breath. These symptoms are associated with formation of ulcers mainly on the palatine arches and the mucous membrane of the posterior wall of the pharynx.

At later stages, the diagnosis is established by the clinical picture, Pirquet's test, microscopic study of granulation taken from the region of the ulcers, and by general examination.

Treatment. In addition to general therapy, patients should be treated by exposing ulcers to the light of a quartz lamp (through a cone). Frequent gargling of the oropharynx with a warm camomile tea, garden sage tea, or hydrogen peroxide solution is indicated. In order to relieve pain during swallowing, the ulcerated surfaces should be treated with anaesthesin ointment or powder. Food should be warm, liquid, and not irritating.

Tuberculosis of the larynx is the most frequently occurring tuberculous affection of the airways, but during past decades its incidence has become low. The larynx is infected with tuberculosis mycobacteria mainly by three routes. The most common of them is contact infection with sputum expectorated from the lungs of patients with pulmonary tuberculosis. The other route of ingress is with blood (haematogenic route). The third way of infection spreading is by lymphatics. Three stages are distinguished in the development of a tuberculous process in the larynx: the first stage is infiltration; the second is characterized by formation of ulcers; and the third stage is associated with affection of the cartilages and perichondrium.

The vocal function is upset only in cases when the vocal or vestibular folds and the interarytenoid notch are involved. Development of the pain syndrome is associated with infiltration in the

epiglottis, posterior surface of the arytenoid cartilages and the aryepiglottic folds.

The laryngoscopic picture corresponds to the stages of the pathological process. But the most common sites of infection residence should be remembered. These are the interarytenoid space, arytenoid cartilages and the adjacent parts of the vocal cords. Tuberculosis of the larynx progresses slowly and its development mainly depends on the progress of pathology in the lungs.

If the tuberculous process in the larynx is eliminated (usually at the infiltration stage), the vocal function is usually restored.

Treatment. This should first of all be aimed at elimination of the main disease (usually pulmonary tuberculosis). Measures to provide optimum living and working conditions for the patient should also be taken.

Streptomycin is the main medicinal preparation used in medicamentous treatment. Streptomycin should be administered intramuscularly, 2 times a day (in 0.25 g doses) or once a day (0.5 g dose) diluted in a 0.25 per cent novocain solution. Not less than 60-80 g of streptomycin should be given in one course. PASA, phthivazid and other antituberculous preparations are also used. The combined use of these preparations is believed to have the best effect. But mycobacteria can survive in the submucous layer of the larynx and they can be reactivated to cause a relapse of the disease under appropriate conditions. For this reason, courses of chemotherapy should be used repeatedly.

Ulcerated surfaces should be cauterized with trichloroacetic acid after preliminary anaesthesia of the larynx with a 5 per cent cocaine solution and a 0.5 per cent citral solution. Anaesthetics should be used to prevent or relieve pain during swallowing.

Rp.: Anaesthesini 0.3
D. t. d. N. 6
S. To suck 15 minutes before meals

Rp.: Spiritus vini rectificati
Acidi tannici, āā 10.0
Anaesthesini 3.0
Mentholi 0.1
M.D.S. To treat the pharyngeal surface for dysphagia (Zobin's mixture)

Alcoholization of the superior laryngeal nerve and intracutaneous novocain block of the anterior surface of the neck are indicated for severe cases.

Lupus of the airways is a variety of the tuberculous process with specific changes in the skin and the mucous membrane. Lupus erythematosus runs a slow painless course and usually leaves scars. The disease occurs mainly in children from 5 to 15 years of age. Lupus often concurs with other tuberculous affections. The patient is infected by microbial invasion through lesions on the skin of the vestibule of the nose, damaged skin of the face, by haematogenic and lymphogenic routes. Lupus is characterized by painless nodular eruptions on the skin of the nose, lips, nasal mucosa, mucosa of the pharynx and less frequently of the larynx. Lupus tubercles are red-brown; they fuse to form large grey-yellow or red granular infiltrates. The infiltrates ulcerate in rare cases. Cicatrization of ulcerative infiltrates causes defects in the apex of the nose, the ala of the nose, and the soft palate. Laryngeal infiltrates usually affect the epiglottis with destruction of its cartilaginous framework and formation of a cicatricial ridge.

Treatment is almost the same as for tuberculosis of the upper airways. Radiation therapy can be successfully used for local treatment.

SCLEROMA

Scleroma (rhinoscleroma) is an endemic disease occurring in the middle East, Eastern Europe and Central and South America. In the Soviet Union it occurs mainly in the Western regions of Ukraine and Belorussia. Scleroma is a chronic disease affecting the mucosa, mainly of the upper airways. The disease attacks the young. The causative agent is believed to be Friesch-Volkovich bacillus (*Klebsiella rhinoscleromatis*), but other causative factors are also possible. The pathomorphological substrate for this disease is infiltrate consisting of fibrous connective tissue rich in plasma cells and vessels, among which are specific for scleroma Mikulicz's cells, Friesch-Volkovich capsule cells included into the Mikulicz's cell vacuole. The infiltrate also contains hyaline globules (Russel's or fuchsine bodies).

Symptoms. Three stages are differentiated in the course of the disease: the first stage is nodular-infiltrative; the second stage is diffuse-infiltrative or specific; and the third stage is regression (scarring). The so-called atrophic form sometimes occurs which is characterized by atrophy of the mucosa. Among the main signs of scleroma infiltrates is the absence of ulceration. The incubation period of the disease is very long; the disease itself persists for decades (Fig. 70).

Figure 70
External nose of a rhinoscleroma patient

The onset of the disease is characterized by atrophy of the mucous membrane which is attended with formation of thick crusts of tenacious mucus. Separate infiltrates can be seen. Scleroma affects mostly the nasal mucosa and the patient complains of dryness in the nose in the early stage of the disease. Breathing through the nose becomes difficult with time, speech disorders ensue, swallowing becomes difficult, and the external nose becomes sometimes disfigured. Rhinoscopy reveals infiltrates in the form of flat or tubercular pale-pink patches; these are absolutely painless to palpation. The infiltrates narrow the lumen of the nasal cavity, the vestibule of the nose, choanae, the nasopharynx, and the larynx. In other words, scleroma infiltrates arise mainly in physiologically narrow areas. Firm scars are later formed at the site of infiltrates. The scars stretch the surrounding tissues and stenose various parts of the respiratory tract.

Treatment can be conservative and surgical. Conservative treatment includes intravenous administration of embichin with 20 ml of a 40 per cent glucose solution. Injections should be done every other day. The dose should be gradually increased from 1-2 mg to 4 mg. Streptomycin should also be injected intramuscularly, 250 000 U twice a day, and by instillation into the trachea once a day. Radiation therapy (a total dose of 3 000-4 000 R) is sometimes effective.

Surgical treatment includes excision of the infiltrates and scars, their elimination by electrocoagulation and cryosurgery (liquid nitrogen).

SYPHILIS

Syphilis of the nose occurs as a primary sclerosis of the secondary and tertiary stages of the disease. A hard ulcer (chancre) occurs rarely and can be located at the vestibule of the nose, on the ala and the skin of the nasal septum. Injured skin promotes infection. Development of the syphilitic process in the nose causes the reaction on the part of the occipital and submandibular lymph nodes. They swell but their palpation is painless.

Inspection reveals a smooth painless erosion in the vestibule of the nose. The erosion is red and is 0.2-0.3 cm in size. The margins of the erosion have a ridge-like thickening. An infiltrate, whose consistency resembles that of a cartilage, can be palpated under the erosion. Secondary syphilides appear as erythema and papules. Erythemas are always associated with swelling of the mucosa and secretion of the sanguineous-serous substance. Such discharge in neonates or nursing infants suggests examination of the baby for possible specific disease. The tertiary stage of syphilis occurs more frequently than the two former stages. This is characterized by diffuse infiltrates or decomposing gummas. A gumma can be located on the mucosa, the bone, periosteum and cartilage. Bony tissue undergoes necrosis and sequestration. Apart from the endoscopic picture, important diagnostic evidence is provided by the Wasserman reaction and histological study of a specimen of the affected tissue.

Treatment must be general. Nasal irrigations with a sodium hydrocarbonate solution is recommended as a local treatment. Deformities of the external nose can be corrected by plastic surgery.

Syphilis of the pharynx. All stages of syphilis can occur in the pharynx. Hard chancre develops as an erythematous, erosive, and ulcerous lesions. The process is usually unilateral; it can last several months. The disease is associated with unilateral regional lymphadenitis (submandibular, cervical and occipital).

Neonates can be infected during breast feeding or due to damage to the mucous membrane. A hard chancre can develop on the lip, buccal mucosa, tongue, soft palate, or a palatine tonsil. In the latter case it can be mistaken for tonsillitis or diphtheria.

Secondary changes in the pharynx occur 6-8 weeks following the

appearance of a hard chancre. Simultaneously similar lesions on the skin develop (roseolas and papules). Roseolas appear on the palatine arches and the tonsils. The specific process in the palatine tonsils differs from acute tonsillitis by normal body temperature and painless swallowing. Pharyngoscopy during the secondary stage is characterized by a copper-hued diffused hyperaemia which extends to the palatine arches, the mucosa of the soft and hard palate.

The secondary-stage papules are greyish-white circular eruptions elevated over the surrounding tissue and circumscribed by a red margin. These lesions (plaques) often ulcerate, and can be seen on the tip and sides of the tongue, on the mucosa of the cheek and the hard palate. *Treponema pallidum* can be found in great quantity in the discharge from the ulcers. The oozing plaques become enlarged and form a large condyloma sometimes crowned with papillar formations. This stage of the disease is characterized by polyadenitis affecting the cervical, occipital, supratrochlear and other lymph nodes.

Diagnosis of the secondary syphilis is established by the positive Wasserman reaction, by discovering *Treponema pallidum* in the papular contents, and by inspection of the pharynx.

Treatment is general and specific. Local treatment includes gargling with weak disinfectant solutions (hydrogen peroxide, camomile tea, and the like).

Syphilis of the larynx manifests itself as a systemic disease. Hard chancre in the larynx occurs in extremely rare cases. The larynx is infected due to injury inflicted by food or a hard object. The secondary stage is manifested by erythema simulating catarrhal laryngitis with involvement of the mucous membrane of the vocal folds, arytenoid cartilages and epiglottis, and also by papules and large condylomas. The papules are located on the vocal, vestibular, aryepiglottic folds and on the epiglottis. Hoarseness is a subjective sign of secondary syphilis of the larynx.

Secondary syphilis of the larynx *is diagnosed* by laryngoscopic findings and by the presence of a similar process in the oropharynx and the other organs. Moreover diagnosis can be confirmed by ineffective specific treatment of laryngitis. The tertiary stage of syphilis of the larynx occurs mainly in males ageing from 30 to 50.

Gummas are located mainly in the epiglottis, and less frequently in the interarytenoid notch and on the vestibular folds. When located in the infraglottic space, a gumma appears in the form of a symmetric infiltrate.

Treatment is specific: novarsenol, osarsol, mercury and iodine

preparations, and antibiotics. The patient should be treated in hospital. Surgical intervention on the trachea or the larynx is indicated for stenosed larynx to improve breathing.

Syphilis of the ear. Secondary syphilis (roseola, papule) affects the skin of the external ear simultaneously with similar affections of the other parts of the skin. Affections of the internal ear are most important. Congenital and acquired forms are distinguished. In congenital form, the affections of the internal ear become evident at the age of 10-20. Hutchinson's triad is pathognomonic: Hutchinson's teeth, parenchymatous keratitis, and cochlear neuritis. Hearing disorder is the leading symptom; it is always bilateral.

Treatment is specifically antisyphilitic.

Mir Publishers of Moscow publishes Soviet scientific and technical literature in twenty-five languages comprising those most widely used. Titles include textbooks for higher technical and vocational schools, literature on the natural sciences and medicine, popular science and science fiction. The contributors to Mir Publishers are leading Soviet scientists and engineers from all fields of science and technology. Skilled staff provide a high standard of translation from the original Russian. Many of the titles already issued by Mir Publishers have been adopted as textbooks and manuals at educational establishments in India, France, Cuba, Syria, Brazil, and many other countries.

Books from Mir Publishers can be purchased or ordered through booksellers in your country dealing with V/O "Mezhdunarodnaya Kniga", the authorized exporter.

ISBN 5–03–000012–7